ISMR

2014 XI'AN CONFERENCE OF INTERNATIONAL SOCIETY FOR MAXILLOFACIAL REHABILITATION

Program Book

September 15-17 , 2014 Xi'an , China

Sponsors:

International Society for Maxillofacial Rehabilitation (ISMR)
Chinese Society of Oral Maxillofacial Rehabilitation (CSOMR)

Co-sponsors:

School of Stomatology, Fourth Military Medical University-China
The Weintraub Center For Reconstructive Biotechnology, UCLA-USA
The Foundation For Oral Facial Rehabilitation-USA
Tata Memorial Cancer Hospital-India
University Of Otago-New Zealand

TABLE OF CONTENTS

HISTORY OF THE ISMR

In the late 1980's John Beumer, Director of Maxillofacial Prosthetics UCLA, Los Angeles, California, Ian Zlotolow, Director of Dental Service, Department of Surgery, Memorial Sloan-Kettering Cancer Center, New York, New York and Sal Esposito, Director of Maxillofacial Prosthetics at the Cleveland Clinic, Cleveland, Ohio met and decided to conduct an international symposium devoted to the art and science of maxillofacial prosthetics. Seed money for this initial meeting was provided by their respective institutions and by the Borchard Foundation. More than 400 individuals from more than 30 countries attended this initial conference. The funds contributed by the Borchard Foundation were used to support the travel and lodging expenses of 30 professionals from underdeveloped countries.

The meeting was so successful and well attended that Beumer, Zlotolow and Esposito formed an international organization devoted to maxillofacial rehabilitation. They decided to conduct the meetings every two years and to rotate them between North America, Europe and Asia. The International Congress of Maxillofacial Prosthetics was then established and incorporated in October of 1996.

As the organization developed, it was understood that professional groups other than prosthodontists contributing to head and neck related care wished to participate in the organization. In recognizing this and the need to create an international organization that brought a diversity of professional groups together, the organization was renamed the International Society for Maxillofacial Rehabilitation (ISMR) on January 7th, 2002. In 2008 it was decided that the ISMR needed to be completely restructured to reflect and embrace the interdisciplinary nature of head and neck related care. The restructuring also needed to address development of a future-oriented organization that actively engaged involvement of the best young minds for the future. The decision was also made that, as a fundamental principle, these best young minds needed to be actively engaged in the operation of the ISMR.

The ISMR interest is in maxillofacial reconstruction and rehabilitation. This interest is not restrictive and relates, in broad fashion, to head and neck education, patient care, outreach and research. The ISMR membership is drawn from the international clinical and research community that has an interest in head and neck related care. The mission of the ISMR is to advance interdisciplinary maxillofacial rehabilitation throughout the world. The fundamental purpose of this mission is to improve reconstructive and rehabilitative maxillofacial care with the aim of improving quality of life of individuals needing care. The ISMR delivers this mission through bringing support to professionals involved in care, teaching and research. The ISMR is structured to be a fully interdisciplinary organization that recognizes the importance of diverse clinical and research disciplines embracing interdependency in their respective roles. The ISMR is an inclusive organization that places particular value on mutual respect of diverse disciplines in delivering excellence in education, patient care, outreach and research.

ISMR

WELCOME FROM PRESIDENTS

Dear colleagues:

On behalf of the International Society for Maxillofacial Rehabilitation (ISMR) and the Chinese Society of Oral Maxillofacial Rehabilitation (CSOMR), it gives me immense pleasure to welcome and thank you for joining the 2014 ISMR Xi'an Conference.

This meeting prepares a three-day program(September 15-17), that will provide all participants an opportunity to exchange knowledge, share ideas and discuss the latest research break through and advances in craniofacial reconstruction and maxillofacial rehabilitation. Our program has also assembled a renowned list of speakers that challenge us to confront the changing dynamics of our specialty.

We would like to take this opportunity to express sincere appreciation to all committee members, supporting organizations, contributors, session chairs, invited speakers, which made this meeting possible. Moreover, a large number of abstracts from all over the world were able to be received thanks to the wonderful support and efforts given by the international committee members.

Finally, we sincerely wish you a happy and pleasant stay in Xi'an attending the conference. Thank you.

Yimin Zhao, Ph.D, D.D.S, Professor
President of 2014 ISMR Xi'an Conference
President of Chinese Society of Oral Maxillofacial Rehabilitation (CSOMR)
Honorary President of International Society for Maxillofacial Rehabilitation (ISMR)
President of Fourth Military Medical University

Dear colleagues:

It is with great pleasure and honour to welcome all delegates to the 2014 Xi'an conference of the International Society for Maxillofacial Rehabilitation (ISMR).

The ISMR aims to be the preeminent interdisciplinary international organization in maxillofacial rehabilitation; 'advancing head and neck - maxillofacial rehabilitation together', through leadership, education, and outreach. One important goal set by the board was to reach out to locations throughout the world where traditionally the ISMR was not well-represented. Therefore, the ISMR is very pleased to be able to partner in the organization of the 2014 Xi'an conference of the ISMR in China.

Much gratitude is owed to the faculty of the School of Stomatology of the Fourth Military Medical School in Xi'an, especially to its President - Prof. Yimin Zhao, also President of the Chinese Society of Maxillofacial Rehabilitation (CSOMR), and Dr. Guofeng Wu who took the initiative and lead in the organization of this great international event in China, in cooperation with Prof. John Beumer III of the Foundation for Oral-facial Rehabilitation.

This resulted in a strong and exciting lecturing program, with renowned presenters from all over the world, representing many disciplines within maxillofacial rehabilitation in head and neck cancer, cleft patients care, and for other congenital conditions. Updates and advances in surgical reconstruction, in the use of digital technology, implant support for prostheses, functional aspects of rehabilitation, and many other topics including basic sciences will be addressed.

An overwhelming amount of over 180 poster presentations are enlisted in the program so far, showing the enormous interest for this great meeting and eagerness to share knowledge.

For sure, this conference will offer its participants a wealth of educational opportunities, but also a great opportunity to meet colleagues and start / maintain relationships. All of these are of great importance to enhance maxillofacial rehabilitation and our patient's care.

I wish you all a wonderful meeting in Xi'an and look forward meeting

you.



Harry Reintsema, Ph.D, D.D.S,
President of International Society for Maxillofacial Rehabilitation (ISMR)

AWARD COMMITTEE

Yongsheng Zhou, Beijing, CHINA

Yan Li, Guangzhou, CHINA

Weihong Ren, Beijing, CHINA

Karl Lyons, Otago, NEW ZEALAND

Doog-Hoo Han, Seoul, SOUTH KOREA

Balasubramanian Srinivasan, Pune, INDIA

Ben Wu, Los Angeles, USA

Kanchan Dholam, Mumbai, INDIA

CONFERENCE SHEDULE

14-Sept-2014		
8:00-21:00	**Registration**	
15:30-17:00	**Visiting School of Stomatology, Fourth Military Medical University (Free of charge)**	
19:00-21:00	**Cocktail Reception (Fee required)**	
15-Sept-2014		
8:30-9:00	Opening ceremony	
	Chair: Prof. Yongsheng Zhou & Prof. Robert Taft	
9:00-9:45	Digital time in the Maxillofacial Rehabilitation	Yimin Zhao, Fourth Military Medical University, School of Stomatology, China
9:45-10:15	Overdentures on primary mandibular implants in patients with oral cancer: a follow-up study over 14 years	Harry Reintsema, University Medical Centre Groningen, University of Groningen, The Netherlands
10:15-10:30	Coffee break	
	Poster Session (Award competition) and Exhibit Reception	
	Chair: Prof. Jianong Yang & Prof. Harry Reintsema	
10:30-11:00	Color stability of silicone maxillofacial elastomers: a summary of 15-year research experience	Sudarat Kiat-amnuay, University of Texas School of Dentistry at Houston, USA
11:00-11:30	Maxillofacial rehab in India: The 2006-2014 experience	Balasubramanian Srinivasan Enhance Head Neck Rehabilitation, India
11:30-12:00	The diagnosis and treatment of dysphagia	Ruiying Ding, Elmhurst College, USA
12:00-13:30	Lunch (Fee required)	
Session I – Advanced Digital Technologies and Maxillofacial Rehabilitation		

	Chair: Prof. Zhengjun Shang & Prof. Doog-hoo Han	
13:30-14:15	Digital technologies in maxillofacial rehab and reconstructive surgery	Robert Taft & Gerald T Grant, National Naval Medical Center, USA
14:15-14:25	Development and progress of craniomaxillofacial reconstruction	Zhigang Cai, Peking University School & Hospital of Stomatology, Beijing, China
14:25-14:35	Direct 3D printing of silicone	Swati Jindal, King's College London, UK
14:35-14:45	Rehabilitation of maxillectomy defects with CAD-RP obturator prostheses: A pilot study	Ting Jiao, 9th People's Hospital, Jiaotong University, Shanghai, China
14:45-14:55	Digital clinical solution of Presurgical Nasoalveolar Molding (PNAM) for infant clefts in FMMU	Guofeng Wu, Fourth Military Medical University, School of Stomatology, China
14:55-15:05	Combined prosthodontic and surgical management of patients with amelogenesis imperfecta: case series of two patients	Ben I Omondi, University of Nairobi, Kenya
15:05-15:15	Preoperative percutaneous nerve mapping of the mandibular marginal branch of the facial nerve	Bo Lin Peking University School of Stomatology, China
15:15-15:30	Coffee break	
	Chair: Prof. Ting Jiao & Prof. Balasubramanian Srinivasan	
15:30-15:40	Digital technology used in rehabilitation of maxillofacial defects	Xiaoyu Gu, 9th People's Hospital, Jiaotong University, Shanghai, China
15:40-15:50	Development of the combined finite-element and rigid-body analysis model for the maxillofacial prosthodontics	Ho Beom Kwon, Seoul National University, Republic of Korea
15:50-16:00	The evaluation of measurement accuracy of two different 3D face-scanner on healthy human faces	Hongqiang Ye, Peking University School of Stomatology, China
16:00-16:10	Application of computer aided technique in the rehabilitation of complicate oral-maxillofacial defect and deform	Shizhu Bai, Fourth Military Medical University, School of Stomatology, China
Session II – Implants and Maxillofacial Rehabilitation		

16:10-16:20	Implant system using precision surgical guide for maxillofacial prosthesis	Young-Bum Park, Yonsei University College of Dentistry, Republic of Korea
16:20-16:50	A Case of Fixed Prosthesis with Autologous Ilium Bone Free Graft Auxiliary GBR to Restore Severe Defects of Maxillary	Sefei Yang, Chinese PLA General Hospital, China
16:50-17:00	Immediate implant-retained prosthesis following radical maxillectomy	Guiqing Liao Guanghua School of Stomatology, Hospital of Stomatology, Sun Yat-Sen University, China
17:00-17:10	Effects of titanium-nanotubes surface modified by estrogen-loaded solid lipid nano-particles: an in vitro study	Yan Gao, Guangdong Provincial Stomatological Hospital, Southern Medical University, China
17:10-17:20	The use of zygomaticus implants in the compromised patient: review and patient report	Jay Jayanetti, Louisiana State University School of Dentistry, USA
17:20-17:30	Implant-supported intraoral prostheses retained by bar-clip attachment following distraction osteogenesis after block resection of mandible in a case of squamous cell carcinoma of the floor of the mouth	Chunbo Tang, Stomatological Hospital of Nanjing Medical University, China
17:30-17:40	Fabrication of Surgical Templates for Orbital Implant Placements and orbital rehabilitation	Songling Chen,, The first affiliated hospital of Sun Yat-sen University, Guangzhou, China
18:10-19:30	**Conference welcome and awards banquet (Fee required)**	
16-Sept-2014		
	Chair: Zhengxue Han & Vojkan Lazic	
8:30- 9:15	Microsurgical Free Flap Reconstructionsof Head and Neck Region: Shanghai Experience of 34 years	Chenping Zhang, The Ninth Affiliated Hospital, Shanghai Jiao Tong University, China
9:15- 9:45	Dental implant for oral tumor patients	Joji George Sekine, Shimane University Faculty of Medicine, Japan
9:45-10:15	Functional Reconstruction maxillary defects after ablative surgery	Jian Sun, The Ninth Affiliated Hospital, Shanghai Jiao Tong University, China

10:15-10:30	Coffee break	
	Chair: Yi Lu & Kanchan P. Dholam	
10:30-11:00	Implants for pediatric patients: growth and implant placement	Arun Sharma, University of California, San Francisco, USA
11:00-11:10	ALT flap in the reconstruction of defects in head and neck region	Jianhua Wei, Fourth Military Medical University, School of Stomatology, China
11:10-11:20	35 years with osseointegrated facial prostheses – history & developments	Kerstin Bergstrom, Sahlgrenska University Hospital, Sweden
11:20-11:30	Preliminary analysis on free flap re-exploration– Beijing's experience	Lei Zhang, Peking University School and Hospital of Stomatology, China
11:30-11:40	Facial prostheses retained on basally osseointegrated implants (BOI)	Vojkan Lazić, University of Belgrade, Serbian
11:40-11:50	Long-term result of reconstruction of mandible continuity with fibula free flap and implant borne dental rehabilitation	Wei Fang, Fourth Military Medical University, School of Stomatology, China
11:50-12:00	Sub-periosteal dissection with denture-guided secondary epithelialization: case series of a novel method for peri-implant tissue management in reconstructed mandibles	PC Jacob, Mazumdar Shaw Medical Center, Bangalore, India
12:00-13:30	Lunch (Fee required)	
Session III - Tissue Engineering and Maxillofacial Rehabilitation		
	Chair: Weihong Ren & Arun Sharma	
13:30-14:15	Recent Advances in Craniomaxillofacial Tissue Engineering	Ben Wu, University of California, Los Angeles, USA
14:15-14:25	Cell homing strategy for bone tissue engineering based on the cooperative actions of simvastatin and SDF-1α - a potential application in maxillofacial rehabilitation.	Yongsheng Zhou, Peking University School of Stomatology, China
14:25-14:35	Human freeze-dried dentin matrix as a biologically active scaffold for tooth tissue engineering	Fang Wang, Fourth Military Medical University, School of Stomatology, China

14:35-14:45	Comparison of tissue engineered bone substitutes for native bone augmentation -An in vivo study	Vijayalekshmi Manju, Amrita School of Dentistry, Amrita Institute of Medical Sciences, India
14:45-14:55	Mechanism of human oral facial fibro-osseous disease and in vivo mouse model development based on disease-specific iPSCs	Haiyan Qin Stomatological Hospital Affiliated Medical School, Nanjing University, China
14:55-15:05	The effect of a novel HDAC3-selective inhibitor on osteogenic induction of human adipose derived stem cells	Wei Lu, The 461 Hospital of PLA, Changchun, China
15:15-15:30	Coffee break	
	Chair: Zhigang Cai & Ho Beom Kwon	
15:30-15:40	Physicochemical properties and in vitro mineralization of porous polymethylmethacrylate cement loaded with calcium phosphate particles for bone reconstruction.	Yue Sa, Hospital of Stomatology, Wuhan University, China
15:40-15:50	Study on construction and biological effects of lipopolysaccharide-amine nano-polymersomes/ hyaluronic acid polyelectrolyte films on titanium surface	Teng Wei, Guanghua School of Stomatology, Hospital of Stomatology, Sun Yat-Sen University, China
Session IV – Miscellaneous topics in Maxillofacial Rehabilitation		
15:50-16:20	Effect of early stage dent-maxillary prosthesis in the rehabilitation of maxillectomy patients	Takahiro Ono, Osaka University Graduate School of Dentistry, Japan
16:20-16:30	The impact of oral rehabilitation on head and neck cancer patients by Liverpool oral rehabilitation questionnaire (LORQv3) along with oral health impact profile (OHIP-14)	Gunjan Chouksey, Tata Memorial Hospital, India
16:30-16:40	Meticulous reconstruction of oral and maxillofacial soft tissue defects after tumor ablation — the principle, method, and reconstructive efficacy	Hanjiang Wu, The Second Xiangya Hospital, Central South University, China
16:40-16:50	Unique prosthetic support for the extended oncologic team members	James A. Kelly, Mayo Clinic College of Medicine, USA

16:50-17:00	Correction of mandibular deviation by combination therapy of maxillary ramp prosthesis (MRP) and mandibular guide flange prosthesis (MGFP) in mandibular defect case.	Nafij Bin Jamayet, School of Dental Science, Universiti Sains Malaysia, Malaysia
17:00-17:10	Saving faces changing lives	Bilal Ahmed, National University of Science & Technology (NUST), Islamabad. Pakistan
18:30-22:00	**Elective Social Outing / Xi'an night tour (Fee required, please contact the local travel agency onsite)**	

17-Sept-2014

	Chair: Hongjun Ai & James A. Kelly	
8:30- 9:00	Microbial adhesion to maxillary obturator prostheses	Karl Lyons, University of Otago, New Zealand
9:00- 9:10	Improvement of swallowing and articulation by using palatal augmentation prosthesis in a semi-total glossectomy patient.	Yoshitomo Minagi, Osaka University Graduate School of Dentistry, Japan
9:10- 9:20	The 3-stage therapeutic process of a sequence obturators for maxillectomy: a case report	Yan Li, GuanghuaShool of Stomatology, Hospital of Stomatology, Sun Yat-Sen University, China
9:20- 9:30	Three-dimensional Finite Element Analysis of Obturator Retained with Anterior Attachment in Maxilloectomy Patients	Yanyi Wang, Chinese PLA General Hospital, China
9:30- 9:40	NAM appliance design utilizing a new geometric format	Jeff Rodney (Present by Ting-Ling Chang) University of Michigan, USA
9:40- 9:50	The clinical experience of the oral prosthodontic treatment in cleft lip and palate patients	Guofang Xing, 9th People' Hospital, Shanghai JiaoTong University School of Medicine, China
9:50-10:00	Maxillofacial rehabilitation – challenges and opportunities	Bhaskar Agarwal, King George's Medical University, India

10:00-10:15	Coffee break	
	Chair: Yan Li & Karl Lyons	
Session V – Chemo-radiation – Morbidities and strategies to minimize them		
10:15-11:00	Head and neck cancer therapy. Oral complications and potential management techniques.	Eric C. Sung, University of California, Los Angeles, USA
11:00-11:10	Multifunctional nanoparticles based on molecular recognition for cancer cell targeting and traceable intracellular drug delivery	Guolin Li, The First Affiliated Hospital of Harbin Medical University, China
11:10-11:20	Effect of radiotherapy and chemotherapy on the quality of life in nasopharyngeal carcinoma patients: A pilot study	Khim H Teoh, National Dental Centre, Singapore
11:20-11:30	The negative effects of postoperative radiation on the rehabilitation of maxillary defect patients	Weihong Ren, Capital Medical University, China
11:30-12:10	Closing remarks –Prof. Yimin. Zhao and Prof. John Beumer III	
12:10-13:30	Lunch (Fee required)	
13:30-15:00	**Visiting School of Stomatology, Fourth Military Medical University (Free of charge)**	

Workshop
14:00 – 17:00
• "Use of Advanced Digital Technologies in restoration of facial defects" – Combined lecture and hands on lab
Instructors – Dr. Shizhu Bai, FMMU, China (Site – FMMU,13:30 boarding bus on the Sofitel hotel gate, registration required)

LECTURE ABSTRACTS LIST

Abstract	Author	Title
1	Zhao Yimin	Digital Time in the Maxillofacial Rehabilitation
2	Harry Reintsema	Overdentures on Primary Mandibular Implants in Patients with Oral Cancer: a Follow-up Study Over 14 Years
3	Sudarat Kiat-amnuay	Color Stability of Silicone Maxillofacial Elastomers: A Summary of 15-Year Research Experience
4	Balasubramanian Srinivasan	Maxillofacial Rehab Marching Ahead in India: 2006-2014 Experience
5	Ding Ruiying	The Diagnosis and Treatment of Dysphagia
6	Robert Taft , Gerald T Grant	Digital Technologies in Maxillofacial Rehab and Reconstructive Surgery
7	Young-Bum Park	Implant System Using Precision Surgical Guide for Maxillofacial Prosthesis
8	Zhang Chenping	Microsurgical Free Flap Reconstructionsof Head and Neck Region: Shanghai Experience of 34 years
9	Joji George Sekine	Dental Implant for Oral Tumor Patients
10	Sun Jian	Functional Reconstruction Maxillary Defects After Ablative Surgery
11	Arun Sharma	Implants for Pediatric Patients: Growth and Implant Placement
12	Ben Wu	Recent Advances in Craniomaxillofacial Tissue Engineering
13	Takahiro Ono	Effect of Early Stage Dent-maxillary Prosthesis in the Rehabilitation of Maxillectomy Patients
14	Karl Lyons	Microbial Adhesion to Maxillary Obturator Prostheses
15	Eric Sung	Head and Neck Cancer Therapy. Oral Complications and Potential Management Techniques..
16	Cai Zhigang	Development and Progress of Craniomaxillofacial Reconstruction
17	Swati Jindal	Direct 3D Printing of Silicone
18	Jiao Ting	Rehabilitation of Maxillectomy Defects with CAD-RP Obturator Prostheses: A Pilot Study
19	Wu Guofeng	Digital Clinical Solution of Presurgical Nasoalveolar Molding (PNAM) for Infant Clefts in FMMU

20	Ben Omondi	Combined Prosthodontic and Surgical Management of Patients with Amelogenesis Imperfecta: Case Series of Two Patients
21	Lin Bo	Preoperative Percutaneous Nerve Mapping of the Mandibular Marginal Branch of the Facial Nerve
22	Gu Xiaoyu	Digital Technology Used in Rehabilitation of Maxillofacial Defects
23	Ho Beom Kwon	Development of the Combined Finite-element and Rigid-body Analysis Model for the Maxillofacial Prosthodontics
24	Ye Hongqiang	The Evaluation of Measurement Accuracy of Two Different 3D Face-scanner on Healthy Human Faces
25	Bai Shizhu	Application of Computer Aided Technique in the Rehabilitation of Complicate Oral-Maxillofacial Defect and Deform
26	Yang Sefei	A Case of Fixed Prosthesis with Autologous Ilium Bone Free Graft Auxiliary GBR to Restore Severe Defects of Maxillary
27	Liao Guiqing	Immediate Implant-retained Prosthesis Following Radicalmaxillectomy
28	GaoYan	Effects of Titanium-nanotubes Surface Modified by Estrogen-loaded Solid Lipid Nano-particles: An Invitro Study
29	Jay Jayanetti	The Use of Zygomaticus Implants in the Compromised Patient: Review and Patient Report
30	Tang Chunbo	Implant-Supported Intraoral Prostheses Retained by Bar-Clip Attachment Following Distraction Osteogenesis after Block Resection of Mandible in A Case of Squamous Cell Carcinoma of the Floor of the Mouth
31	Chen Songling	Fabrication of Surgical Templates for Orbital Implant Placements and Orbital Rehabilitation
32	Wei Jianhua	ALT Flap in the Reconstruction of Defects in Head and Neck Region
33	Kerstin Bergstrom	35 Years with Osseointegrated Facial Prostheses – History & Developments
34	Zhang Lei	Preliminary Analysis on Free Flap Re-exploration– Beijing's Experience
35	VojkanLazić	Facial Prostheses Retained on Basally Osseointegrated Implants (BOI)
36	Fang Wei	Long-term Result of Reconstruction of Mandible Continuity with Fibula Free Flap and Implant Borne Dental Rehabilitation
37	PC Jacob	Sub-periosteal Dissection with Denture-Guided Secondary Epithelialization: Case Sereis of A Novel

		Method for Peri-Implant Tissue Managementin Reconstructed Mandibles
38	Zhou Yongsheng	Cell Homing Strategy For Bone Tissue Engineering Based on the Cooperative Actions of Simvastatin and SDF-1α-a Potential Application in Maxillofacial Rehabilitation
39	Wang Fang	Human Freeze-dried Dentin Matrix As a Biologically Active Scaffold for Tooth Tissue Engineering
40	Vijayalekshmi Manju	Comparison of Tissue Engineered Bone Substitutes for Native Bone Augmentation -An in Vivo Study
41	Qin Haiyan	Mechanism of Human Oralfacial Fibro-osseous Disease and in Vivo Mouse Model Development Based on Disease-specific iPSCs
42	Lu Wei	The Effect of a Novel HDAC3-selective Inhibitor on Osteogenic Induction of Human Adipose Derived Stem Cells
43	Sa Yue	Physicochemical Propertiesand in Vitromineralization of Porous Polymethylmethacrylatecement Loaded with Calcium Phosphate Particles for Bone Reconstruction
44	Teng Wei	Study on Cnstruction and Biological Effects of Lipopolysaccharide-amine Nano-polymersomes/ Hyaluronic Acid Polyelectrolyte Films on Titanium Surface
45	KanchanDholam	The Impact of Oral Rehabilitation on Head and Neck Cancer Patients by Liverpool Oral Rehabilitation Questionnaire (LORQv3) Along with Oral Health Impact Profile (OHIP-14)
46	Wu HanJiang	Meticulous Reconstruction of Oral and Maxillofacial Soft Tissue Defects After Tumor Ablation—the Principle, Method, and Reconstructive Efficacy
47	James A. Kelly	Unique Prosthetic Support for the Extended Oncologic Team Members
48	Nafij Bin Jamayet	Correction of Mandibular Deviation by Combination Therapy of Maxillary Ramp Prosthesis (MRP) and Mandibular Guide Flange Prosthesis (MGFP) in Mandibular Defect Case
49	Bilal Ahmed	Saving Faces Changing Lives
50	Yoshitomo Minagi	Improvement of Swallowing and Articulation by Using Palatal Augmentation Prosthesis in a Semi-total Glossectomy Patient
51	Li Yan	The 3-stage Therapeutic Process of a Sequence Obturators for Maxillectomy: a Case Report
52	Chu Xiaoyang	Three-dimensional Finite Element Analysis of Obturator Retained with Anterior Attachment in Maxilloectomy Patients
53	Jeff Rodne	NAM Appliance Design Utilizing A New Geometric Format

54	Xing Guofang	The Clinical Experience of the Oral Prosthodontic Treatment in Cleft Lip and Palate Patients
55	Bhaskar Agarwal	Maxillofacial Rehabilitation – Challenges and Opportunities
56	Li Guolin	Multifunctional Nanoparticles Based on Molecular Recognition for Cancer Cell Targeting and Traceable Intracellular Drug Delivery
57	Teoh KH	Effect of Radiotherapy and Chemotherapy on the Quality of Life in Nasopharyngeal Carcinoma Patients: A Pilot Study
58	Ren Weihong	The Clinic Observation of the Affection of Postoperative Radiation Therapy on the Rehabilitation of Maxillary Defect Patients

POSTER ABSTRACTS LIST

Session I – Advanced Digital Technologies and Maxillofacial Rehabilitation

1	Yan Haixin	Rehabilitation of Prefabricated Hollow Obturator Prosthesis in Maxillary Sinus Carcinoma Operation：11 Cases Report
2	Didier Maurice	Computerized Project for Reconstruction Surgery, Implantology and Prosthetic Rehabilitation in Mandibular Defect
3	Dai Tong	The Clinical Application of Computer-aided Designing and Manufacturing of Defected Maxilla Cast
4	Gu Bin	Effects of Three Types of Veneering Porcelain on Bending Strength of KAVO™ Y-TZP/porcelain Bilayered Structure
5	Feng Xin	Comparative Analysis of the Upper Airway Volume Using Lateral Cephalogram and Cone-beam Computed Tomography
6	Jing Qiu	The Study of Computer-aided Design for a Facial Prosthesis Using Three-dimensional (3D) Registration Technology
7	LI Binghong	Magfit-attachment-linked Sectional Obsturator and Prosthesis for Maxillary Defects and Placket Restricted
8	Li Chuanjie	Retrospective Clinical Study on the Application of Magnetic Attachment in Maxillofacial Prosthesis
9	Elbashti Mahmoud	Acoustic Characteristics of Vowels in Trismus Simulated Condition
10	Li Zhimin	Application Value Comparision of Cone Bean CT and Spiral CT in Jaw Defect Three-dimensional Reconstruction
11	Liao Muying	The Three－dimensional Finite Elements Analysis of Different Rate of Clinical Crown－Root and Width of Marginal Alveolar Bone of Maxillary Central Incisor
12	Sun Bin	Application of Computer-Assisted Design and 3D-model in mandibular reconstruction by free fibular flap
13	Sun Jian	Biomechanical Design and Fabrication of the Model of the Individual Mandibular Titanium Framework
14	Shang Wei	Clinical Application of Submental Island Flap on Repairing Oropharynx Defects after Cancer Ablation
15	Zheng Yaqi	Pre-surgical Nasal Molding for Infants with Unilateral Cleft Lip and Palate Using Multiple Digital Techniques

16	Zhou Yongsheng	Acquisition of 3-dimensional Digital Models of Maxillary Defects Based on Multisource Data
17	Hou Yuezhong	Inflatable Hollow Obturator Prostheses for Patients Undergoing an Extensive Maxillectomy
18	Liang Yujie	Mandible Reconstruction Assisted by Preoperative Simulation and Transferring Templates: Cadaveric Study of Accuracy
19	Zhang GS	Mandible Reconstruction Assisted by Preoperative Virtual Surgical Simulation
20	Zheng Guangsen	Mandibular Reconstruction Assisted by Preoperative Simulation and Accurate Transferring Templates: Preliminary Report of Clinical Application
21	Huang Zhi	Novel Method of Fabricating Individual Trays for Maxillectomy Patients by Computer-Aided Design and Rapid Prototyping.
22	Xie Rui	The Significance of NHP to the Orbital Prosthesis Fabricated by Computer-aided Design and Computer-aided Manufacturing (CAD/CAM)
23	Gao Rui	Dose Study of LDCT Application to Reconstruct 3D Model of the Maxillofacial Hard and Soft Tissues
24	Zhang Leiqing	3D Printing Technology and Its Application in Oral and Maxillofacial Treatment
25	Wang Bo	Computed Tomography Measurement of the Auricle in Han Population of North China
26	Dong Yu	A Pilot Study on the Orientation of 3-dimensional Facial Images to Natural Head Position (NHP)

Session II – Implants and Maxillofacial Rehabilitation

1	Arun Sharma	The UCSF Experience with Zygomatic Implants for Maxillary Defects
2	Gassino G	Facial Defects: Alteration at Surgery to Enhance the Prosthetic Prognosis
3	Lee Bora	Rehabilitation of Patients with Reconstructed Mandible Using Implant-supported Prostheses
4	Chen Cheng	Application of Implant-supported Overdenture with Locator Attachment in an Edentulous Patient after Hemimaxillectomy: a Case Report
5	Wang Chen	The Application of Silicone Lining Obturator in Single Maxillary Prostheses
6	Yan Fei	The Effect of Different Root Canal Internal Surface Treatment on Bond Strength of Quartz Fiber Post
7	Bassi F	Post Rhinectomy Rehabilitation by Means of an Epithesis
8	Liao Guiqing	Immediate Implant-retained Prosthesis Following Radical Maxillectomy
9	Wei Hongbo	Microporous Pattern Fabricated by Microelectromechanical Systems Improved Fibroblast Functionalities on Titanium Surface
10	Huang Cui	Changes in Serum of Bone Regeneration of Antibacterial Nanocomposite Membrane in vivo
11	Sharad Gupta	Osseointegrated Implants Supported Bar and O-ring Combination Prosthesis post Mandibular Resection
12	Ma Kena	Synthesis and Properties of Sr/CS/G Coatings Fabricated via Electrophoretic Deposition
13	Hu Jian	Application of Obturator Combining Casting Frame in Cystic Lesions of the Jaws
14	Li Ming	Using the Folded Fibula Flap and Dental Implants to Repair Mandibular Defects at the Same Period
15	Liu Xiaofang	Clinical Evaluation of Prostheses Retained by Tooth-implant and Natural Teeth Combined with Extracoronal Magnetic Attachments for Unilateral Mandibular Defects
16	Liu Changying	To Reconstruct Attached Soft Tissue around Dental Implants by Acelluar Dermal Matrix Grafts and Resin Splint
17	Ma Pan	The Pickup Technique Combined with Surgical Guide Template on the Immediate Fixed Restoration in the Rehabilitation of Complete Edentulous Jaws
18	Wu Yiqun	Functional Reconstruction of Maxillary Defect with Zygomatic and Conventional Dental Implants after Tumor Resection
19	Liao Guiqing	Reconstructed the Completed Mandible Defect with Bilateral Fibula Grafts and Dental Implantation
20	Neal Garrett	Efficacy of Implant-supported Maxillofacial Prosthetics
21	Nicholas Goetz	Use of Implants to Retain Facial Prostheses: the UCLA Experience.

22	Paolo Pera	Pulsed Electromagnetic Fields Effects on Swelling and Pain after Implant Surgery: a Double-blind, Randomized Study
23	Shan Xiaofeng	Mandibular Defect Reconstruction with Fibula Flap and Non-vascularized Fibula Bone
24	Song Guangbao	4 Implant-supported Bridge for Mandibular Defects with Vascularized Fibular Osteomyocutaneous Flap
25	Tetsuo Ohyama	The Effectiveness of Implant Overdenture Treatment for the Severe Bone Resorption case
26	Wang Ying	The Effect of Different Doses of Radiation on the Rat Osteoblasts in Vitro
27	Xu Shulan	Study of Coralline Hydroxyapatite Blocks Used in Reconstructing Alveolar Bone Height in Posterior Mandible
28	Xuan Yue	Review of Implant Outcomes on Fibula Free-flap Reconstruction for the Resected Mandible
29	Wang Yichen	Effect of Pore Size and Porosity on Cytocompatibility of Porous NiTi Alloys
30	Zhang Lei	Survival, Functions, and Complications of Oral Implants Placed in Bone Flaps in Jaws Rehabilitation-a Systematic Review
31	Zheng Jie	A Clinical Evaluation of the Implantodontical Obturator Prostheses for Maxillary Defects
32	Wang Zhongshan	Mussel Adhesive Proteins/ Platelet-rich Plasma Composite-Coated Titanium Surfaces Increased Functionality of Dermal Fibroblasts
33	Zhou Wei	What Type of Implants Used for the Irradiated Bone Is the Better: Zirconia or Titanium Implants?
34	Dong Yan	The Study of Bi-lineage Differentiated ADSCs Sheet to Improve Implant Osseointegration in the Irradiated Bone
35	Ren Nan	Biological Characteristics of Osteogenic and Angiogenic Bi-lineage Differentiated ADSCs Sheet-implant Complex
36	Minati Choudhury	Auricular Rehabilitation Using Early Loaded Intraoral Endosseous Implants: a Case of Bilateral Anotia

Session III - Tissue Engineering and Maxillofacial Rehabilitation

1	Gao Bo	A Novel Nano-Bilayer Collagen/Chitosan Composite Membrane for Guided Bone Regeneration
2	Cheng Lin	Segmental Mandibular Defect Reconstruction Using Prefabricated Bone-implant Grafts or Autogenous Bone Grafts with Simultaneous Implantation: an Experimental Study in Dogs
3	Jiang Hua	Analysis of Brain Activity in Patients with Chewing-Side Preference During Chewing: An FMRI study
4	Liu Jiarong	Comparison of EGF and bFGF Expression in Vivo and Their Effect in Vitro
5	Lu Xuguang	Great Auricular Nerve Grafting in The Treatment of Facial Palsy in Parotid Tumor Surgery
6	Pang Danlin	Effects of Aqueous Areca Nut Extract on The Level of Endothelin-1 Secreted by Endothelial Cells
7	Sharmila Hussain	Morindacitrofolia Enhances Bone Marrow Mesenchymal Stem Cell Proliferation and Facilitates Osteogenesis
8	Zhang Yufeng	Evaluation of a Critical Size Calvarial Defect in the SAMP6 Steoporosis Mouse Model
9	Zhipei Chen	Fabrication and Cell Compatibility Evaluation of Pure Titanium Coated with Sustained Release System of BMP-2/ Biomimetic Calcium Phosphate
10	Zhen Zhang	Electrophoretic Deposition of Amoxicillin Silk Fibroin Coatings for Functionalization of Titanium Surfaces
11	Gou Liming	Effects of Acellular Dermis Matrix for The Prevention of Gustatory Sweating Syndrome After Parotidectomy: A Systematic Review Based on Randomized Controlled Trials
12	Lei Zhang	Preliminary Analysis on Free Flap Re-exploration-Beijing's Experience
13	Dong Xixi	The Effect on Induced Pluripotent Stem Cell of The Extract of Akermanite in Vitro
14	Li Yanan	Comparision of The Effects of Different Occlusal Reconstruction on Partial Mandibular Bone Defect Patients
15	Ding Yumei	IL-22 Mediates Oral Mucosal Wound Healing Via STAT3
16	Ba Ruikai	Cell-bricks Based in Jectable Niche Guided Persistent Ectopic Chondrogenesis of BMSCs and Enabled Nasal Augmentation

Session IV – Miscellaneous topics in Maxillofacial Rehabilitation

1	Abdel Raheem Bibars	Effect of Thixotropic Agent on Physical Properties of Facial Silicone Elastomer
2	Bai Bing	Conventional Prosthodontic Management with Attachment-retained Overdenture in Ⅱ Class Defects of Maxilla Patients
3	Sun ChangFu	Yu's Flap For Lower Lip and Reverse Yu's Flap for Upper Lip Reconstruction: 20 years experience
4	Chen Qiang	The Total Lower Lip Reconstruction after Squamous Cell Carcinoma Resection
5	Liu Yang	Application of Retentive Techniques in The Restoration of Maxillary Defects
6	Fang Su	A Study of Computer Color Matching of Silicone Elastomer Based on Artificial Neural Networks
7	Fumi Yoshioka	Clinical Trial of Novel Silicone Materials for Facial Prostheses
8	Gao Jianyong	Application of Vacuum Sealing Drainage (VSD) in Maxillofacial Complex Wound
9	Gong Zhaojian	Chimeric Flaps Pedicled with Lateral Circumflex Femoral Vessel for Individualized Reconstruction of Through-and-through Oral and Maxillofacial Defects
10	Guo Ling	Application of PFM Crowning Techniques To Restore Multiple Adult Stuck Teeth with Large Scattered Clearance
11	Yang Huochuan	Experience of Clinical Details in Restoration for Unilateral Maxillary Defect with Maxillary Obturator
12	Jee Hwan Kim	Genetic Investigation of Bisphosphonate-Related Osteonecrosis of Jaw (BRONJ) via Whole Exome Sequencing and Bioinformatics
13	Zhang Yufeng	The Protection and Evaluation in Epilepsy Patients after a Fixed Partial Denture
14	JunjieWang	Effect of Cleaning Methods on Mechanical Properties of Prostheses Silicone Rubbers
15	LI Chen	The Reaserch about The Relationship between Three Brand of Zironic Ceramic Trancemittance and Color
16	Li Jichen	Correlation Between Autophagy and Apoptosis in Oral Carcinoma IL-24 Gene Therapy

17	Li Xiaona	Effect of Different Surface Treatments on Bonding of Silicone Elastomer to Acrylic Resin
18	Liang Jie	Preliminary Clinical Study on Application of Computer-Assisted Surgery Technique in Maxillary Defect Reconstruction
19	Liu Bing	High Expression of NBR1 Proteins May Be Associated with Epithelial-mesenchymal Transition (EMT) in Keratocystic odontogenic tumours
20	Lv Linhu	A Survey of Motivation and Psychology of Implant Treatment of 60 or Older Habitant in Panzhihua
21	Ma Yuanyuan	The Expression of Neuropeptide Y Was Regulated by Coticosterone and Acetylcholine Via Respective Receptors in The Osteocytic MLO-Y4 Cells
22	Shigehiro Fujiwara	The Approach of Tongue Pressure Measurement for Making Palatal Augmentation Prosthesis
23	Zou Shiquan	Impression Technique for A Maxillofacial Pass-through Defect with Limitation of Mouth Opening:A Case Report
24	Shogo Ozawa	Contributing Factors for Abutment Teeth Survival on Obturator Prostheses
25	Wu Shuyi	EPCs Transplantation for Microvascular Repair in Irradiated Tissue
26	Yan Tinglin	Molecular Mechanism and Potential Roles of TNF-α-enhanced Fusion between Oral Squamous Cell Carcinoma Cells and Endothelial Cells
27	Tong Ling	Application of the Prosthesis with Titanium Framework and Functional Impressiontechnique in The Reconstruction of The Unilateral Maxillary Defect
28	Wang Lufei	The Role of Sclerostin in Mediating Alveolar Bone Remodeling in Response to Tooth Loss
29	Wang Shaohai	Measurement and Analysis of The Distribution Range of Chroma Values of Healthy Anterior Gingival in Han Population
30	Mo Wenjuan	Effects of A Hindered Amine Light Stabilizer on The Color Stability and Mechnical Properties of Maxillofacial Silicone Elastomer
31	Wu HanJiang	Intraoral Approach for Mandibular Benign Tumor Resection and Mandible Reconstruction with Non-

		vascularized Iliac Graft
32	Wu Junhua	The Role of MiR-136 in Osteocyte Autophagy Activated by Estrogen Deficiency in Ovariectomized Mice
33	Zhang Xueling	Increasing the Success Rate of Impression for Rehabilitation of Maxillofacial Defects with Prostheses through Nursing Care
34	Yamamoto Masaaki	Reconstruction of Hard and Soft Palate Defect with Dysarthria Dyspagia : A Case Report
35	Yang Dezhao	The Activity of Hybrid Vector-mediated Interleukin-24 for Oral Carcinoma Drug Resistant Cells
36	Chao Yi	Evaluation of Using Casting Maxillary Prosthesis to Repair for 9 Patients of The Part of Maxilla Were Excised
37	Han Ying	Measured The Adhesive Properties of ZY-1 and ZY-2 Silicone Rubbers Curing by Steps
38	Zhang Ling	The Most Suitable Aperture Size and Porosity for Porous Titanium Used for Oral Implant: a Meta-Analysis of Clinical Trials
39	Zhang Liuchao	Research Progress on Prenatal Ultrasound in The Diagnosis of Cleft lip and Palate
40	Zhang Xueming	Anatomic Study of The Blood Supply of Oral Mucoperiosteum in Minipig
41	Feng Zhihong	Intrinsic Gene Expression During Regeneration in Maxilla of Salamander
42	Lu Lei	Effect of Nursing Cooperation on Restoration of Maxillary Defect with Hollow Obturator
43	Shen Zhiyuan	Comparative Studies on Tongue Reconstruction after Hemiglossectomy with Forearm Flap Versus Anterolateral Thigh Flap
44	Wang Lei	Nerve Growth Factor-modified Mesenchymal Stem Cells Enhance Recovery of Inferior Alveolar Nerve in Rabbit Mandibular Distraction Osteogenesis
45	Wang Yan	The Experimental Study of Stem Cells on Prevention of Irradiation Injury of Salivary Gland in Mice
46	Cheng Xiaobing	Reconstruction Defects of Maxilla and Palate with Temporalis Muscle Flap after Maxilla Tumor Resection
47	Jia Sen,	BDNF Mediated TrkB Activation Contributes to The EMT Progression in Human Salivary Adenoid Cystic Carcinoma

48	Guo Ling	Application of PFM Crowning Techniques To Restore Multiple Adult Stuck Teeth with Large Scattered Clearance
49	Yan Zhiwei	Comparative Studies on Sensory Recovery in The Radial Forearm Flap Versus Anterolateral Thigh Flap Used for Tongue Reconstruction
50	Yang Tao	Experimental Study on Autologous of Rabbit Adipose-derived Stem Cells Transplantation
51	Wang Weiqi	A Comparison of Health Related Quality of Life between Radial Forearm Free Flap and Pectoralis Major Myocutaneous Flap for Reconstruction in Oral Cancer Patients
52	Xia Zhuo	The Clinical Application of Temperature Molding Wax in The Protheses of Soft Palate Defect
53	Zhang Xiangyu	Factors Influencing The Survival of Nonvascularized Bone Grafts Mandibular Reconstruction
54	Li Chunjie	Large Full-thickness Labial Defects Repaired by Free Flaps: A Case-series
55	Li Tang	Optimal Reconstructive Strategy for Large Facial Defects: A Report of 12 Cases
56	Kunal Parekh	A Case Report: Two Stage Denture Issuance Technique for Fabricating Definitive Prosthesis for Hemi-Maxillectomy Patient.
57	Zhong Laiping	GDF15 Is A Potential Predictive Biomarker for TPF Induction Chemotherapy and Promotes Tumorigenesis and Progression in Oral Squamous Cell Carcinoma
58	Hu Jingzhou	Modified Bilateral Karapandzic Flap for Reconstruction of Large Lip Defect
59	Huang Jian	The Basis of Applicating High-frequency Color Ultrasound in Preoperative Identification and Selection Perforator of Anterolateral Thign Flap
60	JiTong	Functional Evaluation after Mandibular Reconstruction for Oral Cancer Patients
61	Li Jun	Double Barrel Vascularized Fibula Graft in Mandibular Reconstruction: A 10-year Experience with An Algorithm
62	Lv Mingming	Ablative Surgery of Giant Ossifying Fibroma in The Jaws Followed by Immediate Reconstruction: A 10-year Single Institution Experience

63	Mubarak Mashrah	Oral Cavity Reconstruction Using A pedicled Submandibular Gland Flap: A Preliminary Report
64	Qu Xingzhou	State of Art of Post-operative Hemimaxillectomy Rehabilitation: Clinical Evaluation on Prosthesis Supported by Zygoma Implant and Remaining Natural Teeth
65	Shen Shukun	Clinical Data Analysis of 200 Cases of Parotid Gland Tumor
66	Shen Yi	Special Considerations in Virtual Surgical Planning for Secondary Accurate Maxillary Reconstruvtion with Vascularized Fibula Osteomyocutaneous Flap
67	Sun Wenling	Surface Modification of Silicone Rubber by Layer by Layer Assembly Method
68	Ong Huishan	Tendon Sheath Giant Cell Tumor (TSGCT) with Intradural Extension: Utilizing Temporal Bone for Skull Base Reconstruction in Preventing Brain Hernia
69	Wang Liang	Application of Submental Island Flaps for Reconstruction of Oral Maxllofacial Soft Tissue Defects
70	Wang Yan an	Surgical Management of Arteriovenous Malformation in Head and Neck
71	Wang Yang	Illiac Crest Flap Used for Mandibular Reconstruction of Familial Gigantiformcementoma
72	Xu Liqun	Orientation Techniques in Mandibular Reconstruction
73	Yang Wenjun	Versatility of The Composite Lateral Arm-PCNA/PCNF Free Flap in Head and Neck Reconstruction
74	Yang Xi	Clinical Present of Vascular Crisis Salvaged Operations of Free Flap Reconstruction of Head Neck Region in 56 Cases
75	Ye Weimin	Tongue Reconstruction with Tongue Base Island Advancement Flap
76	Manju V	Comparison of Functional Outcomes in Surgically and Prosthetically Rehabilitated Maxillectomy Patients
77	Ma Xiao	Clinical Evaluation of The Effects of Different Retention Systems in Patients with Half-maxillary Defects
78	Li Qiang	Analysis of Cortical Bone on The Mandibular Body in Psychological Stressed Rats by Micro-CT
79	Wang Shuming	Prosthesis-guided Implant Restoration of Auricular Defect Using Computerized Tomography and 3-Dimensional Photographic Imaging Technologies: A Clinical Report

80	Zhang Dapeng	Obturator Restoration of An Extensive Palatal Defect with The Assistance of Intermaxillary Traction: A Clinical Report
81	Han Ying	Mechanical Properties and Color Stability of Nano-oxides Pigmented Maxillofacial Elastomer
82	Na Sijia	Effects of Speech after Partial Glossectomy with Reconstruction Using Radial Forearm Free Flap

Session V – Chemo-radiation – Morbidities and strategies to minimize them

1	Yen Chiangting	The effect of X- rays on infraorbital nerve of rabbits
2	Lin Chongxiang	Reconstruction of the cranio-maxiilofacial soft tissue defection with vascularized free rectus abdominis musculocutaneous flap and scalp expansion: a case report
3	Elisabetta Bellia	Evaluation of oral health before and after radiotherapy in patients undergoing a protocol of dental hygiene.
4	Paramjot Kaur Ghotra	Assessment of Shoulder and Neck dysfunction and Functional status Post radiotherapy/chemotherapy in Head and Neck Cancer patients: A Pilot Study
5	Li Xiao	PH-Responsive Micelles Constructed by PCL-PEG-PCL Triblock Polymer via Oxime Linkage for Anticancer Drug Delivery
6	Liu Bing	Sequential Release Chemotherapeutic Drug with Polymeric Delivery System for Oral Squamous Cell Carcinoma Therapy
7	Zhu Yun	A study of postoperative radiotherapy effects on vascularized nerve graft for facial nerve repair in a rabbit model
8	Parisa Shahi	Implants in irradiated tissues
9	Wei Zening	Clinical Analysis of two removable prosthetic material to repair the unilateral maxillary defect.
10	YL Seetoh	Dosimetric distribution to tooth-bearing regions and osteoradionecrosis following intensity-modulated radiation therapy for oropharyngeal cancer
11	Tian Min	Dental implant survival in irradiated maxilla: a systematic review of the literature

WORKSHOP

The following workshop will be held at Education Center,

School of Stomatology, the Fourth Military Medical University

Workshop time: 2:00pm-5:30pm

Workshop is an elective and requires a fee

Workshop Title:

Use of Advanced Digital Technologies in restoration of facial defects

Members limited to 20.

Special requiements for the above workshop: None.

Description of workshop: a.Design of nasal and auricular prosthesis in specific software.b.Design of eyelid, wrinkle and skin texture of prosthesis with Freeform Modeling System.c.Surgicial simulation of tumorectomy and reconstruction of jaw with Synthes ProPlan CMF.

INVITED SPEAKER

Yimin Zhao, D.D.S, Ph.D
Honorary President of ISMR
President of CSOMR
President, the Fourth Military Medical University
Professor, School of Stomatology,
Fourth Military Medical University,
Xi'an, China

Prof. Yimin Zhao is President of the Fourth Military Medical University. He is professor of prosthodontics and is a visiting professor of School of Dentistry, University of California, USA. Prof. Yimin Zhao is the founder of Chinese Society of Oral Maxillofacial Rehabilitation (SCOMR). Due to his great contribution Prof. Yimin Zhao is elected to be the honorary president of International Society for Maxillofacial Rehebilitation (ISMR) and president of the 2014 ISMR Xi'an Conference. He also serves as vice president of Chinese Stomatological Association, chairman of Stomatological Society of Chinese People's Liberation Army and president of Shaanxi Stomatological Association and vice chairman of Chinese Prosthodontic Society. His research interests include the digital restoration for maxillofacial defects, material of prosthetic silicone and tissue engineering of facial organs. Prof. Yimin Zhao wrote the first Chinese textbook for maxillofacial prosthetics and is the most famous leader of this field in China.

Harry Reintsema, D.D.S, Ph.D
Maxillofacial ProsthodontistHead of Center for Special Dental Care and Maxillofacial Prosthetics Dept for Oral and Maxillofacial Surgery University Medical Centre Groningen : University of Groningen
Groningen, Netherlands

Dr. Harry Reintsema graduated from Dental School in Groningen, The Netherlands in 1982 and defended his PhD-thesis in 1988. He is working as a dentist / maxillofacial prosthodontist since 1984, and is head of the UMCG Center for Special Dental Care and Maxillofacial Prosthetics since 2003. His fields of interest concern e.g. the dental / prosthetic treatment of Head-and-Neck Oncology patients and patients with congenital or acquired orofacial defects, and dental (implant-) treatment in general. He is (co-)author of several articles and books on implant dentistry and maxillofacial prosthetics, and has participated in the organization of several conferences and workshops on maxillofacial rehabilitation subjects.He has served on the board of the Dutch Society for Gnathology and Prosthetic Dentistry (NVGPT) from 1992- 2002 and is member of the International Society for Maxillofacial Rehabilitation (ISMR) executive council since 2007 (vice president since 2010, president since 2013).



Sudarat Kiat-amnuay, D.D.S, MS,
Fellow of ACP
Fellow of AAMP
University of Texas School of Dentistry at Houston,USA

Dr. Sudarat Kiat-amnuay holds academic appointments as a tenured Professor and Director of Advanced Education in General Dentistry Residency Program, University of Texas School of Dentistry at Houston, USA. She is a Diplomate of the American Board of Prosthodontics and the American Board of Clinical Anaplastology. She graduated DDS with Honors from KhonKaen University, Thailand. She completed anAdvanced Education in Prosthodontic ResidencyProgram and earned a Master's Degree in Oral biology from the University of Louisville, Kentucky. She also completed a fellowship program in Maxillofacial Prosthetics and Dental Oncology from the University of Texas M. D. Anderson Cancer Center in Houston. She is currently a fellow of the American Academy of Maxillofacial Prosthetics, American College of Prosthodontists, International Congress of Oral Implantologist, and International Academy of Oral Oncology. She has received over 40 teaching and research awards and published over 60 abstracts, 31 peer-reviewed journal articles, and contributed to 2 book chapters. She is a principal and co-principal investigator of 27 grants including two 5-year-funded from the National Institute of Health and HSRA, USA. Her research focuses in the maxillofacial prosthetic field are on color stability and mechanical properties and randomized controlled clinical trialof maxillofacial prosthetic elastomers.

Balasubramanian Srinivasan, D.D.S
Enhance Head Neck Rehabilitation, Pune, India

Dr B.Srinivasan is a Maxillofacial Prosthodontist at the Ruby Hall Cancer Centre.An alumnus of Govt. Dental College & Hospital, Mumbai, he began his career in Maxillofacial Prosthodontics at the Tata Memorial Hospital, Mumbai. He was a recipient of the F.D.Mirza award for paper presentation at successive national conferences of the Indian Prosthodontic Society in 2001 and 2002 respectively.

He is a recipient of International Fellowships from the UICC to pursue advanced training in Maxillofacial Prosthodontics in The Netherlands (2006) and Sweden(2008) and Implants in the Netherlands (2013). He was showcased as "Member of the Month" by the Swiss based International Union against Control of Cancer in May 2008.

He has to his credit, presentations at both the national and international fora and also harbours research interests.He is one of the initiators of the "Poona Head and Neck Group" in 2009,a multidisciplinary study group, to propagate the philosophy of Team Work in Patient Care.He is a member of the Executive Committee of the Indian Prosthodontic Society,Section Editor of the Journal of Indian Prosthodontic Society and a committee member in the International Society for Maxillofacial Rehabilitation.He is the Chief Executive of Enhance Head Neck Rehabilitation LLP,an organisation founded by him to make maxillofacial prosthetics and rehabilitation affordable and accessible.

Recently,his case report on customised ocular prosthesis has been published and acknowledged in the book Maxillofacial Rehabilitation: Surgical and Prosthodontic Management of Cancer-Related Acquired, and Congenital Defects of the Head and Neck by Dr John Beumer III, Mark T. Marunick , Salvatore J. Esposito

Ruiying Ding, Ph.D
Elmhurst College,USA

Dr. Ruiying Ding received her bachelor, mastor and Ph.D. degrees from Northwestern University. She has been an associate professor in Department of Communication Sciences and Disorders at Elmhurst College since Sep 2012. Prior to Elmhurst College, she worked as an associate professor at University of Wisconsin-Whitewater and as a speech-language pathologist in hospital, rehabilitation center, outpatient clinic and long term care facilities.

Dr. Ding has published research articles in nationally and internationally renowned journals, including: Journal of Speech Language Hearing Research, Dysphagia, Head & Neck, Journal of Folia Phoniatrica et Logopaedica, Chinese Journal of Rehabilitation Theory and Practiceand Chinese Journal of Stroke. She also published several book chapters in dysphagia evaluation and treatment in three medical speech and language therapy textbooks.

She has presented extensively in state, national and international conferences, including annual convention of ASHA, Wisconsin Speech-Language-Hearing Association, First and Second China International conference as well as Symposium of Clinical Education in Speech Pathology in several hospital settings.

Dr. Ding served as Journal reviewer for Dysphagia and Head and Neck Medicine. She also served as grant reviewer for ASHA's SPARC award (Students Preparing for Academic & Research Careers). She is the editor for The Communication Connection Journal, the official journal of the Wisconsin Speech-Language-Hearing Association. In 2008 she was elected the Vice President of Communication in the Wisconsin Speech-Language-Hearing Association. She is also an adjunct professor in East China Normal University and Shanghai University of Traditional Chinese Medicine, two renowned universities in Shanghai, China.

Gerald T. Grant, DMD, MS
Naval Postgraduate Dental School, USA

Captain Gerald Grant received his D.M.D. degree from the University of Louisville, School of Dentistry in 1985, a certificate in Prosthodontics from the Naval Postgraduate Dental School, Bethesda, MD and a Masters from George Washington University in 1995, and a certificate in Maxillofacial Prosthetics from the Naval Postgraduate Dental School in 1999. He is a Diplomat of the American Board of Prosthodontics. Captain Grant served as Chairman and Program Director for the Maxillofacial Prosthodontics Fellowship Officer program, Naval Postgraduate Dental School and Specialty Leader to the Surgeon General for Maxillofacial Prosthetics and Implant Dentistry from 2004 to 2009. Heholds academic positions as an associate professor at the Uniform Services Health Science University,adjunct associate professor at Johns Hopkins University School of Medicine department of Plastic Surgery, the Director of Craniofacial Imaging research atthe Naval Postgraduate Dental School (NPDS) and the Service Chief of the 3D Medical Applications Center, Department of Radiology, Walter Reed National Military Medical Center.

Captain Grant was awarded the John J. Sherry Award for Dental Research from the American college of Prosthodontics and the International Association of Dental Research's Fuchette International Research Award for his research and the Major General Bill B. Lefler Federal Services Award from the American College of Prosthodontics for his contributions to military medicine for his efforts with virtual surgical craniofacial reconstructions, digital imaging and additive manufacturing techniques for surgical guides and custom implants.

Captain Grant's research area is in Craniofacial Capture of hard and soft tissue for use in virtual treatment planning, surgical guide techniques, and fabrication of custom implants using additive manufacturing, and CAD/CAM mold design for silicone facial prostheses. His present endeavors are in the area of computer generated forensic reconstruction, facial reconstruction, design of custom Ti implants, and biomaterials for additive manufacturing. His team is a part of the Armed Forces Institute of Regenerative medicine, and has research studies with the FBI, Smithsonian, and several universities in and out of the United States.

Captain Robert M. Taft
Naval Postgraduate Dental School, USA

Captain Taft was born and grew up in Littleneck Long Island, New York. He received his D.D.S. degree from Emory University School of Dentistry in 1983. He entered the Navy in 1983 following graduation and was commissioned a Lieutenant in the U. S. Navy Dental Corps.

Following graduation, Captain Taft's first duty station was a one-year general practice residency at PortsmouthNavalHospital, PortsmouthVa.In July of 1984 he reported to Naval Station San Miguel in the Philippines as Department Head for Dental Services. His next duty station was at Naval Air Station Brunswick, Maine, where he served as the Prosthodontic and Division Officer.In 1988, Captain Taft entered the Prosthodontic residency program at the Naval Postgraduate School in Bethesda, MD and two years later received a certificate. He stayed on staff in the Prosthodontic Department as the Laboratory Officer and Head of Fixed Prosthdontics. Captain Taft then continued in a fellowship in Maxillofacial Prosthetics at Wilford Hall USAF Medical Center, San Antonio, TX receiving a certificate in 1992. Following his specialty training, Captain Taft served in various positions at Naval Medical Center San Diego, CA. Captain Taft next served as Chairman and Program Director for the Maxillofacial Fellowship Officer program, Naval Postgraduate Dental School from 1997 – 2001 and later as professor in the Naval Postgraduate Prosthodontics Residency Program, 2002. He then took assignment at the Navy Medicine Education and Training Command, Bethesda, MD, as Director, Graduate programs and was the Medical Joint-Service Education Director, for the 2005 BRAC process. Captain Taft served as Dean of the Naval Postgraduate Dental School and Specialty Leader to the Surgeon General for Postgraduate Dental Education from June 2006 to June 2011, Deputy Chief, United States Navy Dental Corps from June 2011 to June 2013 and is currently Department Chair, Prosthodontics, Naval Postgraduate Dental School. Captain Taft is a Diplomate, Board Examiner and Secretary/Treasurer of the American Board of Prosthodontics, Fellow/BOD member of the American College of Prothodontists, Associate Fellow, Academy of Prosthodontics, Immediate past President of the American Academy of Maxillofacial Prostheticsand past Specialty Leader to the Surgeon General for Maxillofacial Prosthetics and Implant Dentistry. His personal awards include twoLegions of Merit, three Meritorious Service medals, two Navy Commendation medals and two Navy and Marine Corps Achievement medals.

YoungBum Park, DDS, PhD
Department of Prosthodontics, Yonsei University College of Dentistry
Seoul, Republic of Korea

2013. 03- Current: Associate Professor, Yonsei University College of Dentistry
2011.03-2013. 02: Clinical Associate Professor, Yonsei University College of Dentistry
2009. 03-2011. 02: Clinical Assistant Professor, Yonsei University College of Dentistry
2007-2009: Visiting Instructor in Oral Biology, State University of New York at Buffalo, NY, USA
2007-2008: Clinical Assistant Professor in Periodontics and Endodontics, State University of New York at Buffalo, NY, USA
2003-2006: Visiting Instructor and Resident in Periodontics and Endodontics, State University of New York at Buffalo, NY, USA
1999-2002: Prosthodontist, Yeoju Public Health Center (for Military Service), KOREA
1996-1999: Resident in Prosthodontics, Yonsei University College of Dentistry
PhD: 2009.06, State University of New York at Buffalo, NY, USA/Oral Biology
Master: 2006.02, State University of New York at Buffalo, NY, USA/Oral Science
DDS: 1995.02, Yonsei University College of Dentistry, Seoul, S. Korea/Dentistry



Professor Zhang Chenping, MD, DDS, FRCS
The Ninth Affiliated Hospital, Shanghai Jiao Tong University, China

He is specialized in diagnosis and treatment of oral & maxillofacial and head & neck neoplasm, especially in for functional mandible reconstruction. He was appointed as Council of International Academician of Oral Cancer, Director of IAOMS Oral and Maxillofacial Oncology and Reconstructive Surgery Training Fellowship Program, Academician of Royal College of Surgeons of Edinburgh, UK.As the first accomplisher, he has been awarded First Award for Science and Technology Advancement from Shanghai Municipality in 2010, Chinese Medical Science Prize and other 9 important awards. He has published 12 monographs as editor including two as Editor-in-Chief. He has acquired 15 research grants including Major Program of Shanghai Municipal Science and Technology Commission, Project Supported by National Natural Science Foundation of China. He has published 226 scientific papers, 30 of them are cited by the Scientific Citation Index as first or corresponding author. He was awarded Shanghai Leading Talents and excellent academic leaders of Shanghai Municipal Science and Technology.

Joji George Sekine, DDS, Ph.D
Department of Oral and Maxillofacial Surgery, Shimane University Faculty of Medicine, Japan

Prof. Sekine graduated from Fukuoka Dental College in 1989, and defended his Ph.D. thesis in 1996 (Nagasaki University). He has been working as as resident, assistant professor and lecturer, Department of Oral and Maxillofacial Surgery, Nagasaki University Hospital from 1989 to 2006. He has been invited to Umeå University, Sweden as a visiting professor for 1 year, and then got a title of professor and chairman of Shimane University in 2007. His speciality is oral cancer and reconstructive surgery including functional oral rehabilitation using dental implant. He is a senior consultant as well as an accredited maxillofacial surgeon, Japanese Society of Oral and Maxillofacial Surgeons, a senior consultant, Japanese Academy of Maxillofacial Implants, a certified cytopathologist, Japanese Society of Clinical Cytology, and a clinical oncologist, Certified by Japanese Board of Cancer Therapy. He was given Research Scholarship Grant and Young Investigator's Award of International College of Surgeons in 2006. His hobby is yachting, photography and business administration.

Sun Jian, MD
The Ninth Affiliated Hospital, Shanghai Jiao Tong University
Shanghai, China,

Professor Sun Jian, MD, graduated from the Stomatological College of Shanghai Second Medical University. He went to France for further study on Head and Neck Tumor and Reconstructive Surgery under the supervision of Professor Jean Louis Blanc and Bernard Devauchelle (1997-1998). Now he serves as the vice director of oral and maxillofacial-head and neck oncology dept. Ninth People's Hospital, Shanghai Jiao Tong University School of Medicine. He is now Director of Cooperative Group of Plastic Reconstructive Surgery, Chinese Society of OMFS, CSA, Vice Director of Division of Tumor Plastic Surgery, Chinese Society of Plastic Surgeons, CSA, and Vice director Division of head and neck cancer, Shanghai Anticancer Association. He is specialized in diagnosis and treatment of oral & maxillofacial and head & neck tumor, in particular for the functional reconstruction and microsurgery, computer aided surgery. He has published more than 100 scientific papers, over 40 being collected in SCI among them. He has published 3 monographs as Editor-in-Chief, 10 books as Vice Editor-in-Chief or Writer. His research on functional maxillary reconstruction of large defect with vascularized fibula flap and titanium mesh won First prize of Science and Technology Progress from Ministry of Education.

Arun B. Sharma, BDS, MSc.
Division of Prosthodontics at the University of California, San Francisco School of Dentistry
SF, USA

Dr. Sharma is a Clinical Professor in the Division of Prosthodontics at the University of California, San Francisco School of Dentistry. Dr. Sharma is a Diplomate of the American Board of Prosthodontics. He maintains a private practice, and is the Assistant Director of the graduate program in prosthodontics at UCSF. Dr. Sharma received his dental degree from the University of Bombay in 1983 and a Masters in Prosthetic Dentistry from the University of London. He then completed a prosthodontic residency from UCSF and a maxillofacial prosthetic residency from UCLA. Dr. Sharma has contributed to three textbooks and authored many articles. He has served as the Assistant Editor of the Journal of Prosthetic Dentistry and is currently the Vice Chair of the Editorial Council of the JPD. He is currently Vice President Elect for the American Prosthodontic Society and a Past President of the Pacific Coast Society for Prosthodontics.

Ben Wu, PhD
School of Dentistry
University of California, Los Angeles
LA, USA

Prof. Ben Wu obtained his residency training in Advanced Prosthodontics at Harvard, and his Ph.D. in Materials Engineering at the Massachusetts Institute of Technology. At MIT, he developed the powder-binder interaction physics for 3D printing of biomedical relevant materials, and published the first papers on 3D Printed drug delivery devices and tissue engineering scaffolds. Prof Wu is currently Professor and Chairman of Division of Advanced Prosthodontics in the UCLA School of Dentistry, and Chairman of the Department of Bioengineering in the UCLA School of Engineering. He is Director of the Weintraub Center for Reconstructive Biotechnology, and holds joint faculty appointment in the Departments of Materials Science and Engineering, and the Department of Orthopedic Surgery. He has published over 140 papers and delivered over 100 lectures in the development of material-based solutions to promote tissue regeneration and wound healing. Dr. Wu provides clinical patient care in the UCLA Faculty Dental Group Practice, and serves on numerous advisory committees in academia and industry.

Takahiro Ono, PhD
Department of Prosthodontics, Gerodontology and Oral Rehabilitation (Graduate School of Dentistry) and the Center for Advanced Medical Engineering and Informatics, Osaka University
Osake, Japan

Dr. Takahiro Ono is an associate professor in the Department of Prosthodontics, Gerodontology and Oral Rehabilitation (Graduate School of Dentistry) and the Center for Advanced Medical Engineering and Informatics, Osaka University. He will be the chief professor in the Division of Comprehensive Prosthodontics, Graduate School of Medical and Dental Sciences, Niigata University from October 2014. He graduated from the Faculty of Dentistry in Hiroshima University and completed Ph.D course of Osaka University Graduate School of Dentistry. He is specialized clinically in a prosthodontic rehabilitation for dysphagic patients including oral cancer patients and neurologic patients, and has done a lot of clinical research works in the field of mastication and swallowing physiology. Currently, he serves as a director of Japanese Academy of Maxillofacial Prosthetics, Japanese Society for Mastication Science and Health Promotion, Japanese Society of Stomatognathic Function, and as a councilor of Japanese Society of Geriatric Dentistry, Japanese Society of Prosthetic Dentistry, and Japanese Society of Dysphagia Rehabilitation. Also, he is a member of European College of Gerodontology and the Society of Oral Physiology. He is the chief investigator of 10 national research grants and section-chief investigator of 2 big five-year national grants. He has published 150 academic papers, contributed to 50 book chapters, and received 10 prizes for distinguished academic paper or activities. Additionlly, he is an editorial board member of Journal of Dental Research, Gerodontology and Oral Oncology.

Karl Lyons, BDS
Faculty of Dentistry at the University of Otago
Otage, New Zealand

Karl is a Professor and Prosthodontist in the Faculty of Dentistry at the University of Otago, in New Zealand where he is currently the Chair in Restorative Dentistry and Head of the Department of Oral Rehabilitation. He completed a BDS, a postgraduate prosthodontics programme and a PhD at the University of Otago and a residency in maxillofacial prosthetics at the University of California, Los Angeles. Karl is involved in undergraduate and postgraduate teaching, has lectured nationally and internationally in various areas of prosthodontics, and is actively involved in prosthodontic research. Karl is a past president of The Australian and New Zealand Academy of Prosthodontists and the New Zealand Association of Prosthodontists and Restorative Dentists and is a past Executive Board Member of the International Society for Maxillofacial Rehabilitation.



Eric C. Sung, DDS
School of Dentistry
University of California, Los Angeles
LA, USA

Dr. Sung received his dental degree at UCLA School of Dentistry. He also completed General Practice Residency at UCLA. Since that time, he has been on staff at Childrens Hospital in Los Angeles, City of Hope National Medical Center, VA Greater Los Angeles Health Care System, Kaiser Permanente, and at UCLA. Currently, Dr. Sung is the program director and chair of UCLA's hospital dentistry program. He is also the vice chair of advanced prosthodontics at UCLA School of Dentistry.

Dr. Sung has lectured nationally and internationally and has multiple publications in peer reviewed.

LECTURE PRESENTATIONS

1

Digital Time in the Maxillofacial Rehabilitation

Zhao Yimin

School of Stomatology, Fourth Military Medical University

Purpose: Maxillofacial defects can not only damage physiological functions of oral cavity, but also result in shattered appearance which often causes severe psychological problems. Therefore, the treatment of maxillofacial defects and deformities needs functional reconstruction of jaw bones and realistic repair of facial defects, by using either surgical approaches or prostheses for which surgeries are not feasible.

Methods: We have been focusing on computer-assisted techniques for the reconstruction and repair of maxillofacial defects and deformities in a series of laboratory research and clinical practice in School of Stomatology at the Fourth Military Medical University. For computer-assisted design and manufacture of realistic facial prostheses, three-dimensional models are manufactured according to the data set of facial surface obtained using the sensing system, followed by designs of prostheses using specific software either by creating a mirror image or selecting matched data in a database of normal nose and ear established by our team. We have developed a novel method to ensure precise designs of facial prostheses with totally free control of margin positions, shape and thickness, etc. We have also established a systemic negative-type design protocol to completely avoid the usage of wax and therefore largely simplify the process of prosthesis manufacture, as well as specific software for the design of facial prostheses for much easier learning.

Results: Using these novel technologies, we have successfully treated more than 100 cases of maxillofacial defects and deformities due to trauma, tumor resection or developmental diseases, with satisfactory results.

Conclusion: Through our dedicated efforts, this method is being improved and used more and more. It is now become one of the routine therapy techniques in our hospital.

2

Overdentures on Primary Mandibular Implants in Patients with Oral Cancer: a Follow-up Study Over 14 Years

Harry Reintsema

UMC Groningen, The Netherlands

Purpose: To assess oral functioning, patients' satisfaction, condition of peri-implant tissues and implant survival in oral cancer patients with mandibular overdentures on primary implants up to 14 years after insertion.

Methods: In a prospective cohort of 164 oral cancer patients endosseous dental implants were inserted in the interforaminal region of the mandible during ablative surgery of the tumour. All patients were evaluated using questionnaires and clinical assessments during a final assessment in 2012.

Results: In 84% of the patients an implant-retained mandibular overdenture was made. Completion of prosthetic rehabilitation and oral functioning was not associated with primary tumour location, number or type of implants inserted, tumour stage and the type of reconstruction used during surgery. Over time, peri-implant mucosa was in general free of inflammation. More implants were lost in irradiated patients (8.5%) than in non-irradiated patients (0.5%). Irradiated patients reported more problems in oral functioning and reported lower satisfaction than non-irradiated patients. Patients with an implant-

retained mandibular overdenture reported fewer problems in oral functioning than patients without an overdenture.

Conclusion: Primary implant insertion in oral cancer patients should be routinely incorporated in the surgical planning as oral functioning in patients wearing mandibular overdentures improves distinctly and peri-implant health is at least reasonable.

Key words: Head and neck cancer; Edentulous; Dental implants; Quality of life; Prosthodontics; Patients' satisfaction.

3

Color Stability of Silicone Maxillofacial Elastomers: A Summary of 15-Year Research Experience

Sudarat Kiat-amnuay

The University of Texas School of Dentistry at Houston

Purpose: To summarize the past 15 years results of color stability studies of silicone maxillofacial elastomers, and the translation of the results to the clinical setting.

Methods: Although the silicone elastomers have been used in the maxillofacial prosthetics field for over half a century, there are still numerous reports of dissatisfaction with color stability, esthetics, and longevity. The result of a global satisfaction quality-of-life test instrument revealed that the restoration of esthetics was the most relevant need of patients who wear facial prostheses and ranked as the greatest problem among all evaluated domains. The final esthetic result and color stability are the most important factors affecting clinical success or failure of maxillofacial prostheses. Color changes have directed most investigations on the color stability of colorants and elastomers.

The presentation will cover a review of most common types of opacifiers, pigments, and silicone elastomers used for fabricate maxillofacial prostheses according to the 2010 survey of currently used materials for fabrication of extraoral maxillofacial prostheses in North America, Europe, Asia and Australia, and a review of their color stability research in related studies. This presentation will also cover the color difference thresholds of maxillofacial skin replications.

Results: Based on the 15-year results of the presenter and her collaborator's laboratory studies, recommendations will be made to help clinicians decide which types of opacifier, pigment, and silicone elastomer combinations create the most color stable prostheses.

Conclusion: The subsequent review will help clinicians fabricate better and more predictable color-stable prostheses, enhancing the quality of life for maxillofacial prosthetic patients.

Key words: Color stability; Maxillofacial prosthetic elastomers; Facial prostheses; Review.

4

Maxillofacial Rehab Marching Ahead in India: 2006-2014 Experience

Balasubramanian Srinivasan

Enhance Head Neck Rehabilitation

Purpose: Advancement of a new speciality calls for not just upgradation of technical knowledge but also overcoming logistical hurdles in order to be able to put the new found technical knowledge to effective use. As a professional technical challenge are far easier to overcome than logistical ones. Effecting a paradigm shift in the minds of people can be a daunting task posing immense challenges. For someone who proposes to initiate a maxillofacial practice, especially in an environment where it has been virtually unheard of, subject knowledge needs to be augmented with a simultaneous plan of action to create an environment to be able to execute it as well.

This presentation is a follow up on the author's earlier presentation at the ISMR Conference at Bangkok in 2008, outlining the strides made in maxillofacial rehabilitation in India over the past 8 years.

Key words: Intrinsic motivation to develop the speciality timely guidance from senior colleagues, sustained efforts and support from a global society as the ISMR can ensure advancement of maxillofacial rehabilitation across the globe.

5

The Diagnosis and Treatment of Dysphagia

Ding Ruiying

Elmhurst College

Videofluoroscopy is a moving x-ray study of swallowing. With this procedure, the examiner is able to determine the duration and completeness of bolus transit as well as the movement patterns of the mandible, tongue, velum, larynx, and to some extent, the pharyngeal wall and upper esophageal sphincter. Also, the symmetry of transport can be observed. Penetration of the material into the laryngeal vestibule and aspiration of the material into the trachea can be observed in this procedure. Patients are given small boluses of varying viscosities in accordance with their level of tolerance. Bolus preparations range from 3 to 20 ml.

This procedure is not simply to determine if a patient is aspirating or even why the patient is aspirating; rather, it helps the clinician determine if a patient can receive sufficient nourishment by mouth for health and recovery, and if there are particular compensatory procedures or particular volumes or viscosities that can help the patient return to oral intake. Based on findings from videofluoroscopy, various swallowing disorders can be diagnosed.

The documentation should include not only the reason for the residue or aspiration, but also the timing of each event and the patient's reaction (or lack thereof) to residue or aspirated material. Finally, the impact of compensatory maneuvers should be investigated and documented. The videofluoroscopic swallowing examination is considered the "gold standard" in the clinical assessment of dysphagia.

Many options exist for behavioral interventions for dysphagia. The goal of the therapy is to reestablish of oral feeding while constantly maintain adequate hydration and nutrition and safe swallowing. The two types of therapy are direct therapy and indirect therapy. Direct therapy is performed when patient is eating including changing food characteristics, patient's positions and special manuvers during eating. Indirect therapy is performed when patient is not yet ready to eat orally. It mostly includes various exercises of the oral, pharyngea and laryngeal structures.

Surgical treatment of the head and neck cancer may remove structures that are important to bolus movement. If structures have been removed, a maxillofacial prosthodontist is a valuable resource. In combination with a speech-language pathologist, a maxillofacial prosthodontist can fabricate palatal lifts, obturators, maxillary shaping devices, or other intraoral prostheses that can contribute to improved swallowing function. A palatal lift helps lift the existing soft palate into a raised position, thus creating improved velopharyngeal closure. An obturator is a device that fills a gap created by surgical resection. If the soft palate is removed, an obturator can be used to facilitate separation of the oral and nasal cavities. A maxillary shaping device is a prosthesis that fits over the hard palate. This device may be thickened or shaped to facilitate maximal contact with a weakened or partially resected tongue. Increased lingual-palatal contact facilitates improved oral bolus transport.

6

Digital Technologies in Maxillofacial Rehab and Reconstructive Surgery

Robert Taft , Gerald T Grant

National Naval Medical Center

The use of advanced digital technologies in maxillofacial reconstruction and rehabilitation will be discussed to include image capture, digital design and use of digital manufacturing technologies. Recent developments and examples used in the current practice of the presenters will be presented.

Objectives:

1. Familiarize the viewer with the conventional method of Maxillofacial Prosthetic Reconstructions
2. Demonstrate the application of advanced digital technologies in Maxillofacial Prosthetic Reconstruction.
3. Identify future reconstruction application using advance digital technologies.

7

Implant System Using Precision Surgical Guide for Maxillofacial Prosthesis

Young-Bum Park

Department of Prosthodontics, Yonsei University College of Dentistry

Purpose: The planning of implant surgery using computed tomography (CT) scans has long been used to improve success of implant. However, this methodology may be jeopardized by unfavorable quality or quantity of bone especially in patient who requires maxillofacial implant surgery due to trauma, cancer and congenital abnormalities. Using short implant designed for maxillofacial application with the aid of virtual planning software program may be considered for more precise and accurate implant planning and for successful implant surgery.

Methods: A 60-year-old male patient with maxillofacial defect around orbit, extended to maxilla and zygomatic bone due to tumor resection, was planned to have two implant fixtures in the supraorbital bone for maxillofacial prosthesis. Prior to implant placement, virtual planning was performed by transferring 3-dimensional (3D) computed tomographic scanning to OnDeman3D (Cybermed Co., Seoul, Korea) software program. Two short maxillofacial implants (Dentium, Seoul, Korea) was successfully installed using pre-designed In2Guide (CyberMed Co., Seoul, Korea) mucosa-supported surgical template.

Results: Implant installation were successfully completed without any clinical complications such as fenestrations, nerve injury, bleeding and other unexpected events. Post-operative clinical assessment and radiograph was taken and confirmed that implants were precisely placed as planned. Abutment with magnet attachment was installed and final maxillofacial prosthesis was delivered to patient.

Conclusion: Implant system with maxillofacial implant based on precision implant surgical guide can be successfully utilized for maxillofacial rehabilitation with enhanced accuracy and reliability.

Key words: Maxillofacial implant; Implant surgical guide; Maxillofacial rehabilitation.

8

Microsurgical Free Flap Reconstructions of Head and Neck Region: Shanghai Experience of 34 years

Zhang Chenping

The Ninth Affiliated Hospital, Shanghai Jiao Tong University

Surgery of Oral cancer was unique so as to its important anatomical structure in head and neck region. Different sites of the oral cancer had own characteristics.

The tissue and functional defect was along with radical surgery. So soft and hard tissue reconstruction was obligatory. Free flap reconstruction was prior in large and complex defect. From 1979 to 2013, 3598 soft free flaps included forearm flap, latissimus dorsi myocutaneous flap, pectoralis major myocutaneous flap (PMMF), anterial lateral thigh flap and lateral arm flap, et al. And 1042 hard free flaps consisted of fibular myocutaneous flap, iliac myocutaneous flap and scapula myocutaneous flap. The successful rate increased from 92% in 1980's to 98.5% nowadays, 96.8％ in average. The forearm flap and fibular was the most common flap in soft and hard tissue reconstruction of the defects. Anterial lateral thigh flap provided us much more flexible choice for reconstruction of the different defects. The fibular flap and DCIA was effective in simultaneous dental implant of patients in mandibular reconstruction.

For tongue defect，the volume restoration was to recover swallowing. For buccal defect, we should pay attention to prevent restriction of mouth opening. The aim of mandibular reconstruction was not only the restoration of mandibular continuity and contour, but also restoration of oral function through the use of dental implants. Dental implant combined with mandibular reconstruction was a real sense of challenge for oral and maxillofacial surgery and oral implantology. In our hospital, only nearly 30% patients of mandible reconstruction had received dental implant and attain nearly normal masticatory function. Dental implant distractor (DID) was used with simultaneous fibular flaps for functional mandibular reconstruction, which has been applied in over 40 cases.

9

Dental Implant for Oral Tumor Patients

Joji George Sekine

Shimane University Faculty of Medicine

Background: Oral tumor surgery can result in a myriad of separate and distinct functional and cosmetic problems. Because of this reconstructive surgery is recommended to improve patients' quality of life. The purpose of reconstruction of oral cavity defects is to facilitate healing, prevent wound breakdown and fistula formation, cover exposed bone with full thickness tissue, and promote normal function and facial esthetics as much as possible. To achieve these results maxillofacial surgeons have a large number of reconstructive options available, including no reconstruction, primary repair with local tissue and the use of local, regional or distant pedicle or free flaps. However, patients who underwent reconstruction of mandibular continuity were left without dentition or were rehabilitated with removable dentures. Our policy to establish treatment goal in oral tumor patients is to achieve functional oral rehabilitation with implant-supported osseointegrated implants or extruding patients' own impacted teeth following anatomical reconstructive surgery.

Aims: The present paper describes our surgical strategy for functional oral rehabilitation using osseointegrated implants following many kinds of bone augmentation procedures. Treatment course of benign odontogenic as well as malignant tumors of the mandible is summarized and discussed.

Methods: The present paper describes the functional oral rehabilitation in 26 oral tumor patients using osseointegrated implants as well as extrusion of impacted teeth. Primary lesions were 12 benign (ameloblastoma and ossifying fibroma, 4 men and 8 women, mean age 30.7-year-old) and 14 malignant tumors (squamous cell carcinoma and mucoepidermoid carcinoma, 6 men and 8 women, mean age 62.2-year-old). Bone defect was reconstructed by free or vascularized bone grafting or distraction

osteogenesis at the same timing or following tumorectomy. Soft tissue defect was also done by pedicled or free flap at the same timing of the primary surgery. Fixtures were placed in the grafted or augmented bone, and abutments were connected 6 to 9 months later together with vestibuloplasty. Mucosal grafts were used to replace the skin flap around abutments. In 2 benign cases, impacted teeth were extruded using orthodontic technique following tumorectomy.

Results: All implants survived during 1 to 19years' follow-up after loading. No tumor recurrence has been seen during the follow-up term.

Conclusion: Dental implant would be feasible to improve the quality of life in patients who are suffering form masticatory disturbance due to tumor surgery.

10

Functional Reconstruction Maxillary Defects After Ablative Surgery

Sun Jian

The Ninth Affiliated Hospital, Shanghai Jiao Tong University

Abstract: Oral and Maxillofacial tumor leads to severe facial malformation and oral dysfunction such as impairment of mastication, articulation, and deglutition. The main purpose of functional oral and maxillofacial surgery is to restore the facial contour and oral function as much as possible. This presentation discusses the issues of functional reconstruction of maxillary defects after ablative surgery in oral tumor. For maxillary reconstruction, vascularized fibula osteomyocutaneous flap is used in class 2 defect according to Brown's classification, vascularized fibula osteomyocutaneous flap and titanium mesh are applied in class 3 defect. Surgical plan and simulative operation of ablative surgery, autologous bone harvest, maxillary reconstruction are all preoperatively made in the computer. According to the result of virtual surgery, the individual replicas of the maxilla and the guide template are made by computer aided manufacturing/computer aided design (CAD/CAM) techniques so that the operation can be performed quickly and accurately.

Maxillary reconstruction: Vascularized fibula osteomyocutaneous flap is applied to perform maxillary reconstruction. The fibula is osteotomied into 2~3 segments to restore the unilateral or bilateral alveolar ridge and pterygomaxillary buttress in patients with class 2 defect. The fibular segments are fixed to contralateral alveolar ridge and ipsilateral zygoma with titanium mini plates. The titanium mesh is fixed to the fibula and the residual bony buttress to reconstruct the anterior wall of the maxilla and the orbital floor in the patients with class 3 defects, besides bone reconstruction with the fibula. The skin paddle is to restore the palate. For the patients with extensive soft tissue defects, the free radial forearm flap is combined to restore soft tissue defects. Implant-borne prostheses or removal partial dentures are performed immediately or delayedly. The postoperative evaluation of the function included speech and masticatory function. Assessment of occlusal force was proceeded by T-scan Ⅱ system (Tekscan company, USA). Speech intelligibility test and the computerized acoustic analysis of [a],[i],[e],[u] were conducted to evaluate the postoperative articulatory function. The results of postoperative functional evaluation were well.

Key words: Mandibular reconstruction; Maxillary reconstruction; CAD/CAM technique.

11

Implants for Pediatric Patients: Growth and Implant Placement

Arun Sharma

University of California, San Francisco, USA

Patients with ectodermal dysplasia and alveolar clefts have been a part of clinical research and patient management at UCSF since 1992. Long term follow-up and clinical experience has allowed UCSF to

establish a protocol for the use of osseointegration in children. We are often asked the question, "What is the appropriate time to use implants in children"? While there is no single appropriate answer, we evaluate the pediatric patient and plan treatment in three separate categories: Group I: For the growing child who is missing a single tooth with adjacent natural teeth, implants should not be placed until dento-alveolar development is complete. Group II: For the completely edentulous growing child, implants can be planned as early as 7 years of age. Although surgery may be necessary when growth is complete to correct the jaw size discrepancy. The prostheses may have to be remade and Group III: For the partially edentulous growing child the decision as to when to place implants is more complex, and is dictated by the extent of the edentulous space and its proximity to natural permanent teeth. Our treatment approach is to first make conventional removable prosthesis after orthodontic treatment is complete. If this provides a satisfactory result, we will wait for growth to be completed before implant placement. If the conventional treatment is unsatisfactory, implants can be placed, but the need for surgery and/or remake of the prostheses must be anticipated at the end of growth.

12

Recent Advances in Craniomaxillofacial Tissue Engineering

Ben Wu

University of California, Los Angeles

Cancer, trauma, and congenital defects can produce tissue deficits in the craniomaxillofacial complex t hat are associated with severe esthetic deformity, discomfort, and functional impairment. In particular, tumors that require high dose chemoradiation and extensive resection often leave behind tissues that ha ve limited vascularity, significant scarring, and poor healing capacity. While the use of vascularized fr ee flaps can improved graft survival in these suboptimal healing environments, strategies to minimize ti ssue damage are highly desirable to maximize the remaining quality of life. This talk will highlight rec ent bioengineering advances that may be useful in the preservation of critical tissues surrounding unres ectable tumors. This talk will also summarize some of the exciting innovations in reconstructive biote chnology that may be used to promote the regeneration of functional anatomical structures in the cranio maxillofacial complex.

13

Effect of Early Stage Dent-maxillary Prosthesis in the Rehabilitation of Maxillectomy Patients

Takahiro Ono

Osaka University Graduate School of Dentistry

Purpose: Aesthetic and functional rehabilitation for maxillectomy patients should be started as soon as possible. In our department, Early Stage Dent-maxillary Prosthesis (ESDP) has been delivered to post-surgical maxillectomy patients for this purpose. ESDP is fabricated on the pre-surgical working model, so it duplicates the dentition and alveolar contour on the prosthesis. In my lecture, procedure to fabricate ESDP and its effect in the rehabilitation will be presented. ESDP improves masticatory ability as well as speech intelligibility at the similar level with definitive obturator. Questionnaire assessment of quality of life (QOL) by using EORTC QLQ-H&N35 revealed that patients with ESDP showed higher QOL in the items such as [speech]，[social eating]，[social contact]，[problems with teeth] than patients with delayed surgical obturator. ESDP can be recommended as an effective treatment for maxillectomy patients.

Key words: Dent-maxillary prosthesis; Maxillectomy; Rehabilitation; Quality of life.

14

Microbial Adhesion to Maxillary Obturator Prostheses

Karl Lyons

University of Otago, New Zealand

Restoration of maxillary defects resulting from resection of palate and/or naso-sinus neoplasms is commonly achieved using obturator prostheses, however obturators may be colonised by microorganisms and function as a reservoir for infection of the oral and nasal soft tissues. Such patients commonly also require radiotherapy that can result in changes in oral flora. These changes in immunocompromised individuals increase the risk of prosthesis-related infections. This presentation will present the results of a study that investigated microbial adhesion to, and colonisation of, maxillary obturator materials. The investigation involved clinical and laboratory components. Clinically, microbial colonisation of obturator prostheses and adjacent tissues was investigated in patients referred for restoration of maxillary defects. This was undertaken at various stages of prosthodontic treatment and microbial identification was carried out from samples obtained at these appointments.

Clinically, obturator prostheses and adjacent tissues in all patients investigated were colonised by Candida, with Candida albicans identified in more than 90% of patients, at all stages of treatment. Microbial colonisation increased with the age of the prosthesis with the number of microorganisms only reducing following a reline or delivery of a new prosthesis. For patients receiving radiotherapy, a high level of C. albicans colonisation (>10^5colony forming units per swab) of obturators after 1-week of oral radiotherapy was found to predict patient susceptibility to increased complications during radiotherapy. In the laboratory, Candida, and most commonly, C. albicans was identified from obturator swabs. Using adhesion studies, C. albicans was found to attach to nine different materials from which obturators can be made, and attachment was greater to materials with a greater surface roughness and surface energy. Saliva increased adhesion of C. albicans. Using mass spectrometry, the protein SPLUNC2 was shown, for the first time, to be associated with Candida adhesion to acrylic and may provide receptors for C. albicans adhesion to obturator materials.

15

Head and Neck Cancer Therapy. Oral Complications and Potential Management Techniques.

Eric Sung

School of Dentistry, UCLA

Abstract: Head and neck cancers account for approximately 3 percent of all cancers in the United States. Treatment of this cancer often involves radiation therapy, and increasingly, chemotherapy. We will review some of the complications associated with this therapy and potential management techniques to improve the tolerance by the patient. We will also review the theory on the pathogenesis of ORN and some of the treatment modalities that are currently employed.

16

Development and Progress of Craniomaxillofacial Reconstruction

Cai Zhigang, Shan Xiaofeng, Huang Jinwei, Lian Jie, Zhang Jie, Zhang Jianguo, Zhao Fuyun, Zhang Yi, Mao Chi, Peng Xin, Zhang Lei, Wang Yang, Guo Chuanbin, Yu Guangyan

Dept. Oral & Maxillofacial Surgery, Peking University School & Hospital of Stomatology，Beijing, China

Purpose: The craniomaxillofacial tissue defects caused by head neck ablative surgery, osteomyelitis or severe trauma would physiologically and psychologically affect patients' life quality. However, the complexity of this regional anatomy makes it a great challenge for plastic surgeons to reconstruct the facial contour and rehabilitate the occlusal function. With the development of microsurgery, dental implant, distract osteogenesis and digital surgery, the craniomaxillofacial reconstruction achieved progress rapidly in the last decades. Nowadays, the optional approaches for craniomaxillofacial reconstruction include reconstruction titanium plate, nonvascularized bone grafts, vascularized osteocutaneous flaps and distraction osteogenesis etc. Improvement in microsurgical techniques refinement of titanium fixation systems, and development of digital surgery techniques have revolutionized the reconstruction of this area. Functional and aesthetic rehabilitation of the patients have become a basic goal for clinicians.

Methods: We will introduce some clinical works in our department (Dept. Oral & Maxillofacial Surgery, Peking University School & Hospital of Stomatology) as following: 1. Reconstruction of soft tissue defects after head neck ablative surgery. Some vascular free flaps and regional flaps was introduced, including classification of defects, indications, advantages and disadvantages of different reconstructive methods were retrospective analyzed. 2. Reconstruction of jaws. For the mandibular reconstruction to introduce the clinical indications of 4 kinds of method for mandibular restore and reconstruction, and to discuss the option in midface and maxillary reconstruction according to Brown's classification.

Results: With the help of computer assisted surgery technique, patients got much better function and appearance.

Conclusion: It's believed that the individual and functional facial contour reconstruction is to be achieved precisely with the help of computer assisted surgery techniques in the future.

Key words: Craniomaxillofacial reconstruction; Free flap; Regional flap; Reconstruction of jaws; Digital surgery.

17

Direct 3D Printing of Silicone

Swati Jindal

King's College London, UK

Purpose: Traditionally maxillofacial prostheses are fabricated by hand carving the missing anatomical defect in wax, and creating a mould into which pigmented silicone elastomer is placed. Modern technologies have been used to manufacture anatomical face/body parts utilizing computed tomography (CT) data in conjunction with rapid prototyping (RP) techniques utilizing a hard plastic resin or thermoformed wax. However, these methods still require moulds into which a biocompatible pigmented silicone elastomer is placed. The purpose of this paper is to describe the development of direct printing of two component silicone elastomers suitable for creating facial/body prostheses.

Methods: There are two areas in developing this technology that are intrinsically linked. Firstly, a custom designed 3D printer with x- y-z gantry robot with an accuracy of 0.1μm was adapted with a custom designed printing head. Secondly, a two component silicone elastomer suitable for RP that incorporates the desired characteristics and properties similar to those commercially available for the

provision of facial and body prostheses was developed. The silicone is composed of polydimethylsiloxane (PDMS) chains, filler, catalyst and cross-linker. Varying the amount of these components the mechanical properties of the silicone elastomer can be altered e.g. tensile strength, tear strength, hardness and wettability. To achieve these desired properties consideration must also be given to the set time and viscosity of the silicone elastomer and additionally the speed at which the material is printed.

Results: A biocompatible pigmented silicone with properties similar to currently used elastomers has been developed and printed. The hardness can be varied between 10-26 Shore A while the tensile strength ranges from 1.1 to 3.3 kN/m. The colour and hardness of 3D printed silicone can be varied through the print process to suit the final application.

Conclusion: This technology has the potential to manufacture complex facial/body prostheses of similar characteristics to that of current silicone elastomers used in the traditional way. Further research is needed to ensure appropriate digital colouring of the silicone elastomer to match the patients' natural tissues. Ultimately, this would provide the maxillofacial prosthetist with a tool that manufactures prostheses reliably, with less emphasis placed on individual artistic interpretation.

Key words: 3D Printing; Two component silicone.

18

Rehabilitation of Maxillectomy Defects with CAD-RP Obturator Prostheses: A Pilot Study

Jiao Ting, Dong Xian, Zhu Chenyuan

Shanghai JiaoTong University, Shanghai 9 th People's Hospital

Purpose: Obturator prosthesis is an effective treatment to rehabilitate the maxillary defect for patients with maxillary defect. In this study a new method is established to design and fabricate an obturator prosthesis by computer aided design (CAD) and rapid prototyping (RP) technique and evaluate the functional results of this technique.

Methods: Eleven patients with acquired maxillary defects because of head neck cancer were treated under a protocol based on 3-D reconstruction, CAD, and RP technologies to fabricate obturator prostheses. To evaluate the quality of the obturator prostheses and patients' satisfaction, the Obturator Functioning Scale (OFS) of the Memorial Sloan-Kettering Cancer Centre was applied.

Results: Each patient got an individualized obturator, which could exactly represent the defective shape and fit the defect. The obturator could easily fit the defect with little modification and was suitably placed in the patient's defective cavity without shifting or swinging. The patients showed good results in all fields of functional outcomes and social acceptance. The OFS were comparable with the other studies using traditional methods.

Conclusion: This study combined CAD with RP technology, exploring a new and feasible method for making individualized obturators for the patients after maxillary resection. The new method has significant clinical value in that it helps to decrease chair side time needed for both the patients and prosthodontists and the difficulties in operation and suffering on the part of the patients.

Key words: 3D reconstruction; CAD/CAM; Rapid prototyping; Maxillary defect; Obturator prostheses; Rehabilitation for head neck cancer.

19

Digital Clinical Solution of Presurgical Nasoalveolar Molding (PNAM) for Infant Clefts in FMMU

Wu Guofeng, Feng Xinhua, Zhao Yinmin

Fourth Military Medical University, School of Stomatology, China

Purpose: The aim of this study was to establish a multi-digital approach using latest three-dimensional scanning, reversed engineering and rapid prototyping techniques for PNAM treatments of infant clefts. A 3D database for infants' clefts will be built to survey the growth rules of palatal clefts, which will direct the design of PNAM digital solution.

Methods: 160 newborn cleft babies within 1 week old with clefts were investigated in this study and scanned weekly for their facial digital impressions by a new optical scanner until lip repairs. Meanwhile, plaster models of infants' palate clefts were also prepared for the scanning to fabricate the digital palatal models. All the above original data were collected to build a 3D database of infant clefts, and then carefully compared and documented under a reversed engineering software condition to observe the laws of development. Three dimensional virtual and rapid prototyping approaches were applied to realize the individual design and rapid auto-manufacture for the appliances of infant's preoperative nasal-alveolar molding. With the new chromatosis technique and special silicone material of Maxillofacial Prosthetics the simulational face of infant lip cleft were fabricated, which was used for the simulation surgery and surgical teaching.

Results: The detailed three-dimensional information of infant nasal-lip and palate clefts from 1 week old to 12 weeks old were successfully acquired, which were part of the 3D database of infants clefts. According to each patient's condition, the individual preoperative nasal-alveolar molding programs were generated and computer fabricated the series alliances directly. The simulatioanl facial model of lip cleft was designed and prepared for simulation surgery and teaching. The above pictures show the detailed results of this research. The following pictures show the clinical result of the digital PNAM clinical solution.

Conclusion: New advanced techniques of industry showed their great values and will reveal more interests for the clefts researchers. The digital solution in this research will help the physicians to treat infants' clefts with facility.

20

Combined Prosthodontic and Surgical Management of Patients with Amelogenesis Imperfecta: Case Series of Two Patients

Ben Omondi

University of Nairobi

Purpose: To demonstrate the benefit of muldisciplinary collaboration in the management of adult patients presenting with amelogenesis imperfect (AI) but lacking restorative space.

Methods: Impressions were taken using irreversible hydrocolloid (BluePrintR) and poured in Type III gypsum to generate study casts. Using a face-bow record, these were mounted in a semi-adjustable articulator (Dentatus ARH). Reference points were made on the casts after careful evaluation by the prosthodontic and surgical teams. Mock astsurger was rehearsed on one half of the casts but sparing the palatal/lingual. Base plate wax was adapted on the reduced casts to assess for adequate room for denture teeth but maintaining the occlusal vertical dimensions.

New set of impressions were taken using irreversible hydrocolloid in custom trays and poured in type III gypsum to generate working casts. The aforementioned procedure was repeated and selected complete denture teeth set. The patients approved of the set up before processing and finishing. Surgical phase was undertaken under general anaesthesia and the dentures fitted intra operatively. Tissue conditioner (Coe Comfort) was applied to the dentures on the third day post operatively and

changed every one week for a month. Thereafter, monthly follow ups for 6 months.

Results: The patients reported satisfaction with the outcome as far as their appearance, ability to masticate and enhanced self-esteem. Both have since been married and now have babies.

Conclusion: Despite providing a removable option, satisfactory outcome can be possible with a combined prosthodontic and surgical approach for adult patient with AI but with no prosthetic space.

Key words: Prosthodontic; Surgical; AmelogenesisImperfecta

21

Preoperative Percutaneous Nerve Mapping of the Mandibular Marginal Branch of the Facial Nerve

Lin Bo, Lu Xuguang, Shan Xiaofeng, Zhang Lei, Cai Zhigang

Department of Oral & Maxillofacial Surgery Peking University School of Stomatology

Purpose: In this study, we introduce a reliable method for mapping the location of the mandibular marginal branch of the facial nerve. The utility of preoperative percutaneous mandibular marginal branch mapping and continuous intraoperative nerve monitoring during operation with a submandibular approach are reported.

Methods: The mapping technique was performed in 30 cases. Electromyography surface electrodes were placed on the orbicularis oris muscles and the ground electrode on the forearm. A modified bipolar probe with an adjustable distance between the two tips was used to apply surface stimulation at a frequency of 1 Hz to 2 Hz. The stimulating current most frequently used was 5.0 mA to 5.5 mA. By moving the electrode at right angles across the suspected path of the nerve around the marginal border of the mandible, a point is reached where the orbicularis oris contracted and a clear compound muscle action potential was evoked. Four to five dots were marked and connected to show the complete nerve course. During the surgery, an intraoperative nerve-monitoring technique was used for positive confirmation after the nerve had been visually identified.

Results: Satisfactory mapping was achieved in all cases. A positive correlation between the nerve mapping and operative identification was found. The distance between the nerve branch and the mandibular marginal border at the point of the facial artery ranged from –28 mm to +5 mm. The nerve branch was sacrificed in one case because of oncological reasons.

Conclusion: We found that preoperative percutaneous nerve mapping was a successful method of identifying the location of the facial nerve and could protect the nerve from injury.

Key words: Facial nerve mapping; Mandibular marginal branch; Percutaneous

22

Digital Technology Used in Rehabilitation of Maxillofacial Defects

Gu Xiaoyu, Zhang Fuqiang

9th People's Hospital, Jiaotong University, Shanghai

Purpose: To explore a course for digital maxillofacial prostheses system, improve the clinical treatment for maxillofacial defects on patients.

Methods: The patients with maxillofacial defects were scanned by means of structured light projection and computer tomography (CT). The 3D models were then reconstructed and global registration was made to merge the acquired models into a new digital model for designing. The 3D design of the prosthesis was implemented in a 3D software of reverse engineering. "Double mirror technology" and

the "anatomic" prostheses designing were proposed during the course of the study and a complete 3D design process was set up. Then the concept and technique of designing female molds were built to make the silicone prosthesis indirectly. The parts of female molds were designed according to the 3D data of the prosthesis, and rapid prototyping (3D printing) technology was then used to machine the resin molds on the basis of the digital graphics. Finally, silicone for prostheses were filled and cured in the resin molds to make the clinical restorations for the patients.

Results: 10 patients with varying degrees of maxillofacial defects were rehabilitated by the system explored in the study, including three patients with nasal defects, two with orbital defects, one with auricle defects, four with cheek defects as well as a patient with defect on his maxilla. All patients suffered no pain or discomfort during the treatment; they were satisfied with the final prosthesis of the adaptation, shape, color, retention, stability, etc.

Conclusion: The digital maxillofacial prostheses system explored in this study provided a new way for the treatment of the patients with maxillofacial defects in clinic, which showed superior effects to traditional treatment manners for these kinds of patients.

Key words: Prostheses; 3D design; Female molds; Rapid prototyping.

23

Development of the Combined Finite-element and Rigid-body Analysis Model for the Maxillofacial Prosthodontics

Ho Beom Kwon, Young Jun Lim, SugJoonAhn, Ling Tsou, Antonio Sanchez, Sidney Fels, John

Seoul National University

Purpose: The purpose of the study was to construct three-dimensional computer models composed of finite-elements and rigid-bodies for the analysis of the maxillofacial prosthodontics and to simulate functional movements of the musculoskeletal system of head and neck area for the analysis of the function of the maxillofacial prosthesis.

Methods: Three-dimensional computational models of head and neck area were developed to simulate functional movements of the stomatognathic system. The sectioned images from the dataset of Visible Korean Human Project and the Computed Tomography data of the healthy subjects were used for the construction of computational model. The photographed sectioned images of the Visible Korean dataset and the raw image data of the Computed Tomography were processed using segmentation software. Final segmented data were imported into ArtiSynth (The University of British Columbia, Vancouver, Canada), a three-dimensional biomechanical modeling platform. In Artisynth the model was consisted of cranium, mandible, hyoid bone, masticatory muscles, infrahyoid muscles, tongue, soft palate, and pharynx. Bones were regarded as rigid bodies and soft tissues were made of finite element materials. Finite-element muscle actuators were created to move the models. Using sectioned images imported in segmentation program, the directions of muscles were defined and transferred to Artisynth. Data on muscle activations and material properties of the structures from the previous studies were used. Functional movements including mandibular opening and closing movement and normal velopharyngeal closure were performed by muscle activations. Kinematic analysis and dynamic analysis of the models were done.

Results: A combined computer models of rigid body and finite element were created. It was demonstrated that the mandibular movement could be controlled by the activation of the muscle actuators. The simulation of the functional movements of the structures including mandibular opening and closing movements and the velopharyngeal closure were possible.

Conclusion: Three-dimensional computer simulation is suggested to be a useful methods to study the biomechanics in maxillofacial prosthodontics.

Key words: Finite element; Computer simulation; Rigid body; Maxillofacial prosthodontics Lloyd

24

The Evaluation of Measurement Accuracy of Two Different 3D Face-scanner on Healthy Human Faces

Ye Hongqiang, Lv Longwei, Liu Xiaojing, Zhao Yijiao, Zhou Yongsheng

Dept. of Prosthodontics, Peking University School of Stomatology

Purpose: To compare the accuracy, reliability and reproducibility among the structured light scanning system, stereophotogrammetry system, and caliper measurement on scanning the healthy human faces.

Methods: 10 healthy volunteers were selected for this study. After marking of the facial anatomy points, the faces of volunteers were scanned by the structured light scanning system and stereophotogrammetry system, and the 3D images data were reconstructed with corresponding software. For each subject, the scanning progresses were performed twice after calibration. The linear distances were measured and compared on the faces using caliper, the images from structured light system and the images from stereophotogrammetry system. Absolute errors (AE), absolute percentage errors (APE) and intraclass correlation coefficients (ICC) were chose as index to evaluate the accuracy, reliability and reproducibility of the two different 3D scanning systems.

Results: There was no statistical difference among results acquired by three estimation methods (P value: 0.891 to 0.999). Both of the scanning system presented high accuracy (AE 0.58±0.37mm and APE 1.11±0.73% for the structured light scanning system; AE 0.62±0.39mm and APE 1.17±0.71% for the stereophotogrammetry system). The two scanning systems also showed extremely high reliability compared to caliper measurement (ICC value: 0.982 to 0.998 for the structured light scanning system; 0.984 to 0.999 for the stereophotogrammetry system). And high reproducibility was also presented by the two scanning systems (ICC value: 0.981 to 0.999 for the structured light scanning system; 0.984 to 1.000 for the stereophotogrammetry system).

Conclusion: When applied in scanning and measuring of healthy human faces, the structured light scanning system and stereophotogrammetry scanning system both present high accuracy, reliability and reproducibility.

Key words: 3-dimensional scanning; Structured light; Stereophotogrammetry; Healthy human faces.

25

Application of Computer Aided Technique in the Rehabilitation of Complicate Oral-Maxillofacial Defect and Deform

Bai Shizhu, Wu Qin, Liu Yanpu, Zhao Yimin

School of Stomatology, the Fourth Military Medical University

Purpose: Patients with maxillaryor mandibular defects need surgical reconstruction and further prosthodontics rehabilitation for satisfactory aesthetic and functional outcome. There have always been some patients who had surgical bone reconstruction in improper position, and have troubles or even fail to complete prosthodontic rehabilitation. The prosthodontists have always wished to gain closer collaborations with surgeons and confront these complicated challenges together; if every reconstructed bone could achieve its ideal position from surgical reconstruction, every patient would satisfy with his final denture in cosmetic and function.

Methods: Preoperative virtual planning, computer aided design, a bridge between prosthodontics and surgical reconstruction, makes it possible to overcome this thorny problem. Now we design and fabricate template prosthesis for the patient preoperatively, and integrate the data of the prosthesis to the patient's 3D skull model by CT scanning. Discussion will be made with surgeons to determine the final treatment plan by the help of the software, according to the actual condition of the defect and the prosthesis. Then surgery guide templates will be designed and manufactured by rapid prototyping technique, and thus accurately convert the pre-surgery design into actual surgery procedure.

Results: All the treatment procedures and outcomes by far have proved that, with the method

mentioned above, close and effective preoperative communications and collaborations between prosthodontists and surgeons could be made to determine the optimal treatment plan, and thus achieve the prosthesis-guided surgery reconstruction. In this way patients could get shorter treatment cycle, more-reliable outcome, and better treatment quality. Meanwhile, with the help of the surgical templates, the operation procedure becomes easier, time shorter, and the trauma made to the patient can be greatly reduced.

Conclusion: Through our dedicated efforts, this method is being improved and used more and more. Hopefully it will become one of the routine therapy techniques of our hospital.

Key words: Computer aided design; Oral-maxillofacial defect; rehabilitation.

26

A Case of Fixed Prosthesis with Autologous Ilium Bone Free Graft Auxiliary GBR to Restore Severe Defects of Maxillary

Yang Sefei

Department of Stomatology, Chinese PLA General Hospital

Purpose: To report a case of fixed prosthesis with autologous ilium bone free graft auxiliary GBR to restore severe defects of maxillary.

Method: Basic situation: patient, masculinity, 67 years old, Clinical time: 2013-2. Severe defect of maxillary including the area of 16 to 21 on account of car accident 15 years ago, the height of alveolar crest to vestibular groove less than 5mm, CBCT show that the width of buccolingual is 0.3-1.6mm and the horizontal defect is to 1/3 of root apex in defects of bone area. The range of opening mouth is 3.5cm. The patient required strongly to restore the defect by fixed prosthesis which supported by implant.

Results: Treatment plant : 1.Take the left autologous ilium to free graft to the area of defect of maxillary ; 2. Take Double deck membrane technology with bone meal locally to obtain ample bone increment amount ; 3. The area of 16、15、14、21 placed one-stage implant; 4. Restore the lost natural dentition by fixed prosthesis.

Conclusion: Treatment effect: 1. After operation of autologous ilium bone free graft with titanium mesh and collagen membrane, the width and height of the alveolar was increased, but the increase of the width was more obvious. The healing of the side of ilium was bad, with pit shape defects witch diameter was about 4mm; 2. When placed the implant, there had enough bone mass to sport after 5 month, could place the implant with conventional diameter and length according to ideal angle and direction; 3. Make the fixed bridge only need a bit of false gingiva after two-stage operation , which not only artistic but also can restore the function of mastication when put it into the patient oral.

27

Immediate Implant-retained Prosthesis Following Radicalmaxillectomy

Liao Guiqing

Guanghuaschool of stomntology, Hospital of stomntology, Sun Yat-sen University

Purpose: The maxillary defect after tumor resection typically involves the mucosal defect and the mid-face osseous framework damaged. Reconstruction of this defect remains a considerable challenge because the 3-dimentional architecture of midface serves both function and aesthetic role. This article describes the maxillofacial rehabilitation of a patient diagnosed with recurrence ameloblastoma.

Methods: The surgery consisted of a large amount of maxillary bone and soft tissue resection. During

the surgical healing, zygoma and nasal implants were inserted in a two-step procedure. The immediate maxillary prostheses were installed and fixed by a titanium framework. With the bone and soft tissue remodeling, the immediate maxillary prostheses were replaced by a new one at post-operation 3 months. 6 months after operation, the second stage of implant procedures were carried out. The ultimately maxillary prostheses were fixed by the titanium framework.

Results: After 2 years follow-up, no recurrences were observed. The patient has a good result in aesthetic, functional, stability, and did not complaint any discomfort. Tissues around implants were in good health, and the prostheses remained well-fitted. The patient was extremely satisfied with the final result.

Conclusion: The immediate implant-retained prostheses are well accepted by the patient, improving comfort and safety during function while recovering her esthetic appearance

Key words: Immediate; Implant-retained; Prostheses; Maxillary defect.

28

Effects of Titanium-nanotubes Surface Modified by Estrogen-loaded Solid Lipid Nano-particles: An Invitro Study

Gao Yan, Liu Ying, Zhou Lei, Xu Shulan, Zhao Yadong, Deng Yue, Du Bing

Center of Oral Implantology, Guangdong Provincial Stomatological Hospital, Southern Medical University

Purpose: Challenges exist in improving early osseointegration. The present article was to investigate the effect of local delivery system of estrogen-loaded solid lipid nano-particles (SLN) on titanium-nanotubes (TNT) surface

Methods: Estrogen-loaded SLN were prepared by multiple emulsion-solvent diffusion technique, TNT surfaces fabricated by anodic oxidation was then modified by this local delivery system. An in vitro release experiment was conducted to evaluate the sustained release of estrogen. The particle size and morphology of estrogen-loaded SLN were measured by laser particle size analyzer and transmission electron microscope respectively. The osteoblast-like MG-63 cells were used in present study, cell attachment, spread, proliferation, ALP activity and mineralization assay were performed to assess the early cell response

Results: Estrogen-loaded SLN (60 nm in diameter) were loaded on TNT (80-100 nm in diameter and 500nm in length) surfaces. This delivery system can be achieved a sustained release of estrogen up to 120 h and has a better sustained release effect than the TNT surfaces alone. Estrogen-loaded SLN TNT surfaces accelerated the attachment of MG-63 cells, nearly twice higher than the control group. Spread and cytoskeletal development of cells on the TNT surfaces modified by estrogen-loaded SLN appeared to be greater than the TNT surfaces. Enhanced cell proliferation and differentiation happened on the estrogen-loaded SLN TNT surfaces. At days 14 and 21 of culture, the area of mineralized nodule assayed by alizarin red staining was also greater on the estrogen-loaded SLN TNT surfaces, exhibiting an increase of 80% at day 14 especially.

Conclusion: TNT surfaces modified by estrogen-loaded SLN enhanced the cellular early osteogenic capability, suggesting this delivery system not only enabling more rapid establishment of osseointegration at interface of titanium and bone, but also as a drug delivery systems to treat osteoporosis

Key words: Solid lipid nano-particles; Titanium; Delivery system; Osseointegration.

29

The Use of Zygomaticus Implants in the Compromised Patient: Review and Patient Report

Jay Jayanetti

LSU School of Dentistry, Department of Prosthodontics

Purpose: The zygomaticus implant was designed to allow for implant restoration of the extremely atrophied maxilla, while circumventing the need for bone augmentation procedures, the most popular of which is the external sinus lift. Other bone augmentation procedures include onlay block grafts, and Le Fort osteotomy with interposed bone graft.

Methods： Grafting procedures may require donor site surgery and increased treatment time. The usage of the zygomaticus implant has been expanded to the rehabilitation of near total and total maxillectomy patient. Implant success in such patients are reduced on account of postresection radiotherapy.

Results： In our literature search, the use of zygomaticus implants in the unrepaired cleft palate patient has yet to be reported. Zygomaticus implants were used to rehabilitated the cleft palate patient by supporting an obturator by means of the bar and clip concept.

Conclusion： In the two reported cases; Esthetics and masticatory functions were restored nasal regurgitation corrected; And speech intelligibility improved.

30

Implant-Supported Intraoral Prostheses Retained by Bar-Clip Attachment Following Distraction Osteogenesis after Block Resection of Mandible in A Case of Squamous Cell Carcinoma of the Floor of the Mouth

Tang Chunbo

Stomatological Hospital of Nanjing Medical University

Purpose: To report a 56 years old male patient with distraction osteogenesisafter mandible block resection because of squamous cell carcinoma of the floor of the mouth and to evaluate the functional and esthetic outcome after rehabilitation with implant-supported intraoral prostheses retained by bar-clip attachment.

Methods: A dentition defect patient diagnosed with squamous cell carcinoma of the floor of the mouth previously treated with mandible block resection and distraction osteogenesis. The treatment consisted of a large amount of anterior mandible resection, so distraction osteogenesis was carried out before implant surgery. After 14-day distraction osteogenesis and kept the distractor for 8-month, four Nobel Replace implants were inserted in the spots of left middle incisor, left canine, right lateral incisor and right first premolar. Four months later, the implant-supported intraoral prostheses retained by bar-clip attachment were installed after custom impression.

Results: There was enough bone for implants after distraction osteogenesis and the prostheses remained well-fitted. The implant-supported prostheses retained by bar-clip attachment had excellent stability and retention which improved the quality of life, and the patient was satisfied with the final result.

Conclusion: Maxillofacial defect requires special care in rehabilitation. The use of distraction osteogenesis and bar-clip implant-retained prostheses obtains excellent functional and esthetic results. The implant-retained prostheses are well accepted by the patient, improving safety and comfort during function while recovering his esthetic appearance.

Key words: Maxillofacial Rehabilitation; Implant; Custom Impression; Bar Clip Retention; Squamous Cell Carcinoma of the floor of the mouth.

31

Fabrication of Surgical Templates for Orbital Implant Placements and Orbital Rehabilitation

Chen Songling

The First Affiliated Hospital of Sun Yat-sen University, Guangzhou.

Purpose: Implant placement in orbital sites is challenging because of limited bone volume and poor bone quality.

Preoperative optimal implant planning and intraoperative guides are important to ensure success. This article describes the use of computer simulation for implant insertion and fabrication of a surgical template as a drilling guide for orbital implant placement

Methods: 7 patients with a right orbital defect underwent computerized tomographic scanning, and the data were processed with interactive software to simulate orbital implant placement. A surgical template that served as a drilling guide was designed and fabricated to transfer orbital recipient site information from the three-dimensional computer model into the actual orbital implant sites.

Results: The craniofacial implants were placed in the predictable positions. No unexpected complications or injuries were encountered during the surgery. Magnetic abutments were attached to the implants 2 weeks later. The definitive facial prosthesis was fitted 6 months later, with excellent esthetic results.

Conclusion: The computer-designed surgical template contributed to the success of these treatments.

Key words: Key words: computer-aided design; Computer-assisted manufacture; Craniofacial implant; Orbital; Defect; Surgical template.

32

ALT Flap in the Reconstruction of Defects in Head and Neck Region

Wei Jianhua, Cheng Xiaobing, Lei Delin

State Key Laboratory of Military Stomatology, Department of Oral and Maxillofacial Surgery, School of Stomatology, the Fourth Military Medical University, Xi'an 710032, China

Purpose: The purpose of this study was to explore the clinical application and therapeutic efficacy of head and neck defects reconstructed with anterolateral thigh (ALT) flaps after ablative cancer surgery.

Methods: From May 2013 to May 2014, 33 patients with varied head and neck defects resulting from resection of malignant tumor underwent reconstruction with the ALT flap at our center. The surgical anatomy, flap design, as well as flap raising technique are described, and the outcome is reported.

Results: 13 flaps were myocutaneous flaps, others are fasciocutaneous flaps. According to the defects needs, ALT flaps were tailored as thinned flap, fasciocutaneous flap, myocutaneous flap, splitted flaps in through and through defects or combined with AMT flap in very large defect. Two patient with venous thrombotic events required operative exploration. All 33 flaps were successful based on a 1 to 3 perforator for reconstruction of defects. In 32 cases, the donor site was closed primarily for the ALT flap, leaving only a linear scar, and the thigh had no functional deficit.

Conclusion: The free ALT flap has good pliability and bulky volume. It can be tailored easily to adapt the defects in head and neck defects. This flap presents high successful rate, good functional results at the recipient site with the additional advantages of minimal donor-site morbidity, and a high level of patient satisfaction.

33

35 Years with Osseointegrated Facial Prostheses – History & Developments

Kerstin Bergstrom

Department of Otolaryngology Sahlgrenska University Hospital

Purpose: Bone-Anchored prosthetics have advanced the rehabilitation of patients with defects from cancer therapy, malformation or trauma. 1979 the first patient was provided with an auricular osseointegrated craniofacial prosthesis in Gothenburg, Sweden.

During 35 years the technique has developed and new possibilities for reconstruction have opened. 1983 the first child got osseointegrated fixtures for an auricular prosthesis.

Methods: 31 years follow up and what happens when children grows up will be presented. Every day life, phsycological and functional aspects will be discussed.

Teamwork and treatment planning is important for the final functional and aesthetic outcome of the restoration. Computer - aided surgical and prosthetic planning has further increased the possibility of optimizing the results.

Results: Rehabilitation of patients with combined extraoral and intraoral defects is more difficult and requires even more from the professional treatment team. The use of extra oral skin penetrating implants is regarded as a safe and predictable procedure for anchoring facial prostheses.

Conclusion: Future developments to further improve the rehabilitation and quality of life for our patients is what we are striving for.

34

Preliminary Analysis on Free Flap Re-exploration - Beijing's Experience

Zhang Lei, Wang Yang, Peng Xin, Mao Chi, Zhang Jie, Cai Zhigang

Department of Oral and Maxillofacial Surgery, Peking University School and Hospital of Stomatology, Beijing, 100081, China

Purpose: Microvascular free tissue transfer became the reliable and most popular method to reconstruct the big or complex surgical defects of head and neck region. With the advancement of microsurgery techniques, the success rate of free flap is rising to 90-98%. But there were still a small risk. Microvascular free tissue transfer became the reliable and most popular method to reconstruct the big or complex surgical defects of head and neck region. With the advancement of microsurgery techniques, the success rate of free flap is rising to 90-98%. But there were still a small risk of flap compromise necessitating re-exploration, with a rate from 10.5% to 11.85% mainly owing to vascular thrombosis. If the pedicle thrombosis cannot be detected in time and managed properly, severe complication will happen because of the flap failures. The purpose of this study was to review our experience on the free flap re-exploration based on the free flaps in the past 3 years.

Methods: A retrospective review of all the free flaps performed from 2010 – 2012 in the department of Oral and Maxillofacial Surgery, Peking University School and Hospital of Stomatology. All of the cases which required emergent re-exploration were identified, and the related clinical data on vascular complications and methods used for their management were recorded and analyzed.

Results: A total of 962 free flaps were performed during the study period, of which 75 cases required emergent re-exploration. The re-exploration rate was 7.8%. The most common causes for re-exploration were pedicle thrombosis. Forty-five cases were salvaged successfully and other 30 flaps failed finally, which the successful salvage rate was 60%. The overall flap survival rate was 96.9%. Venous thrombosis was more common than arterial thrombosis (9:1) and had a higher salvage rate (4.5:1). Most of the emergent re-explorations (78.7%) were performed within 48 hours after the

microvascular free tissue transfer, which was called the more dangerous postoperative 48 hours. The delayed vascular thrombosis which happened after 72 hours was difficult to be detected immediately and salvaged successfully. The quicker the vascular thrombosis was detected and managed, the better the free flap reoperation result was. Six hours is critical for the free flap salvation.

Conclusion: Microvascular free tissue transfer is a reliable reconstructive technique with low failure rates. Selection of suitable cases, proper donor vessel and plenty microvascular surgical experience were the basic elements on flap success. Careful monitoring and urgent re-exploration were critical for the salvage of free flaps. The majority of venous thromboses can be salvaged easier than arterial thromboses. The delayed vascular thrombosis was more problematic and difficult to be salvaged.

35

Facial Prostheses Retained on Basally Osseointegrated Implants (BOI)

VojkanLazić, Vitoamir Konstantinović, Igor Djordjević

University of Belgrade, Serbian

Purpose: The use of osseointegrated implants for retaining the maxillofacial prostheses revolutionary improves their stability and thus increases the quality of life of the patients. However, some specifics of maxillofacial implantology could tempt some problems in everyday practice. They are: close anatomical relation to the intracranial structures; less bone quality and quantity; mainly compact bone; irradiated tissue. All of that sometimes limits usage of conventional screw like implants. The goal of this lecture is to present our experiences with facial prostheses retained on basally osseointegrated implants (BOI).

Methods: Two designs of BOI implants are used. Disk implants and bicortical screws (BCS). Specifity of this type of implants is bicortical or multicorticalosseointegration in the basal, resorption free bone. In the last 8,5 years period (follow up 6 months-8,5 - years), 107 BOI implants were inserted for extra and intraoral maxillofacial prostheses anchorage in 38 patients, in nonirradiated (23) as well as in irradiated patients (15). For nasal prosthesis anchorage, 30implants were placed in 12patients. In 17 patients, 42 implants were placed for orbital prosthesis. For intraoral prosthesis, in 9 patients, 36 implants were inserted.

Results: Overall implant survival rate for irradiated patients is 80%. For nonirradiated patients, results are much better (survival rate 98%).

Conclusion: Basally osseointegrated (BOI) implants present an excellent solution for maxillofacial prostheses anchorage, particularly in irradiated patients.

Key words: Basally osseintegrated implants; Facial prostheses.

36

Long-term Result of Reconstruction of Mandible Continuity with Fibula Free Flap and Implant Borne Dental Rehabilitation

Fang Wei, Liu Yanpu, Ma Qin, Zhao Yimin

Department of Implant Dentistry， Department of Oral and Maxillofacial Surgery, Department of Prosthodontics, School of Stomatology, Fourth Military Medical University

Purpose: To evaluate the retrospective outcomes of implant borne dental rehabilitation in patients with mandibular defects reconstructed with fibula free flap (FFF).

Methods: Patients and methods: 74 patients with segmental mandibular defects were enrolled in this cohort study. Defects in these patients were caused by oral neoplasm, trauma and osteoradionecrosis.

They were treated by FFF and dental implant borne prostheses between 1988 and 2010. All patients were available for continuous follow-ups. Clinical and radiographic data was evaluated; Kaplan-Meier survival curve and Poisson Regression analysis were used to evaluate implant survival parameters.

Results: Nine patients (12.1%) developed fibular graft complications postoperatively, three in donor sites, six in recipient sites. 192 implants were inserted. 18 implants failed (9.3%). Overall implant survival in patients was 93.9%, 92.1%, and 86.8% after 5, 10, and 20 years respectively. In 152 implants, probing depth (PD) ranged from 2-3mm. In 31 implants, PD was greater than 5 mm. Of nine implants, PD was greater than 7mm. The highest implant failures were expected for men (OR = 1.10–7.85; p = 0.031), patients received primary FFF reconstruction, (OR = 1.16–11.73; p = 0.027) and for patients who received radiotherapies (OR = 1.40–19.7; p = 0.014)

Conclusion: FFF and implant borne prostheses proved to be reliable approaches for rehabilitation of mandible defects and oral function. The overall postoperative FFF and peri-implant complication rates proved to be low. Regular follow up visits and proper oral hygiene maintenance contributed to the long-term successful treatments.

37

Sub-periosteal Dissection with Denture-Guided Secondary Epithelialization: Case Sereis of A Novel Method for Peri-Implant Tissue Managementin Reconstructed Mandibles

P. C. Jacob, Vinay V. Kumar

Mazumdar Shaw Medical Center, Bangalore, India

Purpose: In patients with mandibles reconstructed using the free fibula flap, management of peri-implant soft tissues is often a clinical problem. This paper intends to present a case series of a new treatment technique, namely ubperiosteal dissection and denture-guided secondary epithelialization (SD-DGSE) as a method of peri-implant soft tissue management in patients with reconstructed mandibles.

Methods: Between July 2011 and July 2013, eleven patients had undergone SD-DGSE procedure to improve soft tissues for implant assisted oral rehabilitation. The procedure consisted of subperiosteal dissection with vestibuloplasty, simultaneous placement of tissue level implants, and immediate loading of the implants with a treatment denture retained on ball abutments. The intaglio surface of the treatment denture was relined at the time of surgery to accomodate the elliptical matrix as well as to conform closely to the tissue surface thereby guiding the formation of soft tissues.

Results: A total of eleven patients (with 32 implants) were treated with this technique. These patients had resection surgeries for benign pathologies reconstructed using a single barrel fibula. Five patients had skin lining (osseomyocutaneous flaps) whereas six patients had primary closure with intraoral mucosa. All patients had presented with increased thickness of soft tissue, insufficient vestibular space and no attached mucosa.

Following SD-DGSE, granulation tissue was seen to fill the fibula in approximately one months time which matures and forms fixed keratinized mucosa in four months time. All patients had stable, fixed and keratinzedperi-implant mucosa with sufficient vestibular space after a period of 6 months.

Conclusion: SD-DGSE is an easy and predictable method of achieving healthy peri-implant tissues in selected patients with reconstructed mandibles. The advantages of this procedure include avoidance of soft tissue grafts, better oral hygiene maintenance and immediate functional rehabilitation. Acknowledgement: This study was partially funded by the International Team for Implantology, Basel.

Key words: Implant supported overdenture; Maxillofacial rehabilitation; Peri-implant soft tissue.

38

Cell Homing Strategy For Bone Tissue Engineering Based on the Cooperative Actions of Simvastatin and SDF-1α-a Potential Application in Maxillofacial Rehabilitation.

Zhou Yongsheng, Liu Yunsong, Ou Mengen

Dept. of Prosthodontics, Peking University School of Stomatology

Purpose: The purpose of this study was to investigate the cooperative effects of simvastatin (SIM) and stromal cell derived factor-1a (SDF-1α) on the osteogenic and migration capabilities of mesenchymal stem cells (MSCs), and construct a seed cell-free bone tissue engineering system comprising SIM, SDF-1α and scaffold which will be promising for application in maxillofacial rehabilitation.

Methods: The effects of simvastatin (SIM) on the proliferation and osteogenic differentiation of mouse bone marrow MSCs were investigated and its effect on the chemotactic capability of SDF-1α was also examined by a transwell cell migration assay. Next, a novel cell-free bone tissue engineering system using PLGA loaded with SIM and SDF-1α was constructed, and applied in critical-sized calvarial defects in mice. New bone formation in the defect was evaluated by micro-CT, HE staining and immunohistochemistry. Then the possible mechanisms under which if SIM and SDF-1α can increase MSCs' migration and homing, promote angiogenesis, and enhance the expression of BMP-2 in newly-formed bone tissue in vivo were also investigated.

Results: We found that 0.2 mM SIM significantly increased alkaline phosphatase activity ($P < 0.05$) of mouse bone marrow MSCs with no inhibition of cell proliferation, and enhanced the chemotactic capability of SDF-1α($P < 0.05$). Next, we constructed a novel cell-free bone tissue engineering system using PLGA loaded with SIM and SDF-1α, and applied it in critical-sized calvarial defects in mice. New bone formation in the defect was evaluated by micro-CT, HE staining and immunohistochemistry. The results showed that PLGA loaded with SIM and SDF-1a promoted bone regeneration significantly more than controls. We investigated possible mechanisms, and showed that SDF-1αcombined with SIM increased MSC migration and homing in vivo, promoted angiogenesis and enhanced the expression of BMP-2 in newly-formed bone tissue.

Conclusion: SIM enhances the chemotactic capability of SDF-1a and the cell-free bone tissue engineering system composed of SIM, SDF-1a and scaffold promotes bone regeneration in mouse critical-sized calvarial defects. This tissue engineering construct is promising for future application in maxillofacial rehabilitation.

Key words: Simvastatin; Stromal cell-derived factor 1; Bone tissue engineering; Cell homing; maxillofacial rehabilitation.

39

Human Freeze-dried Dentin Matrix As a Biologically Active Scaffold for Tooth Tissue Engineering

Wang Fang, Wu Guofeng, Zhao Yimin

School of Stomatology, Fourth Military Medical University

Purpose: Dentin is one of the main components of teeth and has been used as an active scaffold to accommodate odontogenic cells. However, although allogenic dentin has a low immunogenicity, its biological molecules are at risk of being damaged during storage and transportation. In this study, we developed a modified freeze drying technique to prepare a freeze-dried dentin matrix (FDDM) that preserves the bioactivity of dentin but minimizes the immune responses of outside cells.

Methods: The mechanical properties of FDDM were determined, including the compression resistance, flexural strength, flexural modulus, and microhardness. Dentin (D) and hydroxyapatite/tricalcium phosphate (HA) samples were used as controls. Similarly, various biological characteristics, including cell morphology, cell proliferation, collagen secretion, and gene and protein expression, were

investigated using various in vitro testing models. To assess the inductive capacity of FDDM *in vivo*, a combination of FDDM and human dental pulp stem cell (DPSC) sheets were subcutaneously implanted in the dorsal pocket of nude mice. At 8 weeks post-implantation, the transplants were removed and histologically studied.

Results: FDDM has mechanical and biological characteristics similar to those of dentin ($P>0.05$). DPSCs cultured on FDDM and dentin demonstrated superior attachment, growth, viability, and collagen secretion ability but decreased mineral capability compared to DPSCs cultured on HA ($P<0.05$). Histological results show that FDDM, which is similar to dentin, supported dentin-pulp-like tissue regeneration *in vivo*, as demonstrated by the related expression of dentin markers, such as DSP and ALP.

Conclusion: These results suggest that FDDM constitutes a novel bioinstructive scaffold for tooth tissue engineering.

Key words: Freeze dried; Tissue engineering; Dentin

40

Comparison of Tissue Engineered Bone Substitutes for Native Bone Augmentation -An in Vivo Study

Vijayalekshmi Manju

Dept of Prosthodontics &Implantology,Amrita School of Dentistry, Amrita Institute of Medical Sciences, India

Purpose: Augmentation of alveolar bone is required for patients with resorbed ridges and for those who have undergone surgical reconstruction with free vascularized flaps. Although autologous bone is the gold standard for augmentation, donor site morbidity and restricted availability generated the need for the development of bone substitutes .The present research done in animal models would ultimately help to clinically utilise tissue engineered bone with good regeneration potential and mechanical strength to augment the native bone. This would prove value in prosthetic rehabilitation using dental implants as well as an economic option for bone augmentation.

The aim of the study is to characterize and compare two tissue engineered hydroxyapatite (HA) based biomaterials with sufficient strength for the native bone augmentation.

Methods: Five New Zealand white rabbits underwent surgery to create a 10x3x3mm trough in femur. Rabbits were selected due to the fast cellular regeneration similar to the regeneration potential of alveolar bone. Synthesis and characterization of hydroxyapatite based composite scaffolds were done.Scaffold A (sc A) - Nanocrystalline hydroxyapatite were synthesized by aqueous precipitation method, mixed with gelatin and PLLA electrospun sheet.Scaffold B (sc B) Layered biphasic calcium phosphate discs (60% Hydroxyapatite and 40% Tricalcium phosphate) with osteogenic-angiogenic interphase.The mesenchymal stem cells were seeded onto HA based composite scaffolds and induced to differentiate into osteogenic lineage by providing osteogenic supplements. Bone height was measured radiographically and regeneration potential was studied histologically from scaffolds of one limb in first and third months. Mechanical strength was evaluated at third month.

Results: The regeneration potential of both Scaffolds A and B was almost similar. However, the complete resorption was noticed in the Scaffold A compared to B as noticed by Computed Tomography. Using the three point bend test there was significantly higher mechanical strength for scA (110-120Mpa) in wet state than sc B (40Mpa).

Conclusion: Tissue engineered bone with gelatin-HA and electrospun PLLA sheet (scaffolds A) showed adequate mechanical properties and better bone regeneration for augmentation of native bone.

Key words: Tissue engineering; Maxilofacial rehabilitation; Bone augmentati.

41

Mechanism of Human Oralfacial Fibro-osseous Disease and in Vivo Mouse Model Development Based on Disease-specific iPSCs

Qin Haiyan, Qu Cunye, Wang Zhongshan, Ji Jun; Li Bei, Sun Guowen , Hu Qingang, Shi Songtao

Stomatological Hospital Affiliated Medical School, Nanjing University

Purpose: This study tries to uncover the mechanism of human oralfacial fibro-osseous disease and develop animal model *in vivo* based on iPSCs derived from patient-specific mesenchymal stem cells.

Methods: Ossifyng fibroma(OF) is taken as an example of oralfacial fibro-osseous disease. Primary mesenchymal stem cells were cultured from surgically resected OF samples, the differentiation, proliferationetc were compared with normal jawbone MSC(JMSC).Global geneprofile of OFMSC and JMSC were compared using microarray and cluster analysis. Elisa and westernblot were performed to verify the result from microarray and ingenuity pathway analysis. iPSCs reprogrammed from OFMSCs were subcutaneously transplanted into immunocompromised mice with hydroxyapatite-tricalcaium phosphate (HA/TCP).

Results: Ossifying fibroma contains mesenchymal stem cells,which exhibited decreased differentiation and elevated proliferation.TGFβ signaling is highly activated in OFMSCs; TGFβ inhibits BMP signaling to reduce bone formation and activates notch signaling to enhance stromal tissue growth; upregulation of TSP1 contributes to activation of TGFβ signaling in OFMSCs. Histonedemethylation JHDM1D-mediated TSP1/ TGFβ/SMAD3 autocrine loop contributes to TGFβactivation.Establishment of TSP1/ TGFβ/SMAD3 autocrine loop converts normal MSCs to OF-like MSCs. iPSCs reprogrammed from OFMSCs subcutaneously transplanted into immunocompromised mice with hydroxyapatite-tricalcaium phosphate(HA/TCP) can mimik OF pheneotype.

Conclusion: Activated TGFβ signaling in ossifying fibroma mesenchymal stem cells contributes to osteogenesis deficiency and elevated proliferation; ossifying fibroma *in vivo* animal model can mimik phenotype.

Key words: Fibro-osseous disease; Pluripotent stem cells; *in vivo* animal model; Ossifying Fibroma.

42

The Effect of a Novel HDAC3-selective Inhibitor on Osteogenic Induction of Human Adipose Derived Stem Cells

Lu Wei, Ji Kun, Sushmita Saha, Aiden Hempshall, Ronald Grigg, Jennifer Kirkham, Jin Yan, Yang Xuebin

Department of Dentistry, The 461 Hospital of PLA, Changchun, Jilin 130021, P. R. China

Purpose: Histone deacetylases (HDAC) are regarded as important defining the epigenetic program during the lineage differentiation of stem cells. A better understanding of this epigenetic mechanism, that governs osteogenic differentiation of human adipose-derived stromal cells (hADSCs), would promote/improve bone tissue engineering research and provide new insights into the modulation of hADSC-based therapy. The aim of this study was to investigate the effect of a novel HDAC3-selective inhibitor (MI192) on hADSC proliferation and osteogenic differentiation in vitro.

Methods: This study investigated the effect of a novel HDAC3-selective inhibitor (MI192) (5-200 uM) on hADSC proliferation and osteogenic differentiation in vitro. Optimization of the best concentration of MI192 and time of pretreatment for osteogenic induction. Osteogenic differentiation of hADSCs was confirmed by alkaline phosphatase (ALP) staining. Investigate the best concentration of MI192 on the effect of hADSC by cell cycle analysis, quantitative assay for alkaline phosphatase specific activity and real time RT-PCR.

Results: The results showed that high concentration (10-200 uM) of MI192 inhibited the proliferation of hADSC which was concentration dependent. However, after pretreatment with MI192 for 1-4 days,

the alkaline phosphatase positive cells were increased in the osteogenic culture group compare to negative (basal medium) and positive controls (osteogenic medium) without MI192 pretreatment, which indicated MI192 enhanced osteogenic differentiation of hADSCs. This effect was dose dependent. The optimal concentration and pretreatment time of MI192 for hADSC osteogenic induction were 30 μM and two days representively. ALP specific activite was measured using biochemical quantitative assay to confirm that Osteogenic induction of by pretreatment with MI192 (30 μM) for two days significantly enhanced hADSC osteogenic differatiation ($P<0.05$) compare to non-pretreated group. Real-time PCR analysis revealed that MI192 pretreatment upregulated Runx2, Col1, and OCN expression of hADSC under osteogenic induction. In contrast, valproic acid (VPA), a non-selective HDAC inhibitor, did not show any notable effect on osteogenic differentiation on hADSC. DNA flow cytometric analysis indicated that two days pretreatment with MI192（30μM） resulted in G2/M arrest in hADSC. The G2/M arrest was reversible.

Conclusion: Our results suggest that MI192, via inhibiting HDAC, can influence cell cycle to enhance hADSC osteogenic differentiation, and thus could be useful for in vivo bone engineering. This method may have advantages compared to gene therapy and using human recombinated growth factors such as bone morphogenetic proteins.

Key words: Histone deacetylase inhibitor; MI192; Adipose derived stem cells; Osteogenic differentiation; Cell cycle; HDAC-3; Valproic acid.

43

Physicochemical Propertiesand in Vitromineralization of Porous Polymethylmethacrylatecement Loaded with Calcium Phosphate Particles for Bone Reconstruction

Sa Yue, Yang Fang, Sander Leeuwenburgh, Joop Wolke, Ye Guang, Joost R. de Wijn, John A. Jansen, Wang Yining

Department of prosthodontics, Hospital of Stomatology, Wuhan University, PR China

Purpose: To evaluate the effects of calcium phosphate (CaP) particle size and composition on the physicochemical properties and mineralization ability of porous polymethylmethacrylate(PMMA)/CaP cementsin vito.

Methods: Two types of CaP particles of different sizes (1-30 μm and 0.5-1 mm, respectively) were loaded into PMMA cements exhibiting an interconnected porosity created by mixing with carboxymethylcellulose(CMC).

Results: Maximum polymerization temperature internal structure porometricalcharactersand particle distribution of cements was evaluated and the cured cements were subsequently immersed into simulated body fluid to assess their changes of phase composition, mechanical properties and potential bioactivity.

Conclusion: The incorporation of CaP particles did not influence the maximum polymerization temperature of the porous PMMA, but reduced the porosity and the average pore size. Small CaP particles formed agglomerations within the PMMA pores, whereas the big CaP particles were partially embedded in the PMMA matrix and partially exposed to the pores. Both types of CaP particles enhanced the mineralization capacity of PMMA cement without compromising their mechanical properties. Porous PMMA/CaP cement hold strong promise for surgical application in bone reconstruction.

Key words: Porous polymethylmethacrylate; Calcium phosphate; Cement; Bonereconstruction

44

Study on Cnstruction and Biological Effects of Lipopolysaccharide-amine Nano-polymersomes/ Hyaluronic Acid Polyelectrolyte Films on Titanium Surface

Teng Wei, Huang Hongzhang

Department of Prosthodontics．GuanghuaSchoolof Stomatology，Hospital of Stomatology，Sun Yat-SenUniversity &GuangdongProvincialKey Laboratory of Stomatology，Guangzhou，China

Purpose: To evaluate the biological effects of lipopolysaccharide-amine nano-polymersomes/ hyaluronic acid polyelectrolyte membrane to bone marrow mesenchymal stem cells on titanium surface.

Methods: Cationic polyelectrolyte is lipopolysaccharide-amine nano-polymersomes. Anionic polyelectrolyte is hyaluronic acid. Polyelectrolyte films were constructed by Layer by layer self-assembly technique. The morphology of titanium surface was observed by scanning electron microscopy before and after assembles. Physical and chemical characterization of polyelectrolyte films measured by UV spectroscopy and contact angle measurements. The adhesion, proliferation, differentiation and originally transfection capability of bone marrow mesenchymal stem cells on the polyelectrolyte films were studied as well.

Results: The titanium surface becomes relatively smooth since the assembly process of films. DNA absorption peaks appear at 260nm in UV spectrum. Absorption peak intensity increases as the films assembling. The contact angle increases in jagged shape alternately, which further proofed films assembly success. The surface of pNPs-$(HA/pNPs)_4$ can enhance the adhesion, proliferation and differentiation of MSCs, and the difference is statistically significant compared to Ti and alkali-heat treated Ti groups. In situ transfection capability of the films also confirmed.

Conclusion: Construction of the polyelectrolyte films with lipopolysaccharide-amine nano-polymersomes and hyaluronic acid was successfully assembled and has good biological effect for cells.

Key words: Titanium;Layer-by-Layer self-assemble; Polyelectrolyte multilayer films; Lipopolysaccharide-amine nanopolymersomes; Bone morphogenetic proteins2

45

The Impact of Oral Rehabilitation on Head and Neck Cancer Patients by Liverpool Oral Rehabilitation Questionnaire (LORQv3) Along with Oral Health Impact Profile (OHIP-14)

KanchanDholam，GunjanChouksey

Tata Memorial Hospital

Purpose: Cancer therapy affects oral functions. Oral rehabilitation attempts to address such issues and is specifically aimed at improving and enhancing the quality of life of patients. The purpose of this study is to assess the impact of oral rehabilitation on head and neck cancer patients' by using (LORQv3) and (OHIP-14) questionnaire and to carryout and document specific patient-deprived problem in relation to the issues of oral rehabilitation.

Methods: Sixty patients who are in need of oral rehabilitation will be recruited. General patient's information and treatment details will be recorded .Patients will be asked to rate their experience of dental problems before fabrication of prosthesis (baseline) and at the 3 months and one year follow-up visit after prosthetic rehabilitation by using LORQv3 along with OHIP-14. Descriptive and multivariate analysis will be done. Subscale scores will be determined by mean value and p-value ($P < 0.05$) will be considered statistically significant.

Results: LORQv3: Changes in the domains of oral functions, orofacial appearance and prosthesis satisfaction etc will be noted. Similarly assessment of the various domains like functional limitation, psychological disability, social disability and others of OHIP-14 will be done.

Conclusion: The impact of prosthetic intervention has contributed in improving oral rehabilitation.

Key words: Oral rehabilitation; Quality of life; Oral functions

46

Meticulous Reconstruction of Oral and Maxillofacial Soft Tissue Defects After Tumor Ablation—the Principle, Method, and Reconstructive Efficacy

Wu HanJiang

The Second Xiangya Hospital, Central South University

Purpose: To discuss the methods of meticulous reconstruction of oral and maxillofacial soft tissue defects after tumor ablation, and to evaluate the reconstructive efficacy.

Methods: 1.The thorough resection of tumor and the preserve of important structures, the selection of appropriate flaps, and the meticulous suture. Tongue reconstruction: The restoration of tongue movements, the reconstruction of hyomandibular furrow, and the stitching order of tongue reconstruction. Cheek reconstruction: To retain the vermilion as much as possible, and vermilion reconstruction with vermilion flaps; to reconstruct the through-and-through cheek defects with chimeric flaps; to increase the thickness of the cheek or/and to cover the titanium plate with fat flaps; the flaps that provide the intraoral mucosal lining should be slightly larger than the defects and should be sutured while the mouth is open, and mouth-opening exercises should be practiced postoperatively to avoid or decrease limitations in mouth opening; the flaps that provide the extraoral skin lining should be slightly smaller than the defects and should be sutured with some tension to improve the relaxation of the lips after facial nerve resection. Soft palate reconstruction: The nasal side mucosa reconstruction of the soft palate, the proper thickness of skin flap, and the preserve of the shape of uvula.2. Reshaping the reconstructed structures. The linguistic and swallowing functions, especially the tongue; oral balloon assisted training and elastic mask.

Results: The appearances and functions in all patients were satisfactory after the reconstruction, and all the donor sites healed well without significant morbidity.

Conclusion: Meticulous reconstruction of oral and maxillofacial soft tissue defects after tumor ablation can achieve satisfactory functional and aesthetic results.

Key words: Meticulous reconstruction; Oral and maxillofacial; Soft tissue defects

47

Unique Prosthetic Support for the Extended Oncologic Team Members

James A. Kelly

Mayo Clinic College of Medicine

In today modern age of oncologic treatment, it is vital that each patient receives customized prosthetics undergoing radiation therapy or surgical resection. To improve the surgical outcome, and to decrease the side effects of radiation, it is of utmost importance to have the maxillofacial prosthodontist working together with our colleagues. The objectives of this lecture are to: 1) describe multiple fabrication techniques for radiation devices, 2) discuss prosthetic devices to aid our surgical colleagues, and 3) explain different prosthetic techniques to enhance our patients' lifestyles. This presentation will increase the awareness and implementations of Maxillofacial Prosthetic techniques for the oncologic team.

48

Correction of Mandibular Deviation by Combination Therapy of Maxillary Ramp Prosthesis (MRP) and Mandibular Guide Flange Prosthesis (MGFP) in Mandibular Defect Case

Nafij Bin Jamayet, ZaihanAriffin, Adam Husein, Mohammad KhursheedAlam

School of Dental Science,UniversitiSains Malaysia

Purpose: Loss of the continuity of the mandible due to mandibulectomy destroys the balance and the symmetry of mandibular function, leading to altered mandibular movements and deviation of the residual fragment towards the surgical side. To solve this problem mandibular guidance therapy is needed to minimize deviation of the mandible.

Methods: A 27 year old malay man was referred to maxillofacial prosthetic service, school of dental science, UniversitiSains Malaysia, kotabharu, Malaysia for prosthetic rehabilitation following hemi-mandibulectomy of left mandible due to ameloblastoma. The treatment plan involved correction of mandibular deviation and restoration of edentulism associated with the defect area. A maxillary ramp prosthesis (MRP) with mandibular guide flange prosthesis (MGFP) was made and given to patient for muscle exercise and reprogramming to improve the mandibular deviation.

Results: Muscle reprogramming exercises with maxillary ramp prosthesis with mandibular guidance flange therapy were performed for 2 months. On first follow-up after 2 months, the deviation of mandible and the occlusal equilibration was improved after using both the prosthesis.

Conclusion: Mandibular guidance therapy with combination prosthesis can be a useful adjunct to preserve the mandibular function after partial mandibulectomy procedures and to minimize complications associated like mastication, speech and swallowing. An organized mandibular exercise is suggested for eliminating mandibular deviation and uncoordinated muscle movements for successful rehabilitation.

Key words: Mandibular guidance; Hemi-mandibulectomy; Mandibular deviation

49

Saving Faces Changing Lives

Bilal Ahmed

National University of Science & Technology (NUST), Islamabad. Pakistan

Purpose: 1. To highlight the importance of classical prosthodontic principles and materials in maxillofacial rehabilitation.2. To justify significance of simple cost effective and time saving techniques in scenarios where latest equipments and expertise are not available.3. to present immediate, interim or definitive prosthodontic solutions with use of basic dental materials in short time span.

Methods: Case series presentation of maxillofacial defects treated with use of simple cost effective prosthodontic techniques and conventional dental materials.

Results: Prosthodontic rehabilitation of either congenital or acquired maxillofacial defects is always a challenging clinical scenario. these defects pose a major physiological and psychological threat not only to the patient, but to the entire family. a multidisciplinary team approach, thorough investigation, long term followup, proper counselling and a sympathetic attitude may help to bring the affected humanity back to normal life stream.There has been an enormous scientific development in maxillofacial rehabilitation with the advent of cad-cam, 3-d scanning, osseointegrated implants and improved restorative materials. there are specialized centers with latest diagnostic and treatment facilities in the developed countries. However, in certain clinical case scenarios, conventional prosthodontic principles are still the gold standards. as in less developed world, financial and technical constraints are factors affecting treatment planning and result outcomes. however, we can do a lot of benefits to the affected human beings, even with use of simple and cost effective conventional prosthodontic techniques and materials. these treatment strategies may sometimes be considered as

intermediate or temporary options, but with regular followup maintenance can be used on definitive basis.

Conclusion: Treatment outcomes have been enormously improved with use of latest diagnostic and procedural equipments like cad cam, 3-d scanning and implants but in lack of these facilities, acrylic resins, silicones and denture making techniques have significantly improved halth related quality of life and psychosocial well being of our patints.

Key words: Maxillofacial rehabilitation； Prosthodontics; Nasal prosthesis

50

Improvement of Swallowing and Articulation by Using Palatal Augmentation Prosthesis in a Semi-total Glossectomy Patient

YoshitomoMinagi, TakahiroOno, ShigehiroFujiwara, YoshitsuguTokuda, Kazuhiro Murakami, Masaaki Yamamoto, Yoshinobu Maeda

Osaka University Graduate School of Dentistry

Purpose: This case report presents the recovery process of articulation and swallowingfunction by fabricating Palatal Augmentaion Prosthesis (PAP) and mandibular partial denture with extended saddle.

Methods: A 39 year-old male patient who underwent subtotal glossectomy, radial neck on the right side, and reconstruction using forearm flap under the diagnosis of recurrent tongue carcinoma. Speech intelligibility (assessed by 10 speech language pathologists), food test and a VAS(visual analog scale) questionnaire for articulation, chewing, swallowing was evaluated before and after the fabrication of PAP and mandibular partial denture with extended saddle.

Results: By the application of PAP and modified mandibular denture, speech intelligibility score was improved from 3.3 to 2.2,and the amount of oral residue reduced. It was confirmed by the VAS questionnaire that subjective assessment of swallowing and articulation was remarkably improved.

Conclusion: Those prostheses improved speech intelligibility and swallowing ability through securing tongue-palate contact and optimizing oral cavity volume.

Key words: Tongue; Articulation; Swallowing; Glossectomy; Palatal augmentation prosthesis

51

The 3-stage Therapeutic Process of a Sequence Obturators for Maxillectomy: a Case Report

Li Yan, Wu Shuyi

Guanghua School of Stomatology, Hospital of Stomatology, Sun Yat-Sen University

Purpose: To discuss a detail clinical pathway about 3-stage therapeutic process of a sequence obturators for maxillectomy through a typical clinical case

Methods: There are 3 prosthodontic therapeutic stages for maxillectomy: 1. Surgical obturator stage (2 week perioperative period of maxillectomy), discussing with surgeon, impression and manufacture a surgical obturator before operation and place it intraoperative period. 2 .Interim obturator stage (from 1 week to 3 month postoperatively), 2 obturators need to be used, one is the modified surgical obturator use soft liner material, another is the new interim obturator fabricated with artificial teeth.3. Definitive obturator stage (3 month after operation), natural teeth with clasps or implant abutment with attachment to be retentions of the obturator according to planning. Typical case report CB is male, age 63, who was diagnosed with a right maxillary sinus carcinoma need a right maxillectomy. He had experienced fully 3-stage therapeutic process of obturator prostheses. The evaluation items include the appearance, seal,

phonation, retention and mastication functions.

Results: 1. At surgical obturator stage, a sufficient communication with the surgeon confirmed postoperative defect range, skin graft requirement, schedule of operation & restoration, and so on. A suitable surgical obturator provides a good phonation. 2. At interim obturator stage, soft liner modified surgical obturator maintained phonation. A new interim obturator with artificial teeth provided a part of chewing function. 3. In the definitive obturator stage, natural teeth and implant abutments were used to be retention and support of the obturator. A good appearance, phonation, retention and available mastication functions were be obtained.

Conclusion: Successful sequence prostheses of maxillectomy can provide available appearance, phonation, retention and mastication functions if the 3-stage therapeutic process is assured to be used.

Key words: Maxillectomy; Obturator; Sequence therapeutic process; Prosthesis,

52

Three-dimensional Finite Element Analysis of Obturator Retained with Anterior Attachment in Maxilloectomy Patients

Chu Xiaoyang, Wang Yanyi

1 Department of Stomotology, Affiliated Hospital, Academy of Military Medical Sciences,Beijing 100071,China. 2 Department of Stomatology, Chinese PLA General Hospital

Purpose: To establish the FEA models of unilateral maxillary defect and obturator retained with maxillary anterior attachment. Finish the FEA analysis through vertical and lateral loading.

Methods: Use Mimics10.01 software to read and reconstruct the image data obtained by scanning a normal complete dentition volunteer to establish the 3-D solid model of unilateral maxillary defect and obturator. Cut the left maxilla by the software in order to build unilateral maxillary defect model. Use CATIA V5 software to establish 3-D model of SG mini slide-type attachment. Then, use ANSA software modify and assemble it to initial obturator to form the FEA model of attachment retained obturator. Cut the maxillary central incisor , lateral incisors, canine and first premolar of unilateral maxillary defect model to meet the requirement of porcelain crown abutment preparation. Compare stress value and distribution in FEA models of attachment retained obturator with different number of associated porcelain crowns with FEA model of clasp retained traditional obturator after vertical and lateral loading.

Results: The establishment of 3-D FEA model of unilateral maxillary defect, the model has good biomechanical similarity to the real ones.The models with attachment retained obturator has significantly reduced overall maximum stress, even stress distribution of abutments. Considering tissue preservation, stress analysis of abutments and alveolar bone, the model with three abutments associated porcelain crowns works best.

Conclusion: As the results of this study, obturators retained with anterior attachments have advantages in even stress distribution of abutments, avoiding excessive stresses and improving retention and stability of denture comparing with traditional obturators retained with clasps.

Key words: Maxillary defect; Finite element analysis; Obturator; Attachment

53

NAM Appliance Design Utilizing a New Geometric Format

Jeff Rodney (presented by Ting-Ling Chang)

Maxillofacial Prosthodontist,University of Michigan

Purpose: Nasoalveolar molding (NAM) has become a commonplace adjunctive technique in preparing infants with cleft lip (with or without cleft palate) for surgical correction. Multiple approaches to designing the NAM tray appliance have been described in the literature with the common intent to approximate the cleft alveolar segments. The purpose of this study was to explore and develop a systematic approach for NAM applying simple geometric principles.

Methods: Multiple casts of unilateral cleft cases at various stages in treatment were analyzed. A vast array of anthropometric measurements and landmarks were identified and utilized in geometric form to facilitate material application for improved NAM results.

Results: Multiple geometric shapes in relation to involved alveolar cleft segments were studied. The anterior end points of the alveolar crest segments were used to outline a box-like shape that elucidated where segment movement should be achieved to minimize cleft distance. An envisioned parabolic shaped arch form with importance placed on midline positioning of the incisive papilla may also facilitate improved NAM results.

Conclusion: NAM treatment normally involves a subjective approach to material application and gauging of alveolar segment movement to diminish cleft space. This study intended to provide a format upon which more exploration into NAM design and approach for successful outcomes can be simplified, systematized and viewed as a technique-friendly treatment modality.

Key words: Cleft and palate; Nasoalveolar molding

54

The Clinical Experience of the Oral Prosthodontic Treatment in Cleft Lip and Palate Patients

Xing Guofang, Yu Dedong, Zhang Xiuyin

Department of Prosthodontics, Ninth People' Hospital, Shanghai JiaoTong University School of Medicine, Shanghai Key Laboratory of Stomatology. Shanghai 200011, China

Purpose: To discuss the preliminary clinical experience of fixed bridge treatment, removable denture treatment, double dentition treatment in cleft lip and palate patients.

Methods: In this paper, 100 patients of cleft lip and palate with conservative treatment were involved in. The clinical indications, advantages and disadvantages of the three conservative treatment ways were studied. From the aspects of chewing function, maxillofacial appearance, nose and mouth fistula, pronunciation and mental status, the three conservative treatment methods were compared.

Results: The three conservative treatments in cleft lip and palate patients can restore chewing function, maxillofacial appearance, nose and mouth fistula, and improve pronunciation and mental status to some extent.

Conclusion: For the cleft lip and palate patients who don'thave a surgical treatment,the conservative treatment is a simple, economical and practical restoration method.

55

Maxillofacial Rehabilitation – Challenges and Opportunities

Bhaskar Agarwal

Department of Prosthodontics, King George's Medical University, Lucknow, UP, India

Purpose: Changing lifestyle, increasing economic power and changed perception of esthetics have affected the maxillofacial rehabilitation as a profession for dental practitioners and as a treatment modality for patients.

The present study was carried out as a biforked survey of patient expectations and dental practitioners views regarding maxillofacial rehabilitation as a superspeciality practice domain.

Methods: A total of 100 patients visiting the prosthodontic rehabilitation clinics of both the facilities and a total of 50 postgraduate students and faculty members were interviewed regarding their perceptions regarding maxillofacial rehabilitation as a treatment modality and as a career option were obtained using two different semi-structured schedules for patients and professionals respectively.

Results: Around 90% of patients were not clear about the kind of treatment provided by maxillofacial rehabilitation. Most of the patients (89%) considered it to be a treatment option for prosthodontic rehabilitation only. Only 67% patients were aware about the role of maxillofacial rehabilitation in esthetic dentistry. Females were more aware about the esthetic aspect (74%) as compared to males (60%). Most of the patients were concerned about the financial aspect (88%). With respect to dental practitioners, only 20 out of 50 (40%) expressed willingness to opt for maxillofacial rehabilitation as a career option. Among those willing to opt maxillofacial rehabilitation as a career option – challenging work and patient satisfaction were the most important motivating areas while among those unwilling to opt it as a career option paucity of cases and infrastructural facilities were reported to be the barriers in their decision. Concern regarding financial remuneration was expressed as a big barrier by majority of those who opted and who did not opt it as a career option.

Conclusion: Awareness regarding scope of maxillofacial rehabilitation among patients is limited, financial aspect is the most important area of concern for both patients as well as dental professionals in its emergence as a separate superspeciality practice domain.

Key words: Maxillofacial rehabilitation; Maxillofacial prosthesis; Esthetic dentistry

56

Multifunctional Nanoparticles Based on Molecular Recognition for Cancer Cell Targeting and Traceable Intracellular Drug Delivery

Li Guolin

Department of Oral and Maxillofacial Surgery, The First Affiliated Hospital of Harbin Medical University

Purpose: Nanoscopic therapeutic systems that incorporate therapeutic agents, molecular targeting, and diagnostic imaging capabilities are designed and prepared as the new generation of multifunctional nanomedicine to improve the therapeutic outcome of oral squamous cell carcinoma.

Methods: Firstly, the hydrophilic anticancer drug clofarabine was functionalized with hydrophobic alkyl chains to form amphiphilic structure, which could further self-assemble into nanoparticles in water. Then, through the molecular recognition of nucleobases, incorporating the targeting unit aptamer AS1411 and fluorescent groups into the nanoparticles was realized by intermixing of different building blocks. Finally, the in vitro antitumor experiments were evaluated by MTT assay, flow cytometer and confocal.

Results: *In vitro* studies confirmed that multifunctional nanoparticles could target tumor cells efficiently, trace the drug release and induced the apotosis of oral squamous cell. All the results

demonstrated that the reported multifunctional nanoparticles synergistically integrated with cancer targeted drug delivery and controlled release and fluorescent imaging functions augur well for their potential applications as theranostic systems.

Conclusion: These results suggest that multifunctional nanoparticles based on molecular recognition can enhance chemotherapy in oral squamous cell carcinoma. Such strategy holds a great potential in the treatment of oral cancer.

Key words: Chemotherapy; Multifunctional nanoparticles; Drug delivery; Molecular recognition

57

Effect of Radiotherapy and Chemotherapy on the Quality of Life in Nasopharyngeal Carcinoma Patients: A Pilot Study

Teoh KH, Sim C , Seetoh YL

National Dental Centre Singapore

Purpose: The aim of this study was to determine the impact of radiotherapy and chemotherapy on the quality of life (QOL) in nasopharyngeal carcinoma (NPC) patients.

Method: Twenty-two nasopharyngeal carcinoma patients scheduled for intensity-modulated radiotherapy, who met the inclusion criteria and gave informed consent were c recruited. All patients were rendered dentally fit before undergoing radiotherapy. Study subjects were asked to fill up the University of Washington QOL questionnaire (UW-QOL v4) with the assistance of a trained interviewer at 3 time points: pre-radiotherapy and 2 weeks post-radiotherapy and more than1 year post-radiotherapy. Occurrence and timing of chemotherapy was recorded.

Results: Nineteen males and 3 females with a mean age of 50.6 years (SD: 11) participated in the study. One patient was diagnosed with Stage 1 disease, 5 with Stage II, 11 with Stage III, 5 with Stage IV. Five patients had radiotherapy alone. Seventeen patients had both chemo and radiotherapy, of which six had neo-adjuvant and concurrent, five had concurrent and six had concurrent and adjuvant chemotherapy. Nineteen patients returned for the 2 weeks post-radiotherapy review and 12 patients returned for the > 1 year post-radiotherapy review.

The changes in the composite QOL scores based on 3-way comparison of pre, post and >1-year review were statistically significant. There was significant change comparing post versus pre-radiotherapy (mean 61.2 versus 91.4; $p < 0.0001$). The mean composite score went up to 80 at > 1year post-radiotherapy review ($p = 0.001$). Chemotherapy and its timing did not significantly affect the composite QOL scores for pre, post and > 1year post-radiotherapy review. Taste, swallowing and pain were domains of major concern for patients at 2 weeks post-radiotherapy. Upon recall after 1 year, domains of major concern were saliva, pain and swallowing.

Conclusion: Radiotherapy significantly affects the QOL of NPC patients. No significant adverse effect was seen with concurrent chemotherapy. The 3 most important factors affecting the QOL of these patients one year after completion of radiotherapy were saliva, pain and swallowing.

Key words: Quality of life; Radiotherapy; Chemotherapy

58

The negative effects of postoperative radiation on the rehabilitation of maxillary defect patients

Ren Weihong,Ao Hongwei, Lin Qing , Hong Xiaobin

Capital medical university

Purpose: To observe the affection of postoperative radiation therapy on the treatment of trismus

recovery of esthetic of maxillectomy patients.

Methods:1.22 maxillary defects patients, 14 patients received postoperative radiotherapy,8 patients did not, were trained to practice mouth opening exercises from one week to 4 week after their operation. The maximum incisor distance (MID) was measured. 2.The face of 22 patient, 13 patient received postoperative radiation therapy , 9 patients did not, with and without their obturators were scanned by 3D laser Scanner (BIMU 0908X). The 3D facial images were recorded, converted and exported as STL models by geomagic studio software .Then 3D geometric models were established by the software. The Maximum space distance (MSD) was measured and used as the parameter to evaluate the esthetic restoration of patient face.

Results: 1.The result show that In both groups, the final MIDs were statistically higher than the initial ones($P<0.05$). However, significant difference was not achieved from the data ($P=0.105>0.05$) in this study between Group Radiotherapy and Group Non-radiotherapy.2. The MSD without obturators in NO-RT group was lower than that of RT group ,6.58mm versus 9.84mm.and it was still lower with obturator than that of RT group, 2.82mm versus 4.73. these difference were statistically significant $P<0.05$

Conclusion: 1. Patients can be suggested proper mouth opening exercises during the radiotherapy.2 .Postoperative radiation therapy has negative affections on esthetic recovery of Maxillary defect patient. Specious clinic cares should be taken for them

Key words: Postoperative radiation therapy; Maxillary defect trismus; Esthetic

POSTER PRESENTATIONS

Session I – Advanced Digital Technologies and Maxillofacial Rehabilitation

1

Rehabilitation of Prefabricated Hollow Obturator Prosthesis in Maxillary Sinus Carcinoma Operation：11 Cases Report

Yan Haixin, Zhu Haiting, Lu Li

Affiliated Hospital of Stomatology, China Medical University

Purpose: To fabricate the prefabricated hollow obturator prosthesis and evaluate their influences on patients with one side of maxillary defect.

Methods: Eleven patients with one side of maxillary defect caused by maxillary sinus carcinoma operation were collected in this study and received prefabricated hollow obturator prosthesis. Patient's self-assessment of masticatory efficiency, satisfaction, pain etc. were analyzed.

Results: Patients who received prefabricated hollow obturator prosthesis were satisfied with the improvement of appearance, could be normal chewing and swallowing without choking food. Not only there were no obvious discomforts, but also they could adapt to the process quickly.

Conclusion: The prefabricated hollow obturator prosthesis could be considered as an effective prosthesis for maxillectomy patients by reconstructing the form of oral cavity, improving the masticatory efficiency and speech intelligibility. It was helpful to improve the quality of life of patients.

Key words: Maxillary sinus neoplasms; Maxillary defects; Prosthesis

2

Computerized Project for Reconstruction Surgery, Implantology and Prosthetic Rehabilitation in Mandibular Defect

Didier Maurice

UFR Odontologie Paris 7-Denis Diderot French

Purpose: The objective of the mandibular reconstruction after resection surgery is to restore the aesthetics by an osseous support for the soft tissue but also and especially to restore the functions of chewing and deglutition by stabilizing the native mandibular sector and the bone in the resection area.

Methods: The surgery of reconstruction by fibula has to lean and be guided by the prosthetic project, the only guarantee for the good positioning of the implants and of osseous transplant. For that, it is necessary to digitize simulated. The axis of implants is defined by the setting of teeth and the fragment of fibula is modelled according to these axes under the prosthetic surgery, the guide is positioned on the fibula, the implants are placed and then the fibula is cut. At the end of surgery, a fixed transitory prosthesis must be screwed on the implants or a removable prosthesis is placed.

Results: This prosthesis is the prospective prosthetic project. After a few months of healing the definitive fixed prosthesis is made using the common steps of the prosthesis supported by implants.

Conclusion: The prosthetic rehabilitation for a maxilla or mandibular defect during or after reconstructive surgery must be the result of a prosthetic project because the bone framework is in relation with the position and the axis of the teeth. It is essential to do a prospective setting of the teeth

and to include it in the CT-Scan study with the simulation of the resection bone. Then, the fibula framework is determined with the software from the prosthetic project and the axis of the teeth.

Key words: Maxillofacial prosthetic rehabilitation and surgery; Implants; Fibula

3

The Clinical Application of Computer-aided Designing and Manufacturing of Defected Maxilla Cast

Dai Tong

Department of Prosthodontics，School and Hospital of Stomatology，Peking University

Purpose: To test a new cast-making method based on computer-aided designing and manufacturing for defected maxilla.

Methods: Head CT data of 18 patients with defected maxilla were transmitted into the computer. Three-dimensional digital image of the patient's defected maxilla was then obtained with special software processing based on Mimics 8.11 and Geomagic 7.0 and the plastic cast of the defected region was manufactured by prototyping. The obturator was then made on this plastic cast which can duplicate the undercut tissue of defected area. The prominent part of the obturator was made of elastic heat-curing resin and it was helpful to gain the retention through the engagement between the obturator and the tissue undercut. After the obturator was finished, the upper removable partial denture was made traditionally. Then the combination of these two parts was achieved by magnetic attachment. The clinical effects of obturator and removable partial denture were then evaluated and the nasalance values of 5 patients before and after wearing the obturator were measured by nasometer.

Results: The obturator and removable partial denture can be seated into place separately. They all had good retention and stability. After the obturator was seated in place, the nasalance of nonnasal consonant text decreased significantly from 46.53±13.86% to 22.60±8.52% ($P<0.001$).

Conclusion: The cast-making method based on computer-aided manufacturing for cast-making of defected maxilla is feasible and practical. It can solve problems faced with conventional impression methods and get good clinical result.

Key words: Computer-aided designing and manufacturing; Defected maxilla; Obturator; Resin model

4

Effects of Three Types of Veneering Porcelain on Bending Strength of KAVO™ Y-TZP/porcelain Bilayered Structure

Gu Bin, Yang Yang, Lu Rongjian, Wen Ning

Department of the Prosthodontics, The General Hospital of Chinese PLA

Purpose: The purpose of this study was to investigate the effect of three types of veneering porcelain on the bending strength of KAVO™ Y-TZP/porcelain layered structure.

Methods: KAVO™ zirconia ceramics were selected as substructure. To forming Y-TZP/porcelain bilayered structure, a leucite based veneering porcelain was fired on the zirconia substructures by slip-casting technique with dentin washbake, and two nano-fluorapatite based veneering porcelain was fired on the zirconia substructures either by slip-casting or pressed-on technique with or without liner coverage. Bending strength was tested according to ISO 6872 standard, and the veneered surfaces of fracture samples were analyzed by SEM.

Results: For covering KAVO ™ zirconia core material, conventionally applied veneering slurry-porcelain combined with liner or wash firing has significant higher bending strength than pressed-on

porcelain. SEM showed that the main failure type at the interface was adhesive.

Conclusion: Thin layer sintering as applying washbake program or liner on KAVO ™ zirconia surface increased the surface wettability, this procedure may be indispensable when veneering on the surface of dental zirconia.

Key words: Dental ceramics; Zirconia; Mechanical properties

5

Comparative Analysis of the Upper Airway Volume Using Lateral Cephalogram and Cone-beam Computed Tomography

Feng Xin, Li Gang, Qu Zhenyu, Liu Lin, Nässtrom Karin, Shi Xieqi

Department of Oral and Maxillofacial Radiology, Stomatological Hospital, Dalian

Purpose: This study aimed to evaluate the ANR (adenoidal nasopharyngeal ratio) on lateral cephalograms on assessing the upper airway volume using CBCT images as validation method.

Methods: Thirty-two patients (mean age 11.8±1.6 years) were included in the study and it was essential that the lateral cephalogram and CBCT images taken at the examination were not more than 1 week apart. ANR was measured on the lateral cephalograms. The area and volumetric measurement of the nasopharynx (NP) and the total upper airway were obtained on CBCT images. Repeated measurements of ANR and airway volume were performed on 10 cases by two observers.

Results: Correlation (r = -0.78) was demonstrated between the ANR and NP volume. The ANR presented a weak correlation (r = -0.48) with the total upper airway volume. Both measurements performed on lateral cephalograms and CBCT were highly reproducible in terms of intra- and inter-observer agreement.

Conclusion: Based on our results, the measurement of ANR on lateral cephalograms may be used as a screening method to estimate the NP volumes, throughout orthodontic treatment period when lateral cephalogram is readily available.

Key words: Adenoid; Nasopharynx; Cone beam computed tomography

6

The Study of Computer-aided Design for a Facial Prosthesis Using Three-dimensional (3D) Registration Technology

Qiu Jing, Tang Chunbo, Li Ming

Jiangsu Key Laboratory of Oral Diseases, Nanjing Medical University; Department of Oral Implantology, Affiliated Hospital of Stomatology, Nanjing Medical University

Purpose: The aim of this study was to investigate the feasibility of computer-aided design for a facial prosthesis using three-dimensional (3D) registration technology.

Methods: A patient with an extensive and complex maxillofacial defect was scheduled for a facial prosthesis. A fast structured-light scanning of the face and a spiral CT scan of the head were performed respectively. 3D reconstructions were correspondingly accomplished by Geomagic studio and Mimics software. Using 3D registration technology, the structured-light surface was superimposed on the reconstructed CT soft-tissue surface by corresponding landmarks and the iterative closest point (ICP) algorithm. Then, a 3D virtual model of the maxillofacial defect with underlying skeletal structure was created. Registration differences were calculated for validity estimates. Based on the acquired 3D virtual model, computer-aided design for a facial prosthesis of the patient was carried out using

Geomagic software.

Results: A complete 3D virtual model of the maxillofacial defect with underlying skeletal structure was generated using registration. The average registration difference was 0.5 mm. A facial prosthesis of the patient was designed based on the 3D virtual model.

Conclusion: 3D registration technology can be utilized in the computer-aided design for a facial prosthesis.

7

Magfit-attachment-linked Sectional Obturator and Prosthesis for Maxillary Defects and Placket Restricted

Li Binghong, Yang Xiaodong, Ai Hongjun

Department of Prosthodontics, the Affiliated Stomatological Hospital, China Medical University, Shenyang, China

Purpose: To evaluate the clinical effect of rehabilitation with a magfit-attachment-linked sectional obturator prosthesis for maxillary defect and placket restrained.

Methods: The magfit-attachment-linked sectional obturator prosthesis was applied to treat 6 patients with maxillary defect and placket restrained. The integrative hollow obturator was for other 4 patients with maxillary defect only. The masticatory efficiency and speech intelligibility were measured respectively. The clinical effect of prosthesis was reflected individually.

Results: The sectional obturator joining by dental magnetic attachment can make the suffers with maxillary defects and placket restrained rehabilitate ahead .Wearing the obturator changed easily and stability and looked resumed a lot, got clear pronunciation, the masticatory efficiency and speech intelligibility can improve .

Conclusion: To apply the magfit-attachment-linked sectional obturator prosthesis in maxillary defects and placket restrained can achieve perfect effect.

8

Retrospective Clinical Study on the Application of Magnetic Attachment in Maxillofacial Prosthesis

Li Chuanjie, Li Yanan, Wei Zening

Department of Stomatology, Chinese PLA General Hospital

Purpose: Investigation on the magnetic attachment in maxillofacial prosthetic restoration in clinical application. Discussion on how to increase the magnetic attachment stability and clinical use of personalized.

Methods: A computer search was performed in PubMed using key words of "magnetic attachment, maxillofacial prosthesis" in English， and in SinoMed network edition and CNKI database and Wanfang database using keywords of "magnetic attachment, prosthesis" in Chinese.

Results: There are 93 literatures (after 1980) about the magnetic attachment of complex maxillofacial prosthesis, including 78 Chinese literatures and 15 English literatures. Repeated and similar researches were excluded. There are 46 standard literatures were summarized.

Conclusion: Magnetic attachment can effectively improve the retention and stability of maxillofacial prostheses, patients feel more comfortable and satisfaction. According to the specific condition of different patients, it is necessary to choose appropriate the magnetic attachment connection mode and morphology which can make better retention and stability, easier to wear and take off, more clearly

pronunciation and restored much better masticatory function.

Key words: Magnetic attachment; Maxillofacial defect; Prosthesis

9

Acoustic Characteristics of Vowels in Trismus Simulated Condition

Mahmoud E. Elbashti, Mariko Hattori, Yuka I. Sumita, Hisashi Taniguchi

Maxillofacial Prosthetics Department, Tokyo Medical and Dental University

Purpose: In maxillofacial rehabilitation, speech evaluation is important and the acoustic evaluation of vowels is often taken place in patients with maxillofacial resection. Those patients often suffer from trismus as a result of tumor resection and/or radiotherapy. The degree of mouth opening affects the oral function which include speech articulation. The aim of this study was to evaluate the acoustic characteristics of vowels articulation in trismus simulated condition.

Methods: Digital acoustic analysis of five Japanese vowels, /a/, /i/, /u/, /e/ and /o/, was performed on 12 normal male subjects with and without mouth opening limitation. The trismus condition was simulated by using mouth opening limitation device. A simple set of acoustic descriptions called the first and second formant frequencies, formant 1(F1) and formant 2 (F2), were applied and calculated utilizing an auto-correlation method of linear predictive coding. Wilcoxon signed-rank test was used for the statistical analysis.

Results: Recording of uttered vowels in trismus condition was successfully achieved by mouth opening limitation device. The F1 frequency values were significantly different between the normal and trismus simulated conditions for /a/ and /e/ (P= 0.002). The F2 frequency values were also significantly different between the normal and trismus simulated conditions for /a/ and /e/, (P= 0.003 and 0.012, respectively). The F1 range was significantly different (P= 0.003) between the normal and the trismus simulated conditions, while the F2 range did not differ significantly (P = 0.347) between the normal and the trismus simulated conditions.

Conclusion: It was suggested that speech articulation is affected by trismus. When acoustic characteristics of patients are discussed, prosthetic efficiency shouldn't be the only consideration, trismus condition should also be taken into account.

Key words: Trismus; Digital acoustic analysis; Vowels; Simulation; Speech articulation; Maxillofacial

10

Application Value Comparision of Cone Bean CT and Spiral CT in Jaw Defect Three-dimensional Reconstruction

Li Zhimin

Department of Oral Radiology, Stomatological Hospital of Jilin University

Purpose: Compare the application value of cone bean CT and spiral CT in jaw defect three-dimensional reconstruction.

Methods: Respectively, using CBCT and spiral CT to scan 10 hemi-maxillary defect patients' and 3 Mandible defect patients' craniofacial and conduct three-dimensional reconstruction with accompanying software.

Results: CBCT emerges a much more accurate, legible and emulational image compared to spiral CT.

Conclusion: CBCT may get a broader clinical application for its efficiency and accuracy in reconstructing jaw defects compared to spiral CT.

CBCT may get a broader clinical application for its efficiency and accuracy in reconstructing jaw defects compared to spiral CT.

Key words: Cone bean CT; Jaw defect; Three-dimensional reconstruction

11

The Three－dimensional Finite Elements Analysis of Different Rate of Clinical Crown－Root and Width of Marginal Alveolar Bone of Maxillary Central Incisor

Liao Muying, Zhang Yi

Affiliated Stomatological Hospital, Guangxi Medical University

Purpose: To evaluate the date and distribution of stress in periodontal membrane of the three-dimensional(3-D) finite element model of different rate of clinical crown－root and width of marginal alveolar bone of maxillary central incisor.

Methods: Reconstruct a 3-D parametric model of maxillary central incisor by reverse engineering software Geomagic, Mimics, and computer aid design program UG6.Then the 3-D parametric model was imported to Ansys Workbench software. Apply a force about 120N on the edge1/3 of the tooth 45 °tilted, set up 3-D finite element model and evaluate the date and distribution of stress in periodontal membrane and alveolar bone of different rate of clinical crown-root and width of marginal alveolar bone of maxillary central incisor.

Results: (1) When the width of marginal alveolar bone was 0.3mm, the rate of clinical crown-root was changing, the region of the maximum stress was on the cervix of the periodontal membrane and alveolar bone. When the rate of clinical crown-root was increasing, the area and date of the maximum stresses were increasing. When the rate of clinical crown-root reach at 2.25, the Von Mises stress on the peridental membrane was 26.8 MPa which is twice of the normal one. (2) When the rate of clinical crown-root was 1.8, the width of marginal alveolar bone the was decreasing, the area and date of the maximum stresses were increasing, but the rangeability is comparative smaller than former

Conclusion: (1) When the rate of clinic crown-root reach at 2.25, the Von Mises stresses on the peridental membrane were more than the tolerance range of the normal one. The continued force was liable to damage pericementum tissues. (2) When the width of marginal alveolar bone the was decreasing, the rangeability is comparative smaller than former, so we should pay more attention to the damage of the rate of clinical crown-root in clinics.

Key words: The rate of clinical crown-root; The width of marginal alveolar bone; Stress analysis

12

Application of Computer-Assisted Design and 3D-model in Mandibular Reconstruction by Free Fibular Flap

Sun Bin, An jiping, Zhang Wei

Department of Oral and Maxillofacial Surgery, Stomatological School of JiLin University

Purpose: The purpose of this clinical study was to evaluate the value of computer-assisted design and three dimensional model in mandibular reconstruction by free fibular flap.

Methods: 13 mandibular reconstruction procedures using the technique of computer-assisted design and individual 3D-modelby free fibular flaps were performed. The size of the flaps which were used for reconstruction defects ranged between 7 cm and 15cm, and the standard international HCL classification suggested by Jewer et al was used to categorise the defects of mandible. The digital three-

dimensional model of the maxillofacial skeleton and fibular were created using fine-cut(<1.5mm) axial standard computed tomography (CT) date. A virtual mandibular reconstruction with a fibula bone was performed using Mimics 8.1 software. The mandibular lesion was simulatively segmental resected, then the fibular osteotomies were planned by visualizing the reconstruction superimposed on the preoperative image of the mandible such that the outer contour of the mandible was restored. For cases in which a portion of the mandible was already absent, comparison to the normal side and the opposing maxillary dentition facilitated surgical planning. The individual model was then created by 3D-printer using RPM technology, Titanium reconstruction plate was then bent preoperatively to match the contour of the fibula and adjoining facial bones on the individual model. The fibular portion of the mandibular model was cutting into several segments at the turning points, then the fibula cutting guide was manufactured preoperatively to match the segments according to the lengths and angles. The cutting guide was then sterilized for intraoperation use as a reference. During surgery, the sterilized cutting guide was temporarily fixed to the harvested fibula bone, and a reciprocating saw blade was used to make osteotomies at the lengths and angles required to replicate the virtual plan.

Results: All of fibula flap were alive and no complication occurred. The method above both reduce the operation time and improve the precision of mandibular reconstruction. The patients were satisfied with the results both esthetically and functionally.

Conclusion: Computer-assisted design and three dimensional models have potential to increase the speed and accuracy of mandibular reconstruction.

Key words: CAD; 3D-model; Mandible reconstruction

13

Biomechanical Design and Fabrication of the Model of the Individual Mandibular Titanium Framework

Sun Jian, Jiao Ting, Zhang Fuqiang

Ninth People's Hospital, School of Medicine, Shanghai Jiaotong University

Purpose: To evaluate the stress distribution in the individual mandibular titanium framework and discuss the fabrication of the framework model by rapid prototyping.

Methods: A 3 Dimensional finite element model of the individual mandibular with holes in 4mm diameters and 3mm interval both vertically and horizontally was developed according to the defect of the mandible. The total modelling and solution processes were performed using the ANSYS. Then through image conversion, the resin model of the framework was fabricated by rapid prototyping.

Results: The highest stress value was lower than the yield strength of titanium. Stress concentration were at the areas between the holes. And stress concentration were also found between the denture abutment and at the junction of the framework and mandible. And resin model of the individual mandibular titanium framework designed was obtained.

Conclusion: The individual mandibular titanium framework designed in our study met the biomechanical requirement, and the biomechanical design and fabrication of the model of the mandibular titanium framework based on ANSYS and rapid prototyping was feasible.

Key words: Mandibular titanium framework; 3 dimensional finite element; Stress; Rapid prototyping

14

Clinical Application of Submental Island Flap on Repairing Oropharynx Defects after Cancer Ablation

Shang Wei

Department of Oral and Maxillofacial Surgery, the Affiliated Hospital of Medical College, Qingdao University

Purpose: To discuss the clinical effects of submental island flap on repairing oropharynx defects after cancer ablation, and provide experience for clinical application.

Methods: 13 oropharyngeal cancer patients, whose defects were repaired with submental island flaps in oropharynx regions after cancer ablation and radical neck dissection， were 12 patients with squamous cell carcinoma and 1 patient with myoepithelial carcinoma case.

Results: Of the13 flaps, 12 submental island flaps were suivival,1flap had partial necrosis at the distal edge, but healed after trim and dressing. The followed-up time was 3 months-3 years, and no one showed tumor recurrence or metastasis. The patients all got good eating and speech functions.

Conclusion: Submental island flap is safe and effective for repairing small or middle sized oropharynx defects after cancer ablation with being close to the oropharynx, located in the line of radical neck dissection, simple operation, hidden incision and fewer lymph node metastasis in I area. Submental island flap has excellent clinical application value.

Key words: Submental island flap; Oropharynx; Repair; Defect

15

Pre-surgical Nasal Molding for Infants with Unilateral Cleft Lip and Palate Using Multiple Digital Techniques

Zheng Yaqi, Liu Chen, Wu Guofeng

Department of Prosthodontics, School of Stomatology, the Fourth Military Medical University

Purpose: The unilateral cleft of lip and palate is characterized by severe nasal deformities, which need the treatment of pre-surgical nasal molding. The aim of this study is to introduce a novel method achieving a computer aided design and manufacturing (CAD/CAM) molding stent which was carried out on two 5-day-old patients with unilateral lip and palate cleft.

Methods: In this case, by using the 3D facial data acquired by 3dMD, we established a method to rebuild the virtual model by precisely covering the deformed side with a shape that is mirror-symmetrical to the normal nasal ala. In addition, a 3D quantitative system for evaluating the outcome of the correction was established as well.

Results: Finally, after accurate evaluation and design, the pre-surgical nasal molding stent was fabricated by the 3D printing machine automatically.

Conclusion: This technique may be an alternative approach of pre-surgical nasal molding to obtain normal nasal appearance before the cheiloplasty.

Key words: Cleft palate; CAD/CAM； Nasal deformity; Nasal molding stent

16

Acquisition of 3-dimensional Digital Models of Maxillary Defects Based on Multisource Data

Zhou Yongsheng, Ye Hongqiang, Hou Yuezhong, Ge Chunling

Department of Prosthodontics, School of Stomatology, Peking University

Purpose: Combined with spiral CT and intraoral scanning, to establish the precise 3-dimensional (3D) digital models of the defected part and maxillary dentition in patients with maxillary defects, which would make a basic and primary contribution to the digital design and manufacture of maxillary prosthesis.

Methods: Patients with maxillary defects were scan by spiral CT. The scan range must include the whole defected cavity and maxillary dentition. Then, the 3D images of the defected part and the maxillary dentition were reconstructed from CT data via Mimics. The precise intraoral 3D images were acquired by the intraoral scanner (e.g. 3Shape Trios), which contained maxillary dentition and soft tissues. The 3D images from CT data and intraoral scanner were registered via Geomagic Studio. And the defected cavity part from CT data and the maxillary dentition and soft tissues part from intraoral scanner were combined together, generating the precise 3D images needed for the digital design of maxillary prosthesis.

Results: The precise 3D digital models of maxillary defects were acquired via combining spiral CT and intraoral scanning, which contained the complete structures needed for maxillary prosthesis.

Conclusion: The combination of different source data is a feasible way to build up the complex digital models of maxillary defects.

Key words: Multisource data; Maxillary defects; 3-dimensional digital model

17

Inflatable Hollow Obturator Prostheses for Patients Undergoing an Extensive Maxillectomy

HouYuezhong, Huang Zhi, Ye Hongqiang, Zhou Yongsheng

Department of Prosthodontics, School and Hospital of Stomatology, Peking University

Purpose: Use inflatable hollow obturator to treat patients who has extensive palatal or maxillary defects.

Methods: Patients with extensive palatal and maxillary defects were included in this study. These patients underwent either total maxillectomy or radical partial maxillectomy that no tooth is maintained. First, we made a hollow silicone obturator according to the cast of the patients. Then, install an air valve into the obturator making it inflatable. Finally make an upper complete denture on the obturator to restore function and appearance of the patients.

Results: The inflatable obturator prosthesis could be extended further into undercut area to retain itself. It exhibited adequate retention, stability and border sealing, and improving the masticatory, pronunciation and swallowing functions for the patients.

Conclusion: Silicone-based inflatable obturators offer a technique for the reconstruction of extensive maxillary defects. It showed good clinical results for patients that are difficult to treat using conventional methods.

Key words: Inflatable; Maxillectomy; Maxillofacial defects; Obturator; Silicone

18

Mandible Reconstruction Assisted by Preoperative Simulation and Transferring Templates: Cadaveric Study of Accuracy.

Zheng GS, Liang Yujie, Su YX, Liao GQ, Liu HC, Zhang SE, Liang LZ

Hospital of Stomatology, Guanghua School of Stomatology, Sun Yat-sen University

Purpose: In this study we tried to define tumor resection, fibula cutting, and positioning by surgical templates to perform the mandible reconstruction surgery according to the preoperative simulation. The accuracy was evaluated through cadaveric surgery.

Methods: Five cadaveric mandibles and fibulas were obtained. Preoperative surgical simulation was performed. Surgical templates that defined tumor resection, fibula cutting, and positioning were designed and fabricated. Translation, angular deviation, and rotation of bone grafts, as well as translation of condyles, were measured.

Results: The reconstructed mandibles showed high similarity to the surgical planning. The mean translation, angular deviation, and rotation of fibula segments of the reconstructed mandibles were 1.35 ± 0.86 mm, 3.36° ± 1.86°, and 8.13° ± 5.35°, respectively. In the mandible remnants, the translation of condyles was measured, with a mean of 1.39 ± 0.66 mm.

Conclusion: Our method of defining the tumor resection; Fibula cutting, and positioning by surgical templates was accurate enough for mandible reconstruction surgery.

19

Mandible Reconstruction Assisted by Preoperative Virtual Surgical Simulation

Zheng GS, Su YX, Liao GQ, Liu HC, Zhang SE, Liang LZ

Hospital of Stomatology, Guanghua School of Stomatology, Sun Yat-sen University

Purpose: In this study, we evaluated the clinical efficacy of mandible reconstruction with preoperative virtual planning, which focused on esthetics and occlusion.

Methods: A series of 9 patients were enrolled prospectively to undergo mandibulectomy and simultaneous reconstruction. Preoperative spiral CT scans of the maxillofacial region and the fibula region were performed. Virtual surgery of tumor resection and fibula reconstruction was performed in the Mimics platform. The reconstructed mandible models were fabricated with CAD/CAM technique. The reconstruction plate and the positioning template were accommodated to the stereolithographic model as the surgical template.

Results: Surgery was performed accurately according to the templates. All the fibula flaps survived. The appearance and occlusion of the patients were satisfactory.

Conclusion: With preoperative virtual planning, the spatial relationship of the mandible and the fibula graft can be planned individually, which helps achieve optimum appearance and occlusion relationship.

Key words: Fibula; Mandible; Reconstruction; Defect

20

Mandibular Reconstruction Assisted by Preoperative Simulation and Accurate Transferring Templates: Preliminary Report of Clinical Application

Zheng GS, Su YX, Liao GQ, Liu HC, Zhang SE, Liang LZ

Hospital of Stomatology, Guanghua School of Stomatology, Sun Yat-sen University

Purpose: This study investigated the application of a computer-aided design and manufacturing technique of defining tumor resection, fibula cutting, and positioning by surgical templates in mandibular reconstructive surgery.

Methods: Four patients who required mandibulectomy and simultaneous reconstruction were enrolled in this study. Preoperative surgical simulation was performed. The surgical templates that defined tumor resection, fibula cutting, and positioning were designed and fabricated.

Results: The surgeries were performed to the preoperative plan. All flaps survived. Superimposition of the postoperative image and the preoperative plan showed a satisfactory surgical accuracy.

Conclusion: This method of defining tumor resection, fibula cutting, and positioning by surgical templates was accurate enough for mandibular reconstructive surgery.

21

Novel Method of Fabricating Individual Trays for Maxillectomy Patients by Computer-Aided Design and Rapid Prototyping.

Huang Zhi, Wang Xinzhi, Hou Yuezhong

Department of Prosthodontics, School and Hospital of Stomatology, Peking University

Purpose: Making impressions for maxillectomy patients is an essential but difficult task. This study developed a novel method to fabricate individual trays by computer-aided design (CAD) and rapid prototyping (RP) to simplify the process and enhance patient safety.

Methods: Five unilateral maxillectomy patients were recruited for this study. Based on the 3D surface reconstruction of the target area, an individual tray was manufactured by CAD/RP. With a conventional custom tray as control, two final impressions were made using the different types of tray for each patient. The trays were sectioned, and in each section the thickness of the material was measured. Statistics were used to examine the difference of the impression thickness. Afterwards, all casts were then optically 3D scanned and compared digitally to evaluate the feasibility of this method.

Results: Impressions of all five maxillectomy patients were successfully made with individual trays fabricated by CAD/RP and traditional trays. The descriptive statistics of impression thickness measurement showed slightly more uneven results in the traditional trays, but no statistical significance was shown. A 3D digital comparison showed acceptable discrepancies within 1 mm in the majority of cast areas. The largest difference of 3 mm was observed in the buccal wall of the defective areas. Moderate deviations of 1 to 2 mm were detected in the buccal and labial vestibular groove areas.

Conclusion: This study confirmed the feasibility of a novel method of fabricating individual trays by CAD/RP. Impressions made by individual trays manufactured using CAD/RP had a uniform thickness, with an acceptable level of accuracy compared to those made through conventional processes.

Key words: Clinical application; Feasibility; Impression technique; Maxillofacial prosthesis

22

The Significance of NHP to the Orbital Prosthesis Fabricated by Computer-aided Design and Computer-aided Manufacturing (CAD/CAM)

Xie Rui; Dong Yu; Bai Shizhu; Zhao Yimin

School of Stomatology, Fourth Military Medical University

Purpose: Orbital defects will not only affect the vision function，but also affect the facial expression. The key and difficult points of orbital prosthesis fabricated are to restore the aesthetics. The register of the normal head position (NHP) and three-dimensional surface images taken by 3dMD face scanner is conclusive to the edge, location and precision of orbital prosthesis when using computer-aided design .A simple method for obtaining NHP will also shorten the fabricating time of orbital prosthesis.

Methods: The patient's three-dimensional surface images taken by 3dMD face scanner register to the patient's frontal facial photographs of NHP obtained by a simple, easy-to-use method. The registration position of the three-dimensional surface images is in the NHP. Orbital prosthesis is designed and fabricated by using this images on a computer.

Results: Comparison of the orbital prosthesis registered by NHP and by the designer`s experience, the former is more convenient and have favorable edge. The orbital prosthesis morphology registered by NHP is also more realistic.

Conclusion: Previously orbital prosthesis designed by computer is registered by observing and measuring facial landmarks of patients. It depends on the experience of the designers. This method based on Two-dimensional frontal facial photographs of NHP is more precise than that based on designers` experience. And the frontal facial photographs of NHP is relatively simple and easy to implement. It would be more useful and practical for the orbital prosthesis fabricated by computer-aided design and computer-aided manufacturing.

23

Dose Study of LDCT Application to Reconstruct 3D Model of the Maxillofacial Hard and Soft Tissues

Gao Rui[1], Bai Shizhu[2], Zhao Yimin[2]

1. Department of Stomatology, the Affiliated Guangren Hospital of Xi'an Jiaotong University College of Medicine, Xi'an,710004, China

2. Department of Prosthodontics, School of Stomatology, the Fourth Military Medical University, Xi'an, 710032, China

Purpose: Evaluation of the feasibility of using low-dose CT (LDCT) to reconstruct three-dimensional(3D) model of the maxillofacial hard and soft tissues，to provide research evidence for using LDCT in computer aided prosthetic rehabilitation.

Methods: Lightspeed 16-slice spiral CT scanner was used to scan one adult cadaveric head specimens with conventional parameters (280mA) and low dose parameters(200 mA、150 mA、100mA、50mA、35mA、25mA、15mA、5mA); the 3D model of the hard and soft tissues were reconstructed with Mimics 10.01 software, and 3D comparison were carried on with Geomagic 11.0 software; A comparison of the surface morphology of the hard and soft tissues of the 3D model with different scanning parameters was made.

Results: With the reduction of the tube current, the models' surface became rough gradually. Compared to the 280mA scan results, the models' surface of 35mA was still fairing. But when fell to less than 25mA, the models' surface become so rough to distinguish its exact shape. It came to the same results of the test results of models' surface after registration.

Conclusion: The low-dose (35mA) CT can be used to reconstruct 3D model of the maxillofacial hard

and soft tissues.

Key words: CT; Low-dose; Three-dimensional model

24

3D Printing Technology and Its Application in Oral and Maxillofacial Treatment

Zhang Leiqing[1,2], Yuan Xigen[2], Dong Yan [1], Liu Yunfeng[2], Peng Wei[2]

1. Department of Prosthetic Dentistry, College of Medicine, Second Affiliated Hospital, Zhejiang University, Hangzhou 310009, China

2. College of Advanced Manufacture, Zhejiang Industry University

Purpose and methods: With the continuous development and progress of science and technology, production technology also achieves continuous improvement and updating. Presently, an advanced technology called 3D printing technology, can divided the reconstructed 3D digital model into layers, then piled layers up one by one into a physical model. In order to understand the development of 3D printing, as well as its advantages, and focuses on its application in oral and maxillofacial treatment, the authors spent eight months, refer to database of PubMed, Web of Science, Elsevier ScienceDirect, WanFang data, VIP journals, and CNKI, read 52 references. Eventually have a deep understanding about 3D printing technology, and also have a deep understanding about its application in oral and maxillofacial field.

Results: 3D printing first applied in the industrial engineering field, then be promoted in the field of clinical medicine, now it is widely used in orthopedics, cardiothoracic surgery, preoperative diagnosis of oral and maxillofacial surgery, surgical planning and simulation at various stages of various departments; The application of 3D printing technology in treatment of oral and maxillofacial field, broke through many disadvantages of traditional production process, brought the gospel to patients with oral and maxillofacial diseases; The main advantages of 3D printing technology is it can greatly save the cost, because it avoids waste problems which appeared in the traditional craft when molding products, in addition, it can also make full use of computer data to print products accurately, so it improve the precision of the products, truly achieve personalized production services.

Conclusion: Nowadays, 3D printing technology is the most popular production technology. It can bring great social change. People call it "The third industrial revolution". In this paper, we main refer to the 3D printing technology advantages when used in oral and maxillofacial treatment.

25

Computed Tomography Measurement of the Auricle in Han Population of North China

Wang Bo, Dong Yan, Bai Shizhu, Wu Guofeng, Zhao Yimin

Department of General Dentistry & Emergency, School of Stomatology, Fourth Military Medical University, Xi'an 710032 ShaanXi, China

Purpose: The current study sought to provide anthropometric data on normal auricles in a Han-Chinese sample using a 3D CT reconstruction technique.

Methods: We studied the CT data of 485 adult Han-Chinese people (244 males and 241 females). To examine the relationship between auricle dimensions and age, the data were divided into three age subgroups. All measuring points were determined using 3D reconstructed images. Sixteen anthropometric 'landmarks' on the auricles were used to record twelve dimensional measurements.

Results: The results revealed that auricular shape was largely identical bilaterally. Almost none of the anthropometric data for the bilateral position of auricles showed significant differences between sides, with the exception of auricular length and width, length and height of the tragus, and the conchal length. The results revealed that all linear dimensions of auricles, except for height of tragus and conchal length and width, increased significantly with age for both males and females. The auricular and lobular indices exhibited a tendency to decrease as age increased, for both males and females.

Conclusion: The auricle is an important defining feature of the human face. Its shape conveys information about age and sex that is striking yet difficult to characterise. Aesthetic plastic surgeons typically aim to achieve symmetry between the left and right auricles, but few data on auricle dimensions are currently available. This study exhibits the different morphometric measurements from normal auricles in 485 Han-Chinese using a 3D CT reconstruction technique. The results obtained in our study produced many effective parameters for auricle morphology, especially the relationship between auricle morphology and advancing age. We believe that the data presented in this study have many advantages over data obtained by traditional direct measurement techniques. These findings have potential implications for the diagnosis of congenital malformations, syndromes, and acquired deformities, in the planning of cosmetic surgery, and for the hearing instruments industry.

Key words: Computed tomography; Anthropometry; Han Chinese; Normal auricle

26

A Pilot Study on the Orientation of 3-dimensional Facial Images to Natural Head Position (NHP)

Dong Yu [1], Bai Shizhu [2]

1. Xi'an No.2 Hospital, Xi'an, Shaanxi Province 710032, PR China

2. State Key Laboratory of Military Stomatology, Department of Prosthodontics, School of Stomatology, Fourth Military Medical University, Xi'an, Shaanxi Province 710032, PR China

Purpose: With the development of computer-aided design and computer-aided manufacturing (CAD/CAM), the technology has been applied into maxillofacial prosthetics. During the production of prosthesis with CAD/CAM, it is essential to determine an appropriate facial reference to achieve a natural and harmonious prosthesis. Previous studies showed that natural head position reflects true appearance of an individual in real life， and is considered as an optimal reference for facial evaluation. In most of studies on recording and adjusting NHP, investigators used additional head devices to help achieving NHP, which, to some extent, might compromise the process the other way around. Herein, the present study reported a simple, easy-to-use approach to achieving NHP without attached facial devices.

Methods: We used full-face photographs of a head of a relaxed subject who stood and focused on an infinite horizon to aid calibrating 3-dimensional surface images taken by 3dMD face scanner. (1) A self-designed cartridge was made of acrylic, 250mm in height, 200mm in width and 300mm in length, and fixed on a tripod. A one-way mirror was set as its frontal wall. Based on the cartridge, a photographing system was established to aid the achievement of NHP in frontal view. (2) The frontal facial photographs of 42 volunteers were obtained using the systems at baseline, 1h, 1d, 3d and 7d, respectively. The angles between the lines connecting two outer canthus and horizontal line at each time point were measured and compared using one-way ANOVA and Bonferroni's multiple tests. (3) We established a method to correct 3-dimensional surface images according to the full-face photographs of NHP. Specifically, we calculated the 3-dimensional coordinates of four marked points on the surface of facial images using Geomagic Studio software, and then used the points to correct 3-dimensional facial images to NHP. Using the method, we compared angle difference of the corrected 3-dimensional facial images between baseline vs. 1h, 1d, 3d, or 7d respectively.

Results: 1. We have established a method to obtain full-face photographs. So we could easily record the NHP of a subject in frontal view after a few simple steps such as correction by a plumb line.2. We have evaluated the full-face photographs of 42 volunteers at different time points obtained by the above imaging system, resulting in that no statistically significant angle difference was observed between groups at different time points. It was indicated that our imaging system is reproducible.3. We have established a novel method to correct 3-dimensional images of random head orientation to NHP using 2-dimensional photographs of NHP in frontal view. Our study showed that the angle difference was significantly increased at longer time points. The increment peaked at 3d but slowed down at longer time point (7d), which was similar to the results from other studies.

Conclusion: We have established an easy-to-use approach to achieving NHP. Our method might be a feasible tool to study the reproducibility of 3-dimensional NHP imaging.

Key words: Prosthesis; Computer aided design & computer aided manufacturing (CAD/CAM); 2-dimensional full-face photographs; Natural head position; 3-dimensional surface images

Session II – Implants and Maxillofacial Rehabilitation

1

The UCSF Experience with Zygomatic Implants for Maxillary Defects

Arun Sharma

University of California, San Francisco, USA

Obturation of congenital and acquired maxillary defects in edentulous patients poses significant challenges for prosthodontists. Osseointegrated implants provide an alternative to surgical reconstruction. However, not all patients have adequate native bone for the placement of conventional implants. The zygomatic implant was introduced by P-I Branemark in 1988 and has been used with success for the appropriate patient. In 1999 an edentulous patient with an anterior maxillary defect presented to the maxillofacial prosthetic clinic at UCSF unsatisfied with the functional outcome from her conventional obturator. She had insufficient bone for placement of conventional implants and was not a candidate for extensive reconstructive surgery. She was offered the zygomatic implant as an alternative and was successfully treated. We proceeded to treat other patients with similar defects and published our initial findings from 9 patients in 2004. This presentation will highlight updates on our success and failures with the zygomatic implant for edentulous patients with congenital and acquired maxillary defects.

Learning Objectives:

The participants will be able to:1. ntify patients with maxillary defects who will benefit from treatment with zygoma implants as an alternative.2. l appreciate complications and maintenance for patients with maxillary defects who have been treated with zygoma implants.3. cess and failures will be discussed.

2

Facial Defects: Alteration at Surgery to Enhance the Prosthetic Prognosis

Gassino G, Bellia E

Prosthodontic Section, Department of Surgical Science, CIR Dental School, Turin, Italy

Purpose: Aim of the study is to discuss about the variety of circumstances that may dictate prosthetic

restoration of rhinectomy-orbital defects.

Methods: Surgical reconstruction of small facial defects is possible and in most cases is preferable, but if recurrence of tumor is likely, prosthetic restoration gives the advantage to monitor the surgical site closely. Surgical restoration of large defects is technically difficult and requires multiple procedures and hospitalizations. Patients confronted with this type of defect are usually older and less able or willing to tolerate the multiple procedures required for surgical reconstruction. Increasing numbers of this type of tumors are being treated with radiation therapy, whose collateral effects increase the risk of complications associated with reconstruction.

Results: The experience gained in the surgical treatment of defects resulting from resection of tumors of the nose, eyes and ears has brought improvements in prosthetic prognosis. Careful study of the anatomical site to be treated, the treatment of bone and soft tissue margins and the use of implants have led to these results.

Conclusion: Functional results of a well-made prosthesis allows the surgeon and the patient to monitor the wound over time, but to ensure a good aesthetic result it is necessary to improve as much as possible the prognosis, facilitating prosthetic rehabilitation and the social life of the patient.

Key words: Surgical reconstruction; Prosthesis; Tumor control

3

Rehabilitation of Patients with Reconstructed Mandible Using Implant-supported Prostheses

Lee Bora, Jung Hyunjung, Cha Inho, Han Donghoo

Department of Prosthodontics, Yonsei University Dental Hospital

Purpose: Patients with reconstructed mandible after mandibulectomy due to oral tumor are difficult to recover functionally and esthetically using conventional prostheses. In this case report, oral functional and esthetic rehabilitation of the oral tumor patients undergone mandibulectomy and mandible reconstruction using fixed and removable implant prosthodontic treatment were introduced.

Methods: In order for a lower denture to have appropriate support, stability, and retention, neuromuscular balance of tongue, lip, and cheek is important, denture bearing surface should be sufficient, and denture flange should be extended sufficiently into lingual sulcus. However, Patients with reconstructed mandible after mandibulectomy due to oral tumor have various degrees of anatomic structural change, limitation of jaw and tongue movement, reduced motor and sensory ability depending on tumor size, operated structure, and reconstruction methods.

Implant increases support of prostheses and resistance against lateral displacement. Establishment of implant prosthodontic treatment plan should be preceded by evaluation of the amount and quality of reconstructed hard and soft tissue. Bone should have sufficient width and height to ensure placement of fixture appropriate for support of a prosthesis. Reconstructed patients often have thick or movable soft tissue. If soft tissue in location of placement is too thick, there is potential risk of deepening peri-implant pockets, which increases possibility of infection in bone leading to failure of implants.

Type and design of prostheses also should be determined. Removable prostheses include denture flange supporting lower lips, and they not only reinforce missing teeth and alveolar bone area but also improve facial profile.

In this case report, two cases in which patients recovered oral function and esthetics with fixed and removable implant prostheses.

Results: In the cases which were difficult to recover function and esthetics using conventional removable prostheses, implant supported prostheses were used for rehabilitation. Regular clinical and radiographic examinations of prostheses and implants were done for these patients. They have been maintained stable for about 10 and 4 years respectively.

Conclusion: In the patients with reconstructed mandible after mandibulectomy due to oral tumor,

implant placement in proper location and establishment of prosthodontic treatment according to clinical conditions can recover oral function and esthetics.

4

Application of Implant-supported Overdenture with Locator Attachment in an Edentulous Patient after Hemimaxillectomy: a Case Report

Chen Cheng, Ren Weihong

Capital Medical University

Purpose: Edentulous patients after hemimaxillectomy always have difficulties in retention and stability when applicated with conventional complete denture, due to the lost of teeth, the reduction of supporting alveolar and neuromuscular disorder. Thus, implant-supported overdentures with Locator attachment are recommended. We report the case of application of implant-supported overdenture with Locator attachment in an edentulous patient after hemimaxillectomy.

Methods: A 61-year-old edentulous man who had been treated with left hemimaxillectomy was submitted to implant-support overdenture with Locator attachment rehabilitation therapy which aimed to restore orofacial form, function and general well being. The definitive maxillary obturator prosthesis was fabricated. Before the procedure of implant surgery, it was turned into implant drilling guide. With the help of implant drilling guide and CT, three implants were placed in his right residual alveolar ridge. After 3 months, three locator implant abutments were placed and the overdenture was made.

Results: This kind of prosthodontics provided the edentulous patient after hemimaxillectomy with greater satisfaction by giving a comfortable and stable prosthesis that provides better function.

Conclusion: This article has described a simple, clinical time saving and more retentive implant-supported overdenture with locator attachment treatment plan for edentulous patient after hemimaxillectomy. The use of three implants with Locator attachments can adequately support an overdenture in cases of edentulous maxillary defect.

Key words: Implant; Locator attachment; Overdenture; Edentulous; Maxillary defect

5

Wang Chen, Guang Hanbin, Sun Yazhou, Hu Jian

Stomatology School of Nanjing Medical University

Purpose: The aim of this study is to evaluate the effect of silicone lining obturator used in early maxillary prostheses.

Methods: Twelve patients with single maxillary defect were randomly divided into two groups. The patients in group A were restored with hard obturator three months after maxillectomy. The patients in group B were treated with silicone lining obturator two weeks after surgery. The retention, oronasal seal (OS) and speech intelligibility (SI) were compared.

Results: The silicone lining obturator had better retention, OS and SI.

Conclusion: The silicone lining obturator is effective in the early functional impairments with single maxillary defects.

Key words: Maxillary defect; Silicone lining; Obturator

6

The Effect of Different Root Canal Internal Surface Treatment on Bond Strength of Quartz Fiber Post

Yan Fei

Xiang Ya Stomatological Hospital, Central South University

Purpose: To investigate the effect of different pretreatments to root canal dentin on micro push-out strength of quartz fiber post to dentin after post space preparation, and to evaluate the bond strength of different regions of the root. So that appropriate pretreatments to root canal dentin can be used for clinical selection and providing a theoretical basis for improvement bond strength of resin cement to root canal dentin.

Methods: Twenty-four bicuspid teeth with single root were collected after extraction and saved in negative twenty degree Celsius physiological saline. One week after endodontic treatment, the post space preparation of all teeth were made, the teeth were assigned into four groups randomly with 8 teeth each. The teeth of four groups were irrigated with distilled water, EDTA gel, 1%NaClO and EDTA gel+1%NaClO for 60s respectively. 2 teeth were obtained from each group and splitted into two pieces. Observed the middle sections' microscopic characteristic of the root canal dentin surface with SEM. Panavia F self-etching resin bonding cement was imported into other teeth's post space according to the instructions. After cementation, the roots were subjected to simulated aging conditions as thermal cycles. The roots were sectioned into slices with 1mm thickness and a micro push-out test was performed on three different sections of each root to measure bond strengths. Test piece following testing was placed under optical microscope to observe the breakage method.

Results: 1.Both EDTA gel and 1%NaClO notably improved the micro push-out strength ($P<0.05$). But no significant difference in bond strength was determined between EDTA gel and 1%NaClO groups ($P>0.05$);2. No significant difference in bond strength was determined between EDTA gel+1%NaClO groups and the control group ($P>0.05$);3. The coronal third of the root resulted in statistically greater bond strengths than the medium third, whose bond strength was significantly greater than the apical third ($P<0.05$).

Conclusion: 1.EDTA gel and 1%NaClO irrigation to post space before bonding could enhance the bonding strength between resin cement and dentin;2. 1%NaClO followed by EDTA gel irrigation to post space before bonding could not enhance the bonding strength between resin cement and dentin;3. Bonding was more predictable at the coronal level of the root.

Key words: Quartz fiber post; Canal surface treatment; Micro push-out test; Bond strength; SEM

7

Post Rhinectomy Rehabilitation by Means of an Epithesis

Bassi F, Bellia E

Prosthodontic Section, Department of Surgical Science, CIR Dental School, Turin, Italy

Purpose: Surgery for cancer leads often to extended tissues losses with major functional and aesthetical limitations. In nasal defects in particular, prosthetic rehabilitation is indicated. This paper aims to present a case report of a traditional rehabilitation with epithesis after total rhinectomy.

Methods: The patient is visited by the dentist 15 days after the cancer surgery for a first impression, taken with a polysulfide or alginate after having blocked out undercuts with gauzes and vaseline. The impression is poured, obtaining a stone cast on which the waxing of the nose is realized. A pre-surgical impression of the physiological shape of the nose is very useful to obtain a more satisfying result and a study of previous pictures of the patients can be also useful to capture shape, dimensions and colour of the part to be realized.

Results: The wax up is tried-in with the patient, paying attention to the adaptation to the soft tissues.

The final epithesis is realized in silicon and can be retained in the right position with just the help of adhesives or, when it is possible, with osteointegrated implants placed in the residual bone around the defect.

Conclusion: The success of the rehabilitation depends on a meticulous study and planning of the rehabilitation, a good interdisciplinary collaboration with oncologists and surgeons, but also a good communication between patient and operator.

Key words: Rhinectomy; Epithesis

8

Immediate Implant-retained Prosthesis Following Radical Maxillectomy

Liao Guiqing

Hospital of Stomatology, Guanghua School of Stomatology, Sun Yat-sen University

Purpose: The maxillary defect after tumor resection typically involves the mucosal defect and the midface osseous framework damaged. Reconstruction of this defect remains a considerable challenge because the 3-dimentional architecture of midface serves both function and aesthetic role. This article describes the maxillofacial rehabilitation of a patient diagnosed with recurrence ameloblastoma.

Methods: The surgery consisted of a large amount of maxillary bone and soft tissue resection. During the surgical healing, zygoma and nasal implants were inserted in a two-step procedure. The immediate maxillary prostheses were installed and fixed by a titanium framework. With the bone and soft tissue remodeling, the immediate maxillary prostheses were replaced by a new one at post-operation 3 months. 6 months after operation, the second stage of implant procedures were carried out. The ultimately maxillary prostheses were fixed by the titanium framework.

Results: After 2 years follow-up, no recurrences were observed. The patient have a good result in aesthetic, functional, stability, and did not complaint any discomfort. Tissues around implants were in good health, and the prostheses remained well-fitted. The patient was extremely satisfied with the final result.

Conclusion: The immediate implant-retained prostheses are well accepted by the patient, improving comfort and safety during function while recovering her esthetic appearance.

Key words: Immediate; Implant-retained; Prostheses; Maxillary defect

9

Microporous Pattern Fabricated by Microelectromechanical Systems Improved Fibroblast Functionalities on Titanium Surface

Wei Hongbo, Bai Shizhu, Zhao Yimin

Department of Oral Implant, School of Stomatology, the Fourth Military Medical University

Purpose: The fibroblasts, which play an important role in the biologic seal formation and maintaining, determine the long-term success of percutaneous implants. This study aims to evaluate the effect of precisely designed microporous structures manufactured by MEMS on fibroblast functionalities for possible application in the implant percutaneous part.

Methods: Here in well-defined microporous structures with micropore diameters of 10-60 μm were fabricated by microelectromechanical systems and their influence on the fibroblast functionalities was observed. A modified Bosch process was used to manufacture the precisely designed microporous structure by MEMS. Fibroblast functionalities such as cell adhesion, cell proliferation, fluorescent

staining of cytoskeletal actin, fibronectin secretion were assayed.

Results: 1. The six microporous structures with highly ordered and vertically aligned micropores of different diameters of 10 μm, 20 μm, 30 μm, 40 μm, 50 μm, and 60 μm were fabricated by MEMS. The micropores on all the substrates were about 10 μm deep. The titanium film was deposited uniformly on the substrates.2. There was no statistical significance for the adherent fibroblast numbers among the six microporous structures after 4 hours of culture.3. The microporous structures with micropore diameters of 40 and 50 μm induced significantly better cell proliferation than the other structures.4. From hour 4 to day 5, the microporous structures with micropore diameters of 10-60 μm influenced the fibroblast functionalities and those of 40 and 50 μm improved the viability, spread, actin stress fiber organization5. At days 7 the fibronectin amounts were much higher on the microporous structures with micropore diameters of 40 and 50 μm

Conclusion: Well-defined microporous structures with micropore diameters of 10-60 μm can be fabricated by microelectromechanical systems, which provide a good platform to study the interaction of fibroblasts with biomaterial topography. The microporous structures with different micropore diameters of 10-60 μm do not induce obvious influence in the initial adherent fibroblast number; however those of 40 and 50 μm significantly improve the fibroblast functionalities including spread, actin stress fiber organization, proliferation and ECM secretion. The microporous structures with micropore diameters of 40-50 μm show great potential for the implant percutaneous part application.

Key words: Fibroblasts; Microelectromechanical systems; Percutaneous implant; Microporous structure; Surface modification

10

Changes in Serum of Bone Regeneration of Antibacterial Nanocomposite Membrane in vivo

Cui Huang,ongbing Liao; Anchun Mo; Lichong Lan; Muying Liao
Stomatological Hospital of Guangxi Medical University

Purpose: The objective of our study is to observe the changes in serum of rats so as to evaluate the effect of four kinds of guided bone regeneration (GBR) membranes used in the skull defects of rats.

Methods: 45 adult male SD rats were randomly divided into five groups, 9 rats in each group. Then two 5mm trephined defects were produced in the skull of each rat. In the four experimental groups, one defect was covered by four different kinds of GBR membranes with the other side as blank control. The fifth group was used as control group while the defects filled with autogenous blood only. After 1, 4, 8 weeks, the blood samples of rats were taken. The serum were separated and tested, the results showed us the different changes in the alkaline phosphatase (ALP) and calcium concentrations.

Results: Except the blank group ,the rat serum alkaline phosphatase reached the highest values in approximately 4 and 8 weeks, the group whose defects covered by the Ag-nHA-nTiO2/PA66 membrane was the highest, while the blank group showed the opposite trend. As the concentration of calcium ions, the value of experimental group reached the highest point in 4 weeks and decreased slightly in 8 weeks. There was a little increase of calcium ion concentration in the blank group.

Conclusion: The results indicated that four kinds of GBR membranes had excellent biocompatibility in 8 weeks in vivo. The Ag-nHA-nTiO2/PA66 membrane has a positive effect on newly formed bone.

Key words: Guided bone regeneration (GBR); Polyamide; Nano-hydroxyapatite; Alkaline phosphatase (ALP)

11

Osseointegrated Implants Supported Bar and O-ring Combination Prosthesis post Mandibular Resection

Sharad Gupta

MDS, FICD, FICOI, FAAMP

Purpose: Rehabilitation of hemimandibulectomy post cancer resection is a challenge. The immediate concern is trismus which is surmounted upon by the rotation and mandibular deviation to the resected side. The prosthetic rehabilitation is further complicated if the patient is completely edntulous. The purpose of the case report was to utilize the remaining alveolar bone following partial mandibular resection by osseointegrated implant supported prosthesis so as to enhance patient's quality of life.

Methods: Three endosseous implants were placed in the remaining alveolus involving anterior and left mandible following partial mandibulectomy and radiation therapy 8 years back. The implants were placed in a manner so as to fabricate a cast milled bar anteriorly and o-ring attachment was placed posteriorly so as to act as a vertical support. The configuration permitted PM0 movement and led to increased retention support and patient acceptance. The maxillary denture was fabricated with palatal guidance ramp so as to control deviation and guide the patient in occlusion.

Results: Utilization of osseointegrated implants in the rehabilitation of mandibular resection led to greater patient comfort and acceptance. The prosthesis was unique as it incorporated the bar over anterior implant along with o -ring attachment over the posterior implant. The unique combination of two different attachments led to virtually a PM0 movement of the prosthesis. Maxillary guidance ramp and double row of teeth further added to comfort and chewing efficiency.

Conclusion: Rehabilitation of hemimandibulectomy should aim at controlling mandibular rotation and trismus. Successful utilization of remaining alveolar bone can enhance prosthetic rehabilitation outcomes and patients quality of life.

Key words: Hemimandibulectomy; Osseointegrated implant supported mandibular prosthesis; Mandibular guidance; Bar overdenture; Attachment denture

12

Synthesis and Properties of Sr/CS/G Coatings Fabricated via Electrophoretic Deposition

Ma Kena, Wang Yining, Jiang Tao, Huang Dan

Key Laboratory for Oral Biomedical Engineering of Ministry of Education, School & Hospital of Stomatology, Wuhan University

Purpose: The purpose of this study was to enhance the lifespan of the implants applied in the osteoporosis patients through modifying the surface. Our group has successfully prepared chitosan/gelatin (CS/G) coatings on the titanium surface via electrophoretic deposition (EPD). Strontium represents a new promising candidate to prevent and treat osteoporosis. Here, we explored further to prepare CS/G coatings loaded with strontium via EPD. The physico-chemical properties of Sr/CS/G coatings were respectively observed.

Methods: $SrCl_2$ were added into the CS/G solutions. Then the Sr/CS/G coatings were made via EPD as CS/G coatings. Surface morphology of the coatings was observed by scanning electron microscope. The element analysis of the coatings was observed with EDS. X-ray diffraction pattern (XRD) of the coatings was measured using an X-ray Diffractometer. The CS/G solution and Sr/CS/G solution were respectively observed with TEM. MC3T3-E1 cells were seeded on the Sr/CS/G coatings and their morphology was observed by SEM.

Results: A lot of particles existed on the surface of Sr/CS/G coatings with a diameter of 1-4μm and the particles were made up of smaller microspheres and these microspheres were packed with a layer of organic materials. The results of EDS indicated that Sr/CS/G coatings included C、O、Cl、Sr

elements. The atom percentages of Cl and Sr in the non-particle areas were 7.25% and 3.5% and the atom percentages of Cl and Sr in the particle areas were 2.52% and 8.77%.. According to the analysis of matter phase of XRD patterns of, it is judged that the diffraction peaks of $SrCl_2 \cdot 6H_2O$and $SrCO_3$ existed in the XRD patterns of Sr/CS/G coatings. The results of Sr^{2+} release from the Sr/CS/G coatings into PBS showed Sr^{2+} could be continually released within 1 month. The images of TEM indicated that nanoparticles were formed in the Sr/CS/G solution with a diameter of 200-400nm. The nanoparticles appeared like core-shell structure. In addition, MC3T3-E1 cells could grow and spread more widely on the Sr/CS/G coatings observed with SEM.

Conclusion: Sr/CS/G coating could be successfully fabricated on the titanium surface via EPD through adding strontium chloride into the CS/G solution. Such coating may be a promising candidate for improving the success rate of implants applied in the osteoporosis patients.

Key words: Implant; Electrophoretic deposition; Strontium; Osteoporosis

13

Application of Obturator Combining Casting Frame in Cystic Lesions of the Jaws

Hu Jian, Du Yifei, Sun Yazhou, Zhang Feimin

Stomatology School of Nanjing Medical University

Purpose: To evaluate the effect of obturator combining casting frame on cystic lesions of the jaws.

Methods: After curing with Marsupialization, twelve patients with cystic lesions of the jaws were randomly divided into control group (A, n=6) and test group (B, n=6). A were treated with obturator combining casting frame, those in group B with obturator combining acrylic frame. Patients were followed up at half year and one year after treatment. Clinic situation and panoramic radiographs were measured respectively. These indexes of examination include facial deformity, reduction in cyst volume, plaque index (PI) and patient satisfaction (PS).

Results: One year after treatment, Over 80% reduction in cyst volume together with bone healing occurred in all case of two groups. The facial deformity o f all patients was resolved. The obturator combining casting frame obtained higher PS and lower PI than that B group.

Conclusion: The obturator combining casting frame and resin frame were the effective way in the treatment of cystic lesions of the jaws. Therefore, the obturator combining casting frame was well received by patients, with which there was more slight interference on periodontal tissue than with the obturator combining resin frame.

Key words: Obturator; Casting frame; Resin frame; Marsupialization; Odontogenic cysts

14

Using the Folded Fibula Flap and Dental Implants to Repair Mandibular Defects at the Same Period

Li Ming, Wu Yunong, Jiang Hongbing, Xing Shuzhong, Tao Zhenjiang

Stomatology School of Nanjing Medical University

Purpose: To summarize the advantages using the folded fibula flap and dental implants to repair mandibular defects at the same period, and observe its clinical efficacy.

Methods: 28 cases were collected from January 2001 to December 2012, using the folded fibula flap and dental implants to repair mandibular defects at the same period in the Affiliated Stomatological Hospital of Nanjing Medical University. According to the defects location and characteristics, fibula flaps were folded into a "double-barreled" type, with a total of 76 implants implanted. Dental teeth

were fixed after 6-12 months.

Results: Of 28 cases of fibular flap, 26 cases survived (survival rate 92.86%), 2 flaps removed because of postoperative necrosis. 68 dental implants played a good function after 2 years (2-year survival rate 89.47%). Postoperative X-ray showed a high degree of satisfaction with the reconstruction of the mandible, the fibula flap and contralateral mandibular stump healed well and implants got osseointegration. After 2-5 years follow up, the patients have no serious complications, and have satisfied function and good shape.

Conclusion: Using folded fibula flap and dental implants to repair mandibular defects at the same time can achieve satisfactory form and function, it is a good choice for the hospital that can do it.

Key words: Fibular osteomyocutaneous flap; Dental implants; Mandibular defect

15

Clinical Evaluation of Prostheses Retained by Tooth-implant and Natural Teeth Combined with Extracoronal Magnetic Attachments for Unilateral Mandibular Defects

Liu Xiaofang, Song Guangbao, Zhu Xiaobin, Shi Yong, Xie Liben, Gao Limin, Xue Guochu

Guangdong Provincial Stomatological Hospital, Affiliated Stomatological Hospital of Southern Medical University

Purpose: To explore the clinical effect of unilateral mandibular defects repaired by Tooth-implant and natural teeth combined with extracoronal magnetic attachments prostheses.

Methods: In 5 cases of patients with unilateral mandibular defects as a result of mandibular tumor, Tooth-implant and natural teeth combined with extracoronal magnetic attachments prostheses were applied to repair the defect of mandible and the loosed teeth.

Results: The facial contour and the functions of mastication, deglutition, suck, pronunciation were obviously improved after wearing the prostheses.

Conclusion: The Tooth-implant and natural teeth combined with extracoronal magnetic attachments prostheses can effectively improve occlusal function and quality of life of patients with unilateral mandibular defects.

16

To Reconstruct Attached Soft Tissue around Dental Implants by Acelluar Dermal Matrix Grafts and Resin Splint

Liu Changying, Geng Wei, Li Jun, Ma Pan, Tan Baosheng

Department of Dental Implantology Centre, School of Stomatology, Capital Medical University

Purpose: The purpose of this study was to recommend a new method using acellular dermal matrix graft and resin splint to reconstruct the attached soft tissue around dental implants in patients with maxillofacial defects.

Methods: Total 8 patients (3male and 5 female patients) diagnosed with maxillofacial defects and dentition defects caused by tumors, fractures or edentulous jaw, were selected for this study. Dental implants were routinely implanted at the edentulous area. Acellular dermal matrix heterografts and resin splint were used to increase the attached soft tissue. The width of attached gingiva in the labial or buccal surface at edentulous area was measured before surgical procedures and after the completion of superstructures. Paired t-test was applied to assess the change of quantitative variables. All tests were

2-tailed, and $P < .05$ was considered statistically significant.

Results: The dense connective tissue around implants can be reconstructed one month after the completion of surgical procedures, and the epithelial cuff around the implant neck established very well. The width of attached gingival tissue in the patients increased significantly from a mean of 0.61±0.75mm to 6.25±1.04 mm.

Conclusion: The acellular dermal matrix graft could be used to increase the attached gingiva around dental implants in these patients with maxillofacial defects. The resin splint could facilitate the healing of graft.

Key words: Peri-implant attached soft tissue; Implant; Acellular dermal matrix; Maxillofacial defect

17

The Pickup Technique Combined with Surgical Guide Template on the Immediate Fixed Restoration in the Rehabilitation of Complete Edentulous Jaws

Ma Pan, Geng Wei, Li Jun, Tan Baosheng, Liu Changying,

Department of Dental Implantology Centre, School of Stomatology, Capital Medical University

Purpose: To evaluate the preliminary clinical results of surgical guide template and the pickup technique on the immediate fixed restoration in the rehabilitation of complete edentulous jaws.

Methods: This clinical study included 10 patients treated from February 2009 to February 2013 in Beijing Stomatological Hospital of Capital Medical University. Sixty-four implants were placed supporting ten prefabricated fixed complete dentures. Recall examinations included survival of implants, clinical function of prostheses and marginal bone resorption. The deviations between the actual placed and the planned implants were measured in 9 cases with 56 implants. The pickup technique and the routine methods on the immediate fixed restoration were compared. The satisfaction was assessed between using the traditional denture and the implant-supported fixed dentures.

Results: ① Sixty-four implants were successfully guided and placed, on which 10 prostheses were immediately fixed. 2 implants in one patient were lost at 2 months after immediate loading making the implant survival rate 96.875%. During following observation time the implants and restorations were of good immobility and stability. ② An average angular deviation of 56 implants was 3.12°as compared with the planning, while the mean linear deviation was 1.04mm at the hex , 1.53mm at the tip. ③ Compared with conventional methods, the pickup technique is the more obvious advantages for immediate load restoration in the rehabilitation of complete edentulous jaws. ④Compared with traditional dentures, the satisfaction degree of the implant-supported fixed dentures was significantly higher in pronunciation, retention, comfort and mastication ($P<0.05$).

Conclusion: The preliminary clinical results showed computer-guided surgery protocol and the pickup technique was predictable and satisfying for edentulous Chinese patients.

Key words: Dental implantation; Edentulous jaw; Immediate loading; Computer-guided surgery; Surgical template; the pickup technique

18

Functional Reconstruction of Maxillary Defect with Zygomatic and Conventional Dental Implants after Tumor Resection

Wu Yiqun, Huang Wei, Wang Feng, Zhang Zhiyong, Zhang Chenping, Sun Jian, Zhang Zhiyuan

Department of Oral and Craniofacial Implant, Shanghai Ninth People's Hospital, School of Medicine, Shanghai Jiao Tong University

Purpose: Functional reconstruction of maxillary defect due to tumor resection poses a challenging problem in maxillofacial surgery. This study was aimed to evaluate the clinical status and success rates of zygomatic and dental implants for orofacial reconstruction following ablation of tumors. Patient satisfaction after maxillary reconstruction was also assessed with regard to function and comfort.

Methods: Over a 6-year period, patients with maxillary tumors underwent resection with either immediate or delayed bone grafting reconstruction combined with implant supported fixed prostheses or with implant supported obturators. The patients received 88 implants in total, including 9 zygomatic and 79 conventional implants, for maxillary rehabilitation of the defective areas.

Results: Six patients were restored with implant-supported obturators and 18 patients were rehabilitated with implant-supported fixed prostheses. Patient follow-up was started at the point of the implant loading. The average follow-up was 99.1 months (range: 18–137 months). One patient died after 18 months of follow-up due to tumor recurrence, and two patients were lost to follow-up after 3 years of observation. Ten conventional dental implants were removed due to peri-implantitis. The cumulative survival and success rates of the implants were 88.6 and 86.3%, respectively. Most patients treated in the study were fully satisfied with their facial contours, prosthesis comfort, pronunciation and prosthesis function.

Conclusion: This study demonstrated that rehabilitation of maxillary defects following tumor resection with autogenous bone grafting combined with implant supported fixed prostheses or implant supported obturators is successful and is associated with high patient satisfaction. Oral function can be well restored with dental implants for patients with maxillary defects.

Key words: Conventional implant; Maxillary defects; Prosthesis; Tumor; Zygomatic implant

19

Reconstructed the Completed Mandible Defect with Bilateral Fibula Grafts and Dental Implantation

Liao Guiqing, Su Yuxiong, Zheng Guangsen, Liang Yujie, Zhang Sien, Neungkhotapajjai

Hospital of Stomatology, Guanghua School of Stomatology, Sun Yat-sen University

Purpose: This report described the operation and reconstruction of a complete mandible defect due to recurrent osteosarcoma.

Methods: Computer-aided mandibular reconstruction involves three steps: virtual surgical planning, rapid-prototyping procedures for the design and manufacture of the customised surgical device and surgery. A CAD/CAM surgical guide was projected to aid the repositioning of fibula bone segments in the patients. After 3 years followed up, the osteosarcoma displayed no recurrence. After careful assessment of the bilateral fibula grafts, the All-on-four implant skill was use to gain the dental implantation.

Results: Follow up 2 years, the patient was satisfied with the result in facial esthetics and chewing function from the implant-supported denture. Tissues around implants were in good health, and the prostheses remained well-fitted. The patient was extremely satisfied with the final result.

Conclusion: All-on-four dental implantation supporting by bilateral fibula grafts, is suitable and safety for the patient of complete mandible defect. It gains esthetic appearance and good function.

20

Efficacy of Implant-supported Maxillofacial Prosthetics

Neal Garrett, John Beumer III, Scott Recksiedler

UCLA Dental/Medical

Purpose: The primary aim of this longitudinal prospective study has been to determine whether conventional or implant supported dental prosthesis and current surgical reconstructive procedures restore patient's oral function and quality of life to their status prior to the ablative oral cancer surgery. The study was designed to compare conventional dental (CD) prosthesis and implant retained dental (ID) prosthesis in subjects scheduled to undergo a maxillectomy. Hypothesis included: (1) the CD restores oral functions and perceptions to pre-cancer levels; (2) the ID restores oral functions and perceptions to pre-cancer surgery levels; and (3) the CD and ID are equally effective in restoring oral functions and perceptions. The primary outcome variable was defined as masticatory performance.

Methods: A total of 20 participants receiving a partial or total maxillectomy were enrolled in the study. Detailed clinical evaluations and a series of subjective assessments and objective oral functional tests were made at entry. The same measurements were repeated after post-surgical recovery with immediate surgical obturation, definitive conventional dental prosthesis, and definitive implant retained dental prosthesis.

Results: Mean age of patient was 69 years. Out of the 20 patients' enrolled 14 were diagnosed with primary tumors and 6 with recurrent tumors. All subjects were required to be edentulous as an inclusion criterion. Masticatory performances at entry were less than half of that for an average denture wearer (35%) on both the defect (5.5%) and the non-defect (10.8%) sides. This extreme impairment was maintained after surgery. After restoration with the CD, slight increases in performance to 11.5% and 13.3% were seen for the defect and non-defect side respectively. No additional improvement was seen with the implant retained prosthesis.

Conclusion: No difference was seen in performance scores between CD and ID.

Key words: Dental Implants; Maxillary Defects; Obturator; Maxillectomy

21

Use of Implants to Retain Facial Prostheses: the UCLA Experience.

Nicholas Goetz

Division of Advanced Prosthodontics, School of Dentistry, UCLA

Purpose: Present the UCLA experience with these devices as well as describe how the design of the retention apparatus has evolved through the years.

Methods: UCLA clinical experience & Literature review.

Results: Osseointegrated implants have been used effectively during the past 30 years. Auricular & Nasal implant supported prostheses have proven to have good success, while orbital implants have proven to have a lower overall implant success rate.

Conclusion: Implant restorations are an integral part of the present as well as the future of maxillofacial prosthetics Implant retained prostheses have shown a higher survival for auricular defects, with the lowest survival found in orbital defects. Implant retained prostheses in irradiated patients have shown as lower survival rate. Potential increase in survival rate for orbital & nasal prostheses may be found in the use of intra-oral longer implants.

Key words: Implants; Craniofacial; Prostheses; Retention

22

Pulsed Electromagnetic Fields Effects on Swelling and Pain after Implant Surgery: a Double-blind, Randomized Study

Paolo Pera

University of Genoa

Purpose: The aim of this split-mouth, double-blind, randomized study is to evaluate if pulsed electromagnetic fields treatment can improve swelling and pain management after a full-arch immediate loading implant surgery.

Methods: Ten patients were selected for the study. Each patient received four implants in the upper or lower jaw using distal tilted implant and underwent a full-arch immediate loading rehabilitation.

After surgery two pulsed electromagnetic fields (PEMF) devices were applied on the right and the left cheek of each patient. Randomly one PEMF device was switched on (test side), applying the other one as a placebo (control side).

48 hours after surgery clinicians estimated the postoperative swelling through photographic documentation, comparing the condition prior and after surgery, while pain was assessed using a verbal rating scale. Patient's comfort degree in relation to PEMF devices was analyzed by questionnaires using a numerical rating scale.

Results: No differences were observed between the test side and the control one as regards swelling and pain. Most of patients did not present swelling or pain 48 hours after surgery, without distinction between PEMF device activated and not. Variable outcomes emerged from comfort evaluation.

Conclusion: Within the limits of this study, PEMF does not reduce postoperative swelling and pain after immediate loading implant surgery.

Key words: Immediate loading; Implant surgery; Pulsed electromagnetic field (PEMF); Postoperative swelling; Pain

23

Mandibular Defect Reconstruction with Fibula Flap and Non-vascularized Fibula Bone

Shan Xiaofeng, Liang Jie, Lu Xuguang, Zhang Lei, Cai Zhigang

Department of Oral and Maxillofacial Surgery, School and Hospital of Stomatology, Peking University，Beijing, China

Purpose: The vascularized free fibula flap has become the most popular reconstruction method for segmental mandibular defect because of adequate bone graft length and acceptance of dental implants. While because of the height discrepancy between the native mandible and transplanted fibula, it is difficult to wear conventional dentures or do osseointegrated implants. The purpose of this study was to research if mandibular defect could be reconstructed with fibula flap and non-vascularized fibula bone to get a better contour and high neo-alveolar bone.

Methods: 12 patients received mandible reconstruction with fibula flap and non-vascularized fibula bone. In the operation, fibula flap was used to reconstruct the mandible as the inferior portion or superior alveolar portion. The non-vascularized fibula bone was fixed to the fibula flap with titanium plate or screws to augment the height of fibula bone. The periosteum between vascularized and non-vascularized fibula was removed to get a better attachment between vascularized and non-vascularized fibula.

Results: The operation proceeded very smoothly in all 12 cases. The follow up time was 1 month to 24 months. All patients got a good appearance, and the bone height improved 5 to 18mm compared with conventional one-strut type technique. In all 12 cases, non-vascularized fibula was used to reconstruct alveolar bone in 4 cases, 1case suffered infection in 1 month after operation; non-vascularized fibula

was used to recover the low border of mandible in 8 cases, 1 case suffered infection in 1 week after operation. Two patient received operation to remove titanium plate in 6 months after operation, bone coalescence was found between vascularized and non-vascularized fibula. Non-vascularized bone resorption was obviously. The space in non-vascularized fibula bone was filled with granulation tissue.

Conclusion: It is a good choice to reconstruct mandibular defect with fibula flap and non-vascularized fibula bone to get a better contour and high neo-alveolar bone. And we prefer to use the vascularized fibula bone to reconstruct the superior portion of mandible, and use non-vascularized fibula bone to reconstruct the inferior portion of mandible.

Key words: Mandible defect; Fibula flap; Non-vacularized fibula

24

4 Implant-supported Bridge for Mandibular Defects with Vascularized Fibular Osteomyocutaneous Flap

Song Guangbao, Liu Xiaofang, Shi Yong, Wang Xianfeng, Gao Limin, Xie Liben

Guangdong Provincial Stomatological Hospital, Affiliated Stomatological Hospital of Southern Medical University

Purpose: The success of mandibular tissue supported implant prostheses varies in the literature, and the ideal protocol may be elusive from given the numerous studies. This clinic report is to study the reliability of 4 implant-supported bridge for oromandibular defects with vascularized fibular osteomyocutaneous flap.

Methods: 3 patients with mandibular ameloblastoma were operated by Subtotal of mandible and reconstructed with vascularized fibular osteomyocutaneous flap.6 months later the new mandible were receipted 4 implants, and reconstructed with full bridge after 3 months healing periods.

Results: 3 patients were successful to complete 4 implant-supported prosthesis, and long term effect was stable after 3-4 years.

Conclusion: The study indicates that the 4-implant supported prosthesis provides predictable results for oromandibular defects with vascularized fibular osteomyocutaneous flap.

25

The Effectiveness of Implant Overdenture Treatment for the Severe Bone Resorption case

Tetsuo Ohyama, Hiroyasu Yasuda, Satomi Tadokoro, Tomohiko Ishigami

Nihon University School of Dentistry

Purpose: In mandibular edentulous with severe bone resorption cases, improvement in retention and stability of dentures can be achieved by fabrication of implant assisted overdentures using two abutments. In this study, using three-dimensional finite element analysis, indications of implants and denture behavior depending upon differences in the morphology of residual ridges were compared and evaluated.

Methods: Three models that simulated treatment using complete dentures were prepared, including a normal mandibular edentulous case, a mandibular edentulous case with severe bone resorption in the left posterior region and a mandibular edentulous case with severe bilateral bone resorption in the posterior regions. In addition, models simulating implant placements in both canine areas for overdentures were prepared for each model, resulting in a total of six different models.

Results: The implant overdentures, as compared with the conventional dentures, denture movement was very small. It was found that dentures tended to shift toward the side with severe bone resorption.

Conclusion: In cases with implant placement, retention and stability of dentures improved since denture movements were limited by implants.

Key words: Implant over denture; Sever bone resorption; Finite element analysis

26

The Effect of Different Doses of Radiation on the Rat Osteoblasts in Vitro

Wang Ying, Ren Weihong

Department of Prosthodotics, Capital Medical University School of Stomatology

Purpose: The implant-retained obturator prosthesis is the only way to restore the maxillary defects and edentulous jaw. But there is a huge risk for patients who received the radiotherapy in this plan. This risk refers to the harmful bone transplantation, as well as the implant failure. The reason is that radiation not only can kill cancer cells but also has bad influence on bone tissue. To study the radiation damage, it is considered that the model in vitro is better than the model in vivo. The cultured osteoblasts were irradiated with X-ray to establish the irradiated model in this study. The effects of radiation of different doses on the osteoblasts were observed, in order to illustrate the damage of the osteoblasts with radiation of different doses, to provide laboratory evidence for restoration of the implant-retained obturator prosthesis for patients who received the radiotherapy.

Method: The cultured osteoblasts were irradiated with X-ray at2, 4, 6 and 8Gy respectively to establish the irradiated model. The changes in morphology, proliferation, alkaline phosphatase (ALP) activity and mineralization, osteocalcin level and the mRNA levels of intracellular ALP and COL Ⅰ were investigated.

Results: All the above mentioned indices were significantly decreased after irradiation. There was a close relationship between the enhanced impairment and the increase of irradiation dosages. Mineralization capacity presented dual phase change (promoting effect of 2 Gy and inhibition of 8 Gy), the mRNA levels of intracellular ALP and COL Ⅰ significantly decreased.

Conclusion: The radiation injury of the osteoblasts is mainly due to the impairment of the proliferation, physiological function. But their sensitivity to the ionizing radiation is different.The restoration of implant-retained obturator prosthesis for patients who received high dose of radiation should be avoided.

27

Study of Coralline Hydroxyapatite Blocks Used in Reconstructing Alveolar Bone Height in Posterior Mandible

Xu Shulan

Guangdong Provincial Stomatology Hospital

Purpose: Comparing coralline hydroxyapatite blocks to autogenous block bone for clinical effects of bone height augmentation of posterior mandible via onlay grafting, the topic discusses clinical operation feasibility and healing of coralline hydroxyapatite blocks through wedging force.

Methods: Choose 37 patients (male 20, female 17) with partly edentulous posterior mandible receiving dental implants in implantation center of Guangdong province stomatological hospital from 2010-01 to 2014-01. These patients were randomly divided into two groups. 19 patients (group A) were treated with coralline hydroxyapatite blocks via wedging force of box-shaped hole, while 18 patients were treated by means of autogenous bone block through titanium screws. Conventional placement of dental implants was performed after bone augmentation. (1) Panoramic radiographs were taken preoperatively, immediately after the bone grafting procedure, at the time of implant placement, at the time of second-

term surgery, and annually after prosthetic rehabilitation. Compare absorption of bone height between group A and group B in corresponding periods. Mann-Whitney test was computed and P<.05 was considered significant. (2) Using the Mann-Whitney test, based on marginal bone level L2 Immediately after implants placement, marginal bone levels of implants were calculated immediately after prosthetic completion (T3), one and two years thereafter (T4 and T5). The difference between marginal bone levels was recorded as L3-L2, L4-L2 and L5-L2. Using the Mann-Whitney test, P less than 0.05 was statistically significant.

Results: (1) Graft success rate and statistical analysis between group A and group B: of 19 patients (group A) treated with 39 pieces of coralline hydroxyapatite blocks, 2 patients (containing 4 pieces of coralline hydroxyapatite blocks) failed to attain bone height augmentation, because one case had poor blood supply in recipient area, and another had poor retention on account of osteoporosis. Graft success rate was 90% in group A. Of 18 patients (group B), one wound dehisced and bone graft failed, resulting in success rate of 94%. Through chi-square test, there was no statistically significant difference for graft success rate between the two groups（P<0.05）.(2) Comparison of the stability of increased bone height and statistical analysis between group A and group B: after vertical onlay bone graft, vertical Bone resorption from graft placement to implant placement was significantly lower in group A（P=0.001）;vertical Bone resorption from graft placement to prosthetic rehabilitation was significantly lower in group A（P=0.001）; vertical Bone resorption from graft placement to 1 year after prosthetic rehabilitation was significantly lower in group A （P=0.002）;vertical Bone resorption from graft placement to 2 years after prosthetic rehabilitation was significantly lower in group A（P=0.012）. Peri-implant soft tissue health of all patients is good, and no patients had significant symptoms of peri-implantitis.(3) Peri-implant bone resorption between A and B groups: based on implant marginal bone level (L2), peri-implant bone resorption (L3-L2) in group A was less than that in group B at prosthetic completion, being statistically significant（P=0.028）; Group A was less than group B for peri-implant bone resorption at one and two years after prosthetic completion（P=0.025 and P=0.013）. Peri-implant bone resorption among three phases in group A and B was significantly different, with peri-implant bone resorption the minimum half of year after bone grafting and that the maximum 2 years after prosthetic completion.

Conclusion: 1. Coralline hydroxyapatite blocks had good operation feasibility and reliable clinical-retention effect via wedging force of box-shaped hole in edentulous posterior mandible.2. Both coralline hydroxyapatite blocks and autogenous bone can effectively recover posterior mandibular vertical height and the success rates are not statistically different. The stability of bone height increased by means of coralline hydroxyapatite blocks is favorable.

28

Review of Implant Outcomes on Fibula Free-flap Reconstruction for the Resected Mandible

Xuan Yue

Advanced Prosthodontics Resident, UCLA

Mandibular reconstruction by vascularized free fibula flap has become the most popular reconstruction method. It has dramatically broadened the possibilities for dental reconstruction and improved the quality of life of these patients undergone mandible resection surgery. Traditionally, a conventional prosthesis can be used for dental rehabilitation. However the function it provides is limited. With the introduction of osseointegrated implants in these grafted sites, the patient's function and esthetics can be greatly enhanced. The implant placement technique used in fibula flap is similar to the technique utilized in a non-resected mandible. While the success rate of these implants can be favorable, there is a concern on the long-term success once these are restored with a prosthesis. The aim of this review is to explore various methods of implant placement protocols for an implant-supported prosthesis after fibula free-flap reconstruction. These techniques along with their advantages, limitations and survival outcome of these implants will be presented.

29

Effect of Pore Size and Porosity on Cytocompatibility of Porous NiTi Alloys

Wang YiChen, Liu Shuai, Zhao Ke

Hospital of Stomatology, Guanghua School of Stomatology, Sun Yat-sen University

Purpose: To study the effect of pore size and porosity on the mechanical and biological properties of porous NiTi alloy for orthopedic applications, and seeking the optimal pore size in terms of the cytocompatibility.

Methods: Five porous NiTi alloy samples were fabricated with NH4HCO3 powder as a temporary space-holder and pore-size regulator of specified amounts. Microstructural surface characteristics and pore morphology were visualized using metallographic microscopy. Three groups of porous NiTi alloy were selected by compressive and three-point bending tests using a universal testing machine. hFOB 1.19 cells were cultured in the three groups, while commercial pure Ti (cp Ti) and tissue-cultured plates (TCPs) were used as control. Cytocompatibility was examined by cell adhesion, cell proliferation, alkaline phosphatase and scanning electron microscope.

Results: Porous NiTi alloy exhibited a lower Young's modulus (2.0-0.8 GPa). Its compressive strength decreased gradually with increasing MPS (108.8–56.2 MPa; $p < 0.05$) and its Fracture strength was 64.6-41.6 MPa ($p<0.05$). Cells grew and spread well on all porous NiTi alloy samples. Cells attached more strongly on cp Ti and TCPs than on all porous NiTi alloy samples ($p < 0.05$). Cell adhesion on porous NiTi alloy was correlated negatively to MPS (277.2–566.5 μm; $p<0.05$). More cells proliferated on pure Ti and TCP than on all porous NiTi alloy samples ($p<0.05$). Cellular ALP activity on all porous NiTi alloy samples was higher than on cp Ti ($p<0.05$).

Conclusion: The mechanical properties of the porous NiTi alloy can be well adjusted by using NH4HCO3 with different amounts and particle sizes. The porous NiTi with optimized pore size could be a potential orthopedic material.

30

Survival, Functions, and Complications of Oral Implants Placed in Bone Flaps in Jaws Rehabilitation-a Systematic Review

Zhang Lei

Department of Prosthodontics, School of Stomatology, Peking University

Purpose: This systematic review attempted to answer the focused questions: "What is the survival rate of implants placed in bone flaps in jaws rehabilitation?" and "What are the function gains and the most common complications related to these implants?"

Methods: An electronic search without date or language restrictions was undertaken in PubMed and EMBASE from the earliest available dates through July 2014. Titles and abstracts from the results were read by two examiners for identifying studies that meet the inclusion criteria. Subsequently, the reference lists of the relevant publications were searched. Descriptive statistics were utilized to report all the data related to the survival rate of implants placed in bone flaps in jaws rehabilitation, the function gains and the complications related to these implants.

Results: A total of 13 studies were included for systematic review without repetition. The follow-up period ranged from 1 to 10 years. Within the limitation of available studies, the survival rate of implants placed in bone flaps in jaws rehabilitation ranges from 79.9% to 100%. However, available studies investigating long-term outcomes seemed scarce. The most common complications related to these implants reported were peri-implant bone resorption and peri-implant soft tissue proliferation. Other complications reported included postoperative infection, peri-implantitis and screws fracture. Factors that affected the suvival rate were reported as follows: types of bone defect and bone flap,

specific peri-implant conditions, immediate or delayed placement of the implants, tumor recurrence, radiotherapy, surgery-related factors, lack of patient cooperation, poor oral hygiene, patient's age and gender, etc. Despite some persistent soft tissue problems and implant loss, most patients reached a satisfactory functional and esthetic outcome. Implant-supported dental prosthetic rehabilitation in reconstructed jaws improved the quality of life in terms of speech, nutrition, oral competence and facial appearance.

Conclusion: Implants placed in bone flaps in jaws rehabilitation following ablation for tumors, osteoradionecrosis or chronic osteomyelitis were demonstrated to be a reliable technique. But considering multiple influencing factors of jaws rehabilitation outcome, it is suggested that randomized controlled clinical trials and longer clinical studies should be implemented in this area.

Key words: Implants; Bone flaps; Maxillary rehabilitation; Mandibular rehabilitation; Survival rate; Complications

31

A Clinical Evaluation of the Implantodontical Obturator Prostheses for Maxillary Defects

Zheng Jie, Jiang Hua, Wang Juncheng, Li Yanan

Department of Stomatology, Chinese PLA General Hospital

Purpose: To evaluate the clinical effectiveness of rehabilitation with implantodontical maxillary obturator prostheses in individuals with maxillary defect.

Methods: The masticatory efficiency and speech intelligibility of 15 patients with maxillary defects were measured postoperatively, with or without prostheses.

Results: Significant differences existed both in masticatory efficiency and speech intelligibility for l5 individuals. The masticatory efficiency and speech intelligibility ranged between 32. 5% and 75. 0% (mean and standard deviations: 56. 0% ±12. 5%) and between 14. 3% and 41. 0% (mean and standard deviations: 23. 2% ±7. 4%) respectively without prostheses. While obturated by prostheses they were between 59. 0% and 85. 0% (mean and standard deviations: 79. 0% ±11. 3%) and between 72. 5% and 98. 7% (mean and standard deviations: 81. 8% ±9. 4%) respectively.

Conclusion: The prosthodontic rehabilitation can significantly improve the masticatory efficiency and speech intelligibility of patients with maxillary defects.

32

Mussel Adhesive Proteins/ Platelet-rich Plasma Composite-Coated Titanium Surfaces Increased Functionality of Dermal Fibroblasts

Wang Zhongshan，Feng Zhihong，Wu Guofeng, Bai Shizhu, Dong Yan, Qin Haiyan, Zhao Yimin

Department of Prosthetics, School of Stomatology, the Fourth Military Medical University

Purpose: Bacterial invasion and epithelial downgrowth with pocket formation are still severe clinic challenges for transcutaneous implants, and both have closely connections with a lack of stable biological seal around transcutaneous parts. Dermal fibroblasts are the main cells of extracellular matrix in skin tissue, and have been proved to play vital roles in the formation of biological seal. This work is to explore more effective ways to promote fibroblasts adhesion, proliferation and generation of extracellular matrix for the formation of an early stable closure, then strengthen the long-term stability of maxillofacial implants.

Methods: In this work, platelet-rich plasma (PRP) which can release high concentrations of natural cytokines upon activation was used to stimulate rapid fibroblast growth. Mussel adhesive proteins (MAPs) could work as both bio-adhesive and a mediator to anchor blood platelets onto smooth Ti surfaces stably due to the excellent adhesive ability, and MAPs/PRP composite-coated Ti surfaces were constructed successfully. In this work, we took advantage of MAPs and PRP technology in order to get a better biological seal at the transcutaneous sites of implants. Further, the effects of MAPs/ PRP composite-coated Ti surfaces on biological responses of dermal fibroblasts in vitro were evaluated.

Results: The in vitro study indicated an increased fibroblast adhesion ($P<0.05$), cytoskeleton spreading, proliferation ($P < 0.05$), and up-regulated ECM-related gene expressions including β-integrin (ITGB), Matrix metalloproteinase(MMP)-1, vascular endothelial growth factor A (VEGFA)($P<0.05$),on MAPs/PRP composite-coated Ti surface compared with control smooth Ti surface. Our results suggest that the MAPs/PRP composite-coated Ti surface is potentially useful for a stable biologic seal at the transcutaneous sites.

Conclusion: This study showed the effects of MAPs/PRP composite-coated Ti surfaces on fibroblast functionality. MAPs were used as a mediator to anchor palates of PRP onto Ti surface, which serve as an intracellular storage pool of natural cytokines. As such, we successfully designed MAPs/PRP composite-coated structure for transcutaneous parts of implants, and the in vitro study indicated an increased fibroblast adhesion, spreading, proliferation, and up-regulated ECM-related genes expression compared to current smooth Ti surface around the transcutaneous parts of implants. Our results suggest that the MAPs/PRP composite-coated Ti surfaces may be useful for a stable biologic seal at the transcutaneous sites, and maybe a potential design for transcutaneous implants.

Key words: Transcutaneous implants; Platelet-rich plasma; Adhesion; Proliferation; Extracellular matrix

33

What Type of Implants Used for the Irradiated Bone Is the Better: Zirconia or Titanium Implants?

Zhou Wei, Zhao Yimin

Department of Prosthetics, School of Stomatology, the Fourth Military Medical University

Purpose: Zirconia implants have thus become an attractive alternative to titanium. Whether the zirconia implants could be used in the irradiated bone is not sure. The objective of the present study was to investigate the impact of radiation therapy on two materials (titanium and zirconia) implants in the dog mandible.

Methods: Five adult dogs received 40 (20 titanium and 20 zirconia) commercial threaded implants bilaterally in the mandibles after the premolars extraction. At 12 weeks post-implantation, the mandible containing implants was external beam irradiated with the biologic equivalent of 5,000 cGy. After 24 weeks healing, the five mandibles with implants were retrieved at sacrifice for mechanical and histological assessments to evaluate the biomechanical and biological behavior of the implants around irradiated bone.

Results: The Micro CT results showed that the average the bone–implant contact (BIC) rate of titanium implants was higher than that of the zirconia implants (44.47%>33.38%).For the parameters investigated, no statistically significant differences between implants could be detected at 24 weeks after radiation therapy ($P>0.05$). More lamellar bone had been observed by the staining of histological sections around the zirconia implants.

Conclusion: No statistical difference between implants could be demonstrated with any of the methods used. The trabecular bone microstructure around zirconia implant maybe less damaged than that around titanium implant after irradiation.

Key words: Radiation Therapy; Titanium; Zirconia; Bone Implant Contact (BIC)

34

The Study of Bi-lineage Differentiated ADSCs Sheet to Improve Implant Osseointegration in the Irradiated Bone

Dong Yan, Ren Nan, Zhou Wei, Liu Huan, Zhao Yimin

Department of Prosthodontics, School of Stomatology, Fourth Military Medical University

Purpose: To evaluate the effect of osteogenic and angiogenic bi-lineage differentiated adipose tissue-derived stem cells (ADSCs) sheet on implant osseointegration in the irradiated bone.

Methods: The lower hindlimbs of rats had external irradiation of a single dose of 20Gy. Eight weeks later, osteogenic and angiogenic bi-lineage differentiated ADSCs sheet-implant complex (Group A) was implanted in the tibia of the irradiated rat. Osteogenic differentiated ADSCs sheet-implant complex (Group B) and traditional pure Ti implant (Group C) were served as control groups. After eight weeks of implantation, Micro CT assay were conducted in vivo. Then the pull-out tests were proceeded and the rest of specimens were utilized to make hard tissue slices to analyze the implant osseointegration.

Results: The results of micro CT analysis showed that the bone volume ratio increased significantly in Group A compared with the control groups, while the trabecular separation decreased significantly in Group A compared with the other two groups. The bone-implant contacts were 63.48±5.82%, 56.28±6.16%, 42.35±7.22% and the maximal pull-out forces were 105.57±8.73N、92.81±6.34N、77.59±7.04N for Group A, Group B, Group C respectively. Both bone-implant contacts and maximal pull-out forces were significantly higher in Group A than the control groups.

Conclusion: The osteogenic and angiogenic bi-lineage differentiated ADSCs sheet-implant complex could improve osseointegration in irradiated rat, which provided a new approach to improve osseointegration of the impants in the regions received radiotherapy.

Key words: Adipose tissue-derived stem cells; Cell sheet; Implant; Radiotherapy; Osseointegration

35

Biological Characteristics of Osteogenic and Angiogenic Bi-lineage Differentiated ADSCs Sheet-implant Complex

Nan Ren, Yan Dong, Wei Zhou, Huan Liu, Yimin Zhao

Department of Prosthodontics, School of Stomatology, Fourth Military Medical University, Xi'an 710032 ShaanXi, China.

Purpose: This study aimed to construct osteogenic and angiogenic bi-lineage differentiated adipose tissue-derived stem cells (ADSCs) sheet-implant complex and investigate its biological characteristics.

Method: The osteogenic and angiogenic bi-lineage differentiated ADSCs sheet (Group A) and osteogenic differentiated ADSCs sheet (Group B) were warped on traditional pure Ti implant separately and the obtained complexes were cultured in vitro for 4weeks. ALP activity and the expression of BMP-2 and VEGF of the complex surface were investigated after 1d, 14d and 28d of culture. Then the complexes were implanted into subcutaneously pockets of severe combined immunodeficiency mice. After 8 weeks' transplantation, Micro CT assay was conducted in vivo. Then recover the complex, strip the tissue around it and stain with HE to observe its microstructure.

Results: The in vitro assays showed that Group A expressed higher level of ALP, BMP-2 and VEGF compared with Group B. The in vivo Micro CT images showed that the tissue around the implant had a mineral density similar to that of native bone in both groups, while the tissue of Group A was thicker than Group B. HE staining was also confirmed this, showing that more trabecula and microvascular structure formed in Group A compared with Group B.

Conclusion: In this study, osteogenic and angiogenic bi-lineage differentiated ADSCs sheet-implant complex was successfully constructed and the complex possessed excellent osteogenic and angiogenic activity.

Key words: Adipose tissue-derived stem cells; Osteogenic; Angiogenic; Cell sheet; Implant

36

Auricular Rehabilitation Using Early Loaded Intraoral Endosseous Implants: a Case of Bilateral Anotia

Minati Choudhury, Padmanabhan TV, N. Shanmuganathan

Department of Prosthodontics, Sri Ramachandra University, Chennai, India

Purpose: Craniofacial extra oral implants acquired an important role in auricular rehabilitation. This poster evaluates the effectiveness of early loaded intraoral endosseous implants for prosthetic reconstruction of bilaterally missing external auditory meatus and pinna.

Methods: A 16year old female patient with bilateral anotia was referred for prosthetic reconstruction. Patients was thoroughly evaluated with the reconstruction team involving a ENT surgeon, plastic surgery and prosthodontist as patient had four failed attempt at surgical ear reconstruction .CT scan was taken with radio opaque markers to evaluate the bone availability at the proposed implant site. Four intraoral wide diameter (5x7.3mm) endosseous implants (Neo biotech IS) were placed under GA .Single stage procedure was followed with the healing collar placed at the time of implant surgery and umbilical tape was wound over it with sterile dressing to form tissue cuffing. The implants were longer than the regular extraoral implants providing more initial stability. Also the initial clamping force is excellent as a strong streamlined thread extends to the end of the apex and advantageous for bi-cortical fixation. This design of the implant helped in early loading of the implant. After 10 days post surgery impression procedure was carried out and silicon prosthetic ear was given with bar and clip attachment.

Results: No skin infection, extrusion or bony complication was encountered during the follow up and the result was well appreciated.

Conclusion: Implanted under guidance of an appropriate team and with the proper selection of implant design intraoral implants can also be viable option for craniofacial prosthetic reconstruction.

Key words: Intra oral endosseous implant; Auricular prosthesis; Early loading

Session III - Tissue Engineering and Maxillofacial Rehabilitation

1

A Nvel Nno-bilayer Cllagen/Citosan Cmposite Mmbrane for Gided Bne Rgeneration

[1]Bo Gao, [2]Xiang Li[i], [1]Yan Dong

1 Department of Prosthetic dentistry, College of Medicine, Second Affiliated Hospital, Zhejiang University, Hangzhou, China

2 Material college, Zhejiang University, Hangzhou, China

Purpose： The purpose of present study was to develop a bi-layer membrane. Type Ⅰ collagen /chitosan/ poly(ethylene oxide) nanofibrous film with porous allowing cells adhesion and

proliferation；Collagen/chitosan film was on the opposite surface with freeze-dried for inhibition cells invasion.

Methods: Chitosan or collagen dissolved in 1%(v/v) HAc solutions to prepare a 2% and 0.5% (w/v) solution, respectively. After removing entrapped air-bubbles, the mixed solution frozen at -20℃、-40℃、-80℃ for several hours，lyophilized for 24h to obtain a porous membrane. Various weight percents of chitosan/collagen in 3%(v/v) HAc solution mixed with PEO were homogenized, solution was loaded into a 5ml syringe and connected to stainless steel needle tip by rubber tube. The solution was electrospun and the fibers were collected on aluminum foil covered with the previous fabricated film. The bi-layer composite membrane crosslinked with Glutaraldehyde vapor. Mechanical strength and morphology and biocompatibility evaluated by SEM, MC3T3-E1and MTT.

Results: Homogeneous nanofibers can be fabricated by electrospinning. Scanning electron microscopy observed that scaffold structure of the freeze-dried film side was dense and almost non-porous of cross-section; the nanofibers film side was a high porosity. Tensile strength of freeze-dried film was 0.6MPa and pressurized film was 4.04MPa ,which was similar to Haiau film of 4.96MPa. MC3T3-E1 spread well on the surface of the nanofibers. SEM images indicated that cells on the nanofibers also migrated through the pores into nanofiber mesh , which was beneficial for the three-dimensional repair of damaged bone tissue. Cell proliferation on collagen/chitosan nanofibers in vitro show that after 7-day culture, the number of cells increased with the culture time and much higher than control group, which implied the porous fiber structure favored cells attachment.

Conclusion: The bi-layer film showed favorable biocompatibility and promoted cells attachment and proliferation in early stage according to MTT test. Our preliminary research indicated that the bi-layer film have the potential to be a well substitute for guided bone regeneration.

Keywords: Electrospinning; Collagen; Chitosan; Composite membrane; Guided bone regeneration

nano- fiber bilayer collagen/chitosan composite membrane

2

Segmental Mandibular Defect Reconstruction Using Prefabricated Bone-implant Grafts or Autogenous Bone Grafts with Simultaneous Implantation: an Experimental Study in Dogs

Cheng Lin, Zhongcheng Gong, Zhao quan , Hao Wen

1 Post-doctor in Clinical Postdoctoral Research Station, the First Teaching Hospital of Xinjiang Medical University, Xinjiang Medical University, Urumqi, Xinjiang, China

2 Department of Oral & Maxillofacial Surgery, No.474 Military Hospital, Urumqi, Xinjiang, China

3 Oncology Department of Oral & Maxillofacial Surgery, the First Teaching Hospital of Xinjiang Medical University, Stomatology Faculty of Xinjiang Medical University, Urumqi, Xinjiang, China

4 Digestive and Vascular Surgery Center, the First Teaching Hospital of Xinjiang Medical University, Xinjiang Medical University, Urumqi, Xinjiang, China

Purpose: To evaluate a new method for functional reconstructing of segmental mandibular discontinuity defects using prefabricated ilium-implant grafts.

Methods: Eighteen Beagle dogs were randomly divided into three groups of six. The experimental group received bone grafts with prefabricated implants (PR group). The IM group received immediate simultaneous autogenous ilium and dental implant insertion and the control group received dental implant insertion 3 months after the ilium transplantation. In all animals, a 25 mm bone defect was created on one side of the mandible. In the PR group, the defect was reconstructed by an ilium-implant graft, prefabricated 2 months prior to surgery. Animals in the PR and IM groups were sacrificed 2

months after transplantation while animals in control group were sacrificed 3 months after implantation. The healing process was evaluated clinically, histologically and biomechanically. Morphometry measurements were made using Micro CT.

Results: The prefabricated (PR) implant group demonstrated superior bone formation to the immediate (IM) implant group. The bone-implant contact (BIC%) was 38.63±8.37% vs. 23.87±4.48%; $p<0.05$, bone volume/tissue volume (BV/TV) was 28.70±4.66 vs. 18.42±5.25; $p<0.05$, trabecular thickness (Tb.Th) was 0.92±0.17 vs. 0.39±0.14; $p<0.05$ and trabecular number (Tb.N) was 1.18±0.25 vs. 0.57±0.20; $p<0.05$). There were no significant differences in these parameters between the PR and control groups. The implant displacement force was 215.74N±14.29 N in PR group and 136.48N±19.67 N in IM group ($p<0.05$).

Conclusion: Prefabricated ilium-implant grafts shorten the treatment period and augment peri-implant bone tissues making the procedure a viable option for reconstructing segmental mandibular defects.

Key words: Mandibular reconstruction; Bone grafting; Prefabricated composite grafts; Autogenous bone; Dental implant

3

Analysis of Brain Activity in Patients with Chewing-Side Preference During Chewing: An FMRI study

Hua Jiang, Hongchen Liu, Gang Liu, Zhen Jin, Yanan Li, Lin Wang

Department of Stomatology, Chinese PLA General Hospital

Purpose: Investigate the activation characteristics of cerebral cortex in participants with CSP during rhythmic chewing movement.

Methods: Sixteen right-handed participants with left (2 males: 29.0±8.4 years old, 6 females: 32.3±4.8 years old) or right (4 males: 31.0±6.1 years old, 4 females: 30.8±4.7 years old) CSP were scanned by functional magnetic resonance imaging during rhythmic chewing. The on-off sequence of scanning was 30s of rhythmic chewing and 30s of rest (off) a total of 5 times.

Results: The results showed that blood oxygen level–dependent signals in the contralateral (to the CSP) primary sensorimotor cortex increased more than in the ipsilateral primary sensorimotor cortex in participants with both left and right CSP ($P\leq0.001$). Moreover, the BOLD signal within the right substantia nigra of midbrain, brainstem was more significantly ($P\leq0.001$) activated than its left counterpart in participants with left CSP while no activation was observed in those with right CSP except for one participate in the individual-based analysis. The inferior parietal lobule, inferior frontal gyrus and left insular cortex were significantly ($P\leq0.001$) activated in participants with right and left CSP.

Conclusion: These findings suggest a relationship between hemispheric dominance and CSP in the primary sensorimotor cortex responsible for rhythmic chewing movement. The brainstem might also play important role in the regulation of CSP.

Key words: Chewing-side preference(CSP); Cerebral cortex; Functional magnetic resonance imaging; Chewing

4

Comparison of EGF and bFGF Expression in Vivo and Their Effect in Vitro

Jiarong Liu, Lijuan Zhu, RanYu, Chenguang Zhang, Lili Chen

Huazhong University of Science and Technology

Purpose: Oral mucosal wound healed faster and with minimal scar formation compared with dermal wounds. The present study tried to found useful information in scarless oral wound healing process.

Methods: This study firstly evaluated the effect of EGF and bFGF on the proliferation and migration of isolated fibroblasts from oral mucosa and skin. Then an liner wound was made in SD rats on transplanted oral mucosa and control skin.

Results: In vitro study we found that both bFGF and EGF could promote the migration of dermal fibroblasts but not for oral fibroblasts. The oral fibroblasts proliferation was more sensitive to different concentrations of EGF, while bFGF had no significant effect on cell proliferation in this experiment. Our in vivo results demonstrated that oral mucosal wound healed with minimal scar after transplanting to skin and expressed higher EGF. No regular bFGF expression was found either on the transplanted oral mucosal or dermal wound.

Conclusion: The results suggested that oral mucosa healed with minimal scar mainly due to its inherent cell phenotypes. The results also implied the important role of EGF played in scar formation.

Key words: EGF; bFGF; keratinocyte

5

Great Auricular Nerve Grafting in The Treatment of Facial Palsy in Parotid Tumor Surgery

Lu Xuguang, CaiZhigang, YuGuangyan, PengXin

Department of Oral and Maxillofacial Surgery, Peking University School and Hospital of Stomatology, Beijing, 100081, China

Purpose: To assess the long time follow-up nerve function and clinical value of great auricular nerve grafting in the treatment of facial palsy after parotidectomy.

Methods: From 1998 to 2004, 14 patients with parotid tumors who were treated with great auricular nerve grafting afterparotidectomywere followed up.(9 men and 5 women; age range 22~65 years). 4 were benign and 10 were malignant tumors. All of them were unilateral affected.11 cases of nerve grafting were done immediately after the tumor dissection. 2 cases were done 6 months after tumor operation and one case was 9 months. The facial nerve affected included 6 cases in the main trunk, 4 cases in the cervical division, one was in the zygomatic branch and one was in the zygomatic branch and temporal branch. The great auricular nerve in the same side of the tumor was harvested for nerve grafting except both sides were used in one case. These patients were followed up from half a year to 5 years, until they were recovered or no obvious recovery was observed in half a years.Neurotrophic drugs and neuromuscular facial retraining were both given post operation. House-Brackmann grading scale, electroneurography and whether the patient was satisfied with the operations were applied to analyze the results of the operation.

Results: Except for one patient recurred one year after operation,10 cases which were treated at the same time with tumor dissection recovered to HB grade I to II. All 10 patients were satisfied with the results of operation. 7 cases hadfacial spasm in the tumor side.2 patients had no recovery in lifting eyebrow. Electroneurography showed the amplitudes in the grafting sides are all lower than the normal side. Only 1 of the 3 cases which were treated more than half a year later recovered to HB grading II, the other 2 have no recovery in facial nerve movement and electroneurography showed no signal..

Conclusion: The great auricular nerve grafting is an effective method in the treatment of facial nerve defect in parotidectomy. A great part of facial nerve function will be preserved after operation. Facial plasmis a common complication. Instant operation will get a much better result than secondary operation.

Key words: Parotid tumor; Facial palsy; Great auricular nerve Nerve grafting

6

Effects of Aqueous Areca Nut Extract on The Level of Endothelin-1 Secreted by Endothelial Cells

Pang Danlin, PengJieying, YinXiaomin, WuYingfang, Li Ming

Xiang YaStomatological Hospital Central South University

Purpose: To assess the possibility of endothelial cells (EC) and endothelial cells-1(ET-1) in the process of oral submucous fibrosis(OSF) by observing the direct effect of aqueous areca nut extract （AANE） on the level of ET-1 secreted by EC.

Methods: EC (from ECV-304) were cultured in vitro. EC were incubated together with AANE of different concentration:0、50、100、200、400、600、800 ug/ml, and after 48 hours we investigated the level of ET-1.

Results: The level of ET-1 secreted by EC was increased when EC were affected by AANE of concentation at 100 ug/ml or more for 48 hours,and positive comelations were found between intensity of increasing agents and the dosage.

Conclusion: AANE of some concentration could play an important role in the process of OSF through making the content of ET-1 increase by injuring EC.

Keywords: Queous areca nut extract; Oralsubmucousfibrosis; Vascularendothelial cell; Endothelin

7

Morindacitrofolia Enhances Bone Marrow Mesenchymal Stem Cell Proliferation and Facilitates Osteogenesis

Sharmila Hussain, Ramasamy Tamizhselvi, Leema George

1. Department of Prosthodontics, Saveetha dental college and hospital, Chennai, Tamilnadu. India

2. School of BioSciences and Technology, Vellore institute of technology, Tamilnadu. India

Purpose: *Morindacitrifolia*(Noni), an important traditional medicinal plant used in patients with bone fractures or dislocation to promote connective tissue repair and to reduce inflammation. However, the influence of *Morindacitrifolia* on osteogenic differentiation is yet to be clarified. The objective of this study is to evaluate the effect of Noni juice (NJ) on the proliferation rate of bone marrow mesenchymal stem cells (MSC), the differentiation of marrow mesenchymal stem cells into osteoblasts (osteoblastogenesis) and the level of mineralization.

Methods: The rat bone marrow-derived MSC were isolated and cultured in media with or without TNJ (*Morindacitrifolia)*and their osteogenic differentiation was evaluated by their alkaline phosphatase (ALP) activities and level of mineralization. MSC cultures in control media and media supplemented with Noni juice were also subjected to a cell proliferation assay (MTT).

Results: Runt-related transcription 2 (RUNX2) mRNA expression was examined by RT-PCR. The addition of NJ to undifferentiated MSC increased their proliferation rate significantly in comparison with that of cells grown in basal media alone.

Conclusion: MSCs grown in basal media and supplemented with NJ differentiated into osteoblasts, as identified by ALP activity and increased bone mineralization. Furthermore, RUNX2 mRNA expression was observed in MSC supplemented with NJ. Our study demonstrated that the TNJ could increase bone regeneration and may become very useful in the rapidly advancing field of regenerativemedicine

8

Evaluation of a Critical Size Calvarial Defect in the SAMP6 Steoporosis Mouse Model

Yufeng Zhang, Lu Wang, Feng Deng, Hongmei Qiu, Xiaohong Wu

Department of Prosthodontics, the Affiliated Hospital of tomatology, Chongqing Medical University

Purpose: To establish a calvarial defect model in mice with senescence-accelerated osteoporosis and evaluate differences in the spontaneous healing capacity between senescence-prone inbred strains (SAMP6) and senescence-resistant inbred strains (SAMR1) in order to determine the critical size defect in the cranium of this animal model.

Methods: Unilateral full-thickness calvarial defects of 2 or 4 mm in diameter were made in 6-month-old male SAMP6 and SAMR1 mice (n=6 per size). The local repair process was monitored in vivo by high-resolution micro-CT scanning at day 0 and 6 and 12 weeks postoperatively. After the final micro-CT scan, mice were sacrificed, and calvarial specimens were collected for histological examination by hematoxylin and eosin staining and histochemical staining with Masson's trichrome and tartrate-resistant acid phosphatase (TRAP) staining to identify the content of healing tissue and osteoclast activity within the defect, respectively.

Results: In vivo micro-CT analysis revealed that a significantly smaller percentage of new bone formation was observed in defects in SAMP6 mice compared to SAMR1 mice at 12 weeks post surgery, with <5% healing in SAMP6 mice for both 2- and 4-mm defects compared >5% healing in 2-mm defects in SAMRI mice ($p<0.05$). Still, the mean percentages of healing within the calvarial defects in both SAMP6 and SAMR1 mice were less than 10%. Histological analysis revealed a dense connective tissue layer but little bone healing in 2- and 4-mm defects in SAMP6 and 4-mm defects in SAMR1 mice. In contrast, newly formed bone was observed at the periphery of the 2-mm defects in SAMR1 mice. Masson's trichrome staining also supported these findings. In addition, more enlarged osteoblasts were detected at the periphery of defects in SAMR1 mice, and even though no obvious TRAP-positive cells were found at the margins of any defects, more TRAP-positive cells were seen in the diplo ë of contralateral cranial bone in SAMP6 mice than in that of SAMR1 mice.

Conclusion: A 2-mm defect was found to be a critical size defect in the cranium in both SAMP6 and SAMR1 mice. Intramembranous ossification of the defect was impaired in SAMP6 mice, likely due to the combined effects of osteoblast insufficiency and excessive osteoclastogenesis.

9

Fabrication and Cell Compatibility Evaluation of Pure Titanium Coated with Sustained Release System of BMP-2/ Biomimetic Calcium Phosphate

Zhipei Chen,Xiaojing Zhu, Hui Zhang, Chengyun Nin, Yan Wang*(corresponding author)

Guanghua School of Stomatology, Sun Yat-sen University

Purpose: To fabricate sustained release delivery system of bone morphogenetic protein (BMP-2) / biomimetic calcium phosphate coating on titanium surface, explore the effects of BMP-2 concentration on the loading and release behavior of BMP-2 and evaluate cell compatibility of the system in vitro.

Methods: 0.1mm thickness of pure titanium (Ti) specimens were immersed into sterile SBF solution for 4d at 37℃ and then rinsed with deionized water and air dried overnight at 37℃. The coated specimens were then randomly divided into five groups and immersed in supersaturated calcium phosphate solutions (SCP) which contained five concentrations of BMP-2 (0, 50, 100, 200 and 400ng/mL) for 2d at 37℃ to fabricate calcium phosphate coatings loaded with BMP-2. The topography of the specimen was observed by scanning electron microscopy. Chemical structure and phase composition of coatings were detected by Fourier infrared spectroscopy analysis and X-ray diffraction respectively. The amount of incorporated BMP-2 and its release profile were determined by BMP-2

enzyme linked immunosorbent assay kit. Cell biocompatibility was assessed by observing MC3T3-E1 morphology by SEM, detecting the proliferation and differentiation ability by CCK-8 kit and alkaline phosphatase kit .

Results: 1.The inclusion of BMP-2 did not change the surface topography and phase composition of the codeposited coatings regardless of BMP-2 concentration in supersaturated calcium phosphate solution. All the coatings were composed of plate-like units of hydroxyapatite and octacalcium phosphate crystals. The loading amount of BMP-2 in the calcium phosphate coatings increased accordingly with the increase of BMP-2 concentration in supersaturated calcium phosphate solution. The in vitro release test showed that all the release profiles of BMP-2 of the 4 various concentrations could be divided into two stages- -burst release stage and sustained release stage, with about (51.46±1.4)%, (45.98±4.0)%, (38.25±5.2)%, (28.91±1.3)% BMP-2 release in 24hours respectively, and (72.52±2.1)%, (76.72±1.26)%, (62.83±1.27)%, (49.14±1.5)% BMP-2 release in 20 days respectively. BMP-2 was continuously released in a sustained manner.2. BMP-2 /calcium phosphate coatings were more favorable for cell adhesion. Both cell proliferation and differentiation ability showed a concentration - and time-dependent manner. The highest cell density and differentiation ability were found on coating fabricated with BMP-2 concentration of 400ng/mL .

Conclusion: 1.BMP-2 incorporated inside the BMP-2/ biomimetic calcium phosphate is released in a sustained manner. Favorable BMP-2 incorporation rate and release model can be obtained at the concentration of 400ng/mL.2.The hybrid coating of BMP 2/calcium phosphate can significantly promote the proliferation and differentiation ability of MC3T3-E1 on the surface of titanium. The 400 ng/mL BMP- 2 group showes the optimal cell compatibility in vitro.

Key words: Pure titanium; Calcium phosphate coating; Bone morphogenetic protein 2; Sustained -release; Cell compatibility

10

Electrophoretic Deposition of Amoxicillin Silk Fibroin Coatings for Functionalization of Titanium Surfaces

Zhen Zhang, Xian Cheng, Xiaoshuang Li, Lili Chen

Union Hospital, Tongji Medical College, Huazhong University of Science and Technology

Purpose: To investigate the function and mechanism of the amoxicillin loaded silk fibroin coating

Methods: The prepared coatings were characterized using fluorescence microscopy, scanning electron microscopy, Fourier transform infrared spectroscopy, X-ray diffraction, shear bond strength testing and antibiotic test.

Results: The characterization of the obtained coatings indicated that the intermolecular hydrogen bonds formed between the backbone of silk fibroin and amoxicillin molecular. The amoxicillin loaded coating showed remarkable antibacterial activity against gram-positive (Staphylococcus aureus) and gram-negative (Escherichia coli) bacteria.

Conclusion: Electrophoretic deposition was an effective and efficient technique to prepare amoxicillin loaded silk fibroin coatings on the titanium surface and that the coatings with antibacterial property were promising candidates for further loading of functional agents.

Key words: Electrophoretic deposition; Silk fibroin; Amoxicillin.

11

Effects of Acellular Dermis Matrix for The Prevention of Gustatory Sweating Syndrome After Parotidectomy: A Systematic Review Based on Randomized Controlled Trials

Gou Liming, Li Chunjie, Li Longjiang

Department of Head and Neck Oncology, West China Hospital of Stomatology, Sichuan University

Objectives: To assess the efficacy and safety of acellular dermix matrix for the prevention of gustatory sweating syndrome after parotidectomy.

Methods: Medline, CENTRAL, EMBASE, OPEN SIGLE, CBM, VIP, CNK and Wanfang database were searched electronically on March 17th 2013. Hand-searching covering 19 relevant Chinese journals were also performed. Risk of bias assessment, which was suggested by Cochrane handbook for systematic reviewers of intervention review, and data extraction of included studies were delivered by two reviewers in duplicate. Meta-analysis was done with Revman5.2 and STATA 11, and the quality of evidence was evaluated by GRADE.

Results: 16 randomized controlled trials involving 1097 participants were included and 1 included studies had high risk of bias and the rest had unclear risk of bias.. Meta-regression showed the variables related to the clincial heterogeneity did not influence the outcome (P>0.10). Begg test showed there was no publication bias (P=0.350). The meta-analysis showed that for objective assessment, acellular dermis matrix implantation could reduce 82% of the gustatory sweating syndrome (P<0.00001) which had the strongest clincial recommendation. For subjective assessment, acellular dermis matrix could reduce 89% of the incidence of gustatory sweating (P<0.00001). When comparing acellular dermix matrix, there was no difference between acelluar dermix matrix with tissue flaps (P=0.70). No serious adverse events were reported.

Conclusion: There is significant effect and safety of acellular dermix matrix for prevention of gustatory sweating syndrome after parotidectomy and had a strong clincal recommendation. But more high-quality RCTs were needed to increase the reliability.

12

The Effect on Induced Pluripotent Stem Cell of The Extract of Akermanite in Vitro

Dong Xixi, Du Qinghua, Wei Lijun, E Lingling, Cao Junkai

Department of Stomatology, Chinese PLA General Hospital.

Purpose: To assess the ability of iPS cells to differentiate into bone in vitro.

Methods: Use the different diluted rate extract to induce ipsc, MTT analysis were used to reveal the proliferation. Expression level of osteogenic differentiation genes(ALP、BSP、OCN) were examined at 7、14 and 21 days.

Results: 1/2 extract has the better efficiency in osteogenic differentiation.

Conclusion: The exract of Akermanite has the ability to induce ipsc into bone, and ipsc with its scaffolds have a great potential in application in engineered bone.

Key words: Induced pluripotent stem cell; Bioactive ceramics; Akermanite; Tissue engineering;

13

Comparision of The Effects of Different Occlusal Reconstruction on Partial Mandibular Bone Defect Patients

Li Yanan, Guo Guihua, Shi Xiaowei, Li Hongmei, Gong Qiwei, Liu Hongchen

Department of Stomatology, Chinese PLA General Hospital

Purpose: To explore and compare the effects of occlusal reconstruction with removable prosthesis and fixed prosthesis on partial mandibular bone defect patients..

Methods: 41 patients with partial mandibular bone defect and 1-2 molar or premolar lost were divided into two groups, 24 were repaired with removable prosthesis, and 15 were repaired with fixed prosthesis. Their feelings (esthetic feeling, comfort), clinical symptoms, masticatory efficiency and temporomandibular joint disease symptoms (TMJDS) were observed and analyzed before and after occlusal reconstruction..

Results: The patients were all satisfied with their prosthesis. Their clinical symptoms, masticatory efficiency were improved. Statistical analysis showed the significant differences before and after occlusal reconstruction ($P<0.01$). The fixed prosthesis had better effects than the removable prosthesis （$p<0.05$）on patients' feeling and masticatory efficiency. No patient showed TMJDS after occlusal reconstruction in either group.

Conclusion: Both removable prosthetic and fixed prosthetic occlusal reconstruction were effective to improve the partial mandibular bone defect patients' oral and occlusal function. The fixed prosthesis has better effect on esthetics, feeling, comfort and masticatory efficiency.

Key words: Partial mandibular bone defect; Occlusal reconstruction; Removable prosthesis; Fixed prosthesis

14

IL-22 Mediates Oral Mucosal Wound Healing Via STAT3

Ding Yumei, Yu ran, Zhu Lijuan, Zhang Chenguang, Chen Lili

Union Hospital, Tongji Medical College, Huazhong University of Science and Technology

Purpose: To investigate the function and mechanism of IL-22 during oral mucosal wound healing

Methods: Expression level of IL-22 and STAT3 were investigated via a mice tongue wound model in vivo, and in vitro study was checked with Real-time PCR, Western blotting and proliferation assays in keratinocytes and fibroblast.

Results: The results showed that IL-22 and p-stat3 were associated with oral mucosa wound healing, and STAT3 was activated when the keratinocytes and the tongue tissue were stimulated by IL-22. But fibroblasts showed negative result.

Conclusion: In summary, our study suggests that IL-22 can promote the oral mucosa wound healing via STA3 in keratinocytes.

Key words: IL-22; STAT3; keratinocyte

15

Cell-bricks Based in Jectable Niche Guided Persistent Ectopic Chondrogenesis of BMSCs and Enabled Nasal Augmentation

Ba Ruikai, Li Man, Wu Wei , Zhao Yimin

Department of Prosthetics, School of Stomatology, The Fourth Military Medical University

Purpose: Developing cartilage construct with injectability, appropriate matrix composition and persistent cartilaginous phenotype remains an enduring challenge in cartilage repair. Bone marrow derived mesenchymal stem cells (BMSCs) presented chondrogenic potential. Current approaches to drive their chondrogenic differentiation require extensive cell manipulation ex vivo and using exogenous growth factors. However, preventing hypertrophic transition of BMSCs in vivo and maintaining persistent chondrogenesis remain bottlenecks in clinical application. This study aimed to develop completely biological, injectable construct to generate cartilage by co-transplanting chondrocyte and BMSCs.

Methods: Chondrocytes isolated from 1-month old rabbit's auricular cartilage were cultured to form cell bricks and cell expension for 10 days while BMSCs from the same donor were expanded for seeding. 48 nude mouse were divided evenly(n=6) into BMSCs-PRP(B-P), BMSCs-chondrocytes-PRP(B-C-P),BMSCs-cell bricks-PRP(B-CB-P)groups for1month and 3months achievement. BMSCs, cell bricks, BMSCs/chondrocytes mixture or BMSCs/cell bricks mixture were suspended in PRP and were subcutaneously injected into animals..

Results: Best cartilage formation was achieved in B-CB-P group after 3months,confirmed by safranin O staining, and collagen type II immunostaining. Hypertrophy and ossification appeared in B-P and B-C-P, confirmed by collagen type X immunostaining ,collagen type I immunostaining and Masson's trichromestaining. Immunofluorescencestaining of BrdU

(5-Bromo-2-deoxyUridine) labeling BMSCs confirmed that new-born chondrocytes originated in BMSCs we injected. Statistical differences could also be found among four groups in terms of gene and protein expression. We used the complex of B-CB-P to construct a new nose for nude mouse and observed for 12 weeks, finding it stable in morphology.

Conclusion: We concluded that cell bricks-enriched PRP clot provide autologous substance derived niche for chondrogenic differentiation of BMSCs *in vivo*, which suggests that such an injectable, completely biological system is a suitable stem cell carrier for micro-invasive cartilage repair

Key words: Cell bricks; Chondrogenesis; Bone marrow stromal cell; Hypertrophy; Nasal augmentation

Session IV – Miscellaneous topics in Maxillofacial Rehabilitation

1

Effect of Thixotropic Agent on Physical Properties of Facial Silicone Elastomer

Abdel Raheem Bibars, Zied Alhourani

Jordan University of Science and Technology

Purpose: The aim of this study was to investigate the effect of viscosity modifiers on the mechanical properties of silicone elastomers

Methods: One hundred twenty dumbbell-shaped and trouser-shaped specimens were produced using

combinations of cosmosil M511 part A, part B and colorants (1 drop/5gm). Trouser-shaped specimens will be used to evaluate the tear strength of the maxillofacial material. While dumbbell-shaped specimens were utilized to evaluate the tensile strength and the elongation percentage.

Results: The group of silicone without thixotropic agent had a significant higher tear strength than that of silicone with added thixotropic agent ($P<0.05$). Overall there were no significant differences in the mean tensile strengths between the two groups silicone without added thixotropic and the group added thixotropic agent ($P=0.4$). The elongation at break for the two groups showed that the group of silicone added thixotropic agent had a significantly lower elongation at break in comparison to the other materials ($P<0.001$).

Conclusion: Within the limitations of this study, it can be concluded that adding thixotropic agent to the silicone during mixing can lead to lower tear strength and elongation percentage.

Key words: Thixotropic agent; Thickening agent; Maxillofacial silicone; Tear strength; Tensile strength

2

Conventional Prosthodontic Management with Attachment-retained Overdenture in Ⅱ Class Defects of Maxilla Patients

Bai Bing,Zhu Jingtao,Ai Hongjun

Department of Prosthodontics, School of Stomatology, China Medical University

Purpose: The aim of the study was to evaluate the effect of ball cap attachment-retained maxillofacial rehabilitation prothesis for the Ⅱ class defects of maxilla.

Methods: We make Maxillofacial Rehabilitation prothesis for 10 patients with ball cap attachment. We choose the teeth which near the defect as the abutments of ball cap attachment. After root canal therapy of these teeth, we made ball cap attachment on them. After 1 week of the prothesis of Ⅱ class defects of maxilla patients, we fixed the cap. The Patient's Satisfaction (PS), Speech Intelligibility (SI) and Masticatory Efficiency (ME) were investigated before and 1, 3, 6 and 12 months after the fix of the cap. The ME test was performed with optical, an artificial test food.

Results: The PS of all prothesis was excellent; 2 of them need to be relined. The SI of patients was significantly enhanced as soon as the prothesis were done. Speech of all patients made great progress after the treatment. The ME was higher in patients with ball cap attachment after treatment than before. The ME was near 20-30% before treatment, and the ME were near 40-50% after treatment.

Conclusion: Ball cap attachment has an effect to improve the quality of patient's oral prothesis. The ball cap attachment improved the quality of patient's life.

Key words: Ball cap attachment; Maxillofacial Rehabilitation; Ⅱ class defects of maxilla

3

Yu's Flap For Lower Lip and Reverse Yu's Flap for Upper Lip Reconstruction: 20 years experience

Sun ChangFu

Hospital of Stomatology, China Medical University

Purpose: The aim of this study is to report our experience of the Yu's flaps, and we hope it will be helpful to other surgeons.

Methods: In our department between January 1992 and December 2012, 8 patients had reverse Yu flaps for the reconstruction of upper lip defects and 56patients had classic Yu flaps for lower lip defects.

Patients with defects located laterally to the upper lips, ranging from 1⁄3 to ½, had unilateral reverse Yu flaps, and bilateral procedures were done for defects of less than 2⁄3 of the lips. However, if the defects were located in the centre of the upper lips, between 1⁄3 and ½, they were treated with bilateral reverse Yu flaps. Patients with defects between1⁄3 and 2⁄3 of lower lips had unilateral Yu flaps, and if the defects were wider than 2⁄3 of the lower lips, the procedure was bilateral.

Results: No flap failed and desirable functional and aesthetic outcomes were recorded in all cases.

Conclusion: The Yu technique can be used as a one-stage procedure to close defects up to all the lower lips and 2⁄3 of the upper lips.

Key words: Lip defects; Yu's flap; Lip reconstruction; Combined rotation and advancement flap

4

The Total Lower Lip Reconstruction after Squamous Cell Carcinoma Resection

Chen Qiang, Xu Yang

Department of Oral and Maxillofacial Surgery, School of Stomatology of Jilin University

Purpose: To assess the effectiveness of local flaps for total lower lip reconstructions. To preserve oral function and achieve acceptable cosmetic results. To certify the two-stage operation is deserved.

Methods: We applied two-stage operation in a patient with total lower lip defect following excision of squamous cell carcinoma. Total lower lip reconstruction was performed in two operations. The first operation method is local Upper lip pedicle flap and two advancement flaps. After first operation, we just restored a large part function. Such as, oral competence, muscle function, lips sensation. The disadvantage is microstomia, so subsequent corrective surgery is required. The second operation is restore the oral gape .

Results: After first operation, we restored a large part function. Such as, oral competence, muscle function, lip sensation. The disadvantage is microstomia. After the second operation, we restored the oral gape. After two operations, the functional and aesthetic outcomes are satisfactory on follow-up, with normal lip movement and sensation, adequate mouth opening, good colour and texture match with adjacent tissues, and excellent volume and quality of the vermillion. No recurrence has been noted 6 months after lower lip excision.

Conclusion: Effective reconstruction of the lower lip must not only restore the shape but also preserve the function of the lip. So lower lip reconstruction aims to restore function and appearance with the best results, ideal lip reconstruction should maintain sphincter function, not leak fluid between the upper and lower vermillions, obtain sufficient mouth space, and have an acceptable aesthetic appearance. With the total defects, reconstruction is less than optimal, but every effort should be taken to obtain an adequate sphincter function and lip continence to saliva, both of which are the most important goals to achieve in lip reconstruction.

This technique is simple and achieves the main goals of total lower lip reconstruction in a single stage with minimal morbidity. What is more, no recurrence has been noted 6 months after lower lip excision.

Key words: Lower lip; Reconstruction

5

Application of Retentive Techniques in The Restoration of Maxillary Defects

Liu Yang, Leng Yong

Dalian Stomatological Hospital

Purpose: To investigate the effect of several retentive techniques in the restoration of maxillary defects.

Methods: Four cases were included: 2 females and 2 males who visited the Prosthodontics department of Dalian Stomatological Hospital from Dec 2009 to Jun 2011. Their ages ranged from 59-76 with average 67.5 years old. According to Zhao Yinmin's classification to maxillary defects : one Class Ⅰ maxillary defect with defect of hard palate. Two Class Ⅴ maxillary defect with defects of one half of dentulous maxillary. One Class $Ⅶ_5$ maxillary defect with defect of one half of edentulous maxillary . Hollow maxillary prostheses were designed and issued to the four patients. In Class I case framework prosthesis with 3 clasps combined with soft reliner obturator were designed. In class Ⅴ cases framework prostheses with clasps combined with ERA attachments were designed. Abutment teeth near the defects were protected with connected crowns. In class $Ⅶ_5$ case root magnetic attachments were designed . The whole clinic processing was operated by the same specialist from design to prostheses issue and adjustment.

Response Evaluation Criteria: according to the evaluation criteria proposed by Zhao Yimin and other scholars: ① Excellent: intact prosthesis; prosthesis are in good stability, restore the patient's pronunciation and appearance, restore chewing function partially, no inhaled drinking and abutment tooth mobility. ②Good: intact prosthesis; prosthesis are in accepted stability, partially restored patient's above function and appearance; no inhaled drinking and abutment tooth mobility exist.③Poor: Any of the following one: damaged prosthesis or fracture of the clasps; prosthesis are in bad stability; cannot effectively restore above function and appearance; tooth loosening due to prosthesis.

Results: Four cases restored with hollow maxillary prostheses have got excellent clinic effects. In class **I** case patient's facial appearance has no change after restoration. In the other three cases patient' facial appearance improved greatly .The four prostheses have no damage after two-years with good retention and reliable stability. Patients' masticatory function was restored partially as well as phonetic function and facial appearance. No inhaled drinking and abutment teeth mobility happened. Mental states of the patients have improved a lot with increased confidence.

Conclusion: Reasonable retention design is one of the key steps in the restoration of maxillofacial prosthetics. Prosthetic treatment in maxillary defects is a relatively faster, cheaper and more convenient method which can significantly improve the function of mastication, pronunciation and are easily accepted by patients.

Key words: Maxillary defect; Prosthesis; Retention.

6

A Study of Computer Color Matching of Silicone Elastomer Based on Artificial Neural Networks

Fang Su

Dental Institute

306 Hospital of Chinese PLA， Beijing 100101， China

Maxillofacial Prosthetics as the special area of dental practice, which restore the orofacial defects with maxillofacial material to rehabilitate the patients appearance and function that is an ancient art. Color selection and color matching is the key to success in the maxillofacial restorations. The color difference between the facial prosthesis and surrounding skin has long puzzled both of dentist and patient. The color matching of the restoration is a complex process, and now the dentists who select and evaluate the color of skin and restoration depend on perceptional method. The perceptional method relies on

color perception by human eyes, which is affected by many factors: surrounding light condition, size of objective, background and eye fatigue. The purpose of this study is to introduce CCM technology into the color matching of maxillofacial restorations and set up a set of equations to increase the accuracy of color matching.

Computer Colorant Formulation has been implemented using a theory of radiation transfer known as Kubelka-Munk (K-M) theory. Oil paint matching as some other paints needs to use the two-constant K-M model if we take a computer color matching method based on the K-M theory. However, some assumptions have to be met when we use the model, so the application of two-constant K-M model is restricted a lot. In this study, avoiding using the complicated optical assumption, the artificial neural networks (ANNs) was introduced to the research of color matching of maxillofacial restoration because of its advantage in solving the problem of nonlinear mapping between color space and recipes space. The results of the study are as follow:1.According to the research of Structure of Networks, a multi-layer BP neural network model is made to predict the recipes of oil paints in this study. 2.The experiment shows that the multi-layer BP neural networks model could Implement the prediction well between CIE-XYZ color space and recipes space. The results suggest that all the errors distribute at a low level. Almost all of the color difference is under 1.5. The result is content to meet clinical requirements of color matching of maxillofacial restoration.

Key words: Silicone elastomer; Computer color matching; Artificial neural networks

7

Clinical Trial of Novel Silicone Materials for Facial Prostheses

Fumi YOSHIOKA, Shogo OZAWA, Maiko, Manami, Kohei, Yoshinobu

Aichi Gakuin University, School of Dentistry, Removable Prosthodontics

Purpose: A project of developing novel silicone materials is proceeding by the cooperation of Japanese Academy of Maxillofacial Prosthetics and GC Company, Japan. We have tested basic properties of trial prosthetic silicone materials and revealed that they have comparable properties with the existing silicone material. The aims of this study are to access color stability of the silicone materials, and to compare two kinds of silicone materials in terms of color changes and patients preferences.

Methods: Silicone samples were fabricated using two kinds of silicone; novel silicone developed by GC and existing materials manufactured by Factor II. The samples including pigments and nylon flocking were exposed artificial ultraviolet light, and evaluated color changes by spectrophotometer. Moreover, clinical trial was conducted and twelve patients who were treated in Maxillofacial Prosthodontic Clinic, Aichi Gakuin University Dental Hospital were enrolled in this study. Eight weeks after the delivery of two facial prostheses, patient preference was surveyed by questionnaire.

Results: The color changes on the CIE Lab values revealed that Hue and Chroma showed significant differences between before and after the exposure rather than brightness in both materials. The samples including nylon flocking were more affected by ultraviolet exposure than the samples with pigments only. Results of the questionnaire demonstrate that impression of usage and subjective evaluation were different between two materials although color change did not show significant differences. Patient preferred facial prostheses made of novel silicone materials in terms of materials properties and feeling of wear.

Conclusion: Novel silicone material has similar material property and color stability as compared to the existing material. Clinical trial of this material showed favorable patient acceptance. This project was supported by cooperation of Japanese Academy of Maxillofacial Prosthetics and GC Company, Japan.

Key words: Silicone material; Facial Prosthesis; Clinical Trial; Changes

8

Application of Vacuum Sealing Drainage (VSD) in Maxillofacial Complex Wound

Gao Jianyong

Department of Stomatology, Changhai Hospital, Second Military Medical University, Shanghai

Purpose: To explore the methods and clinical value of vacuum sealing drainage in the treatment of complex maxillofacial and neck wound infection , effusion and internal and external fistula after the oral cancer radical and reconstruction operation.

Methods: Collect these numbers below in our department. Between January 2008 to January 2011, there was 8 cases with wounds effusion and split, and 5 cases with internal and external fistula under the jaw and neck after the oral cancer radical + free flap defect repair, statistics the average time of healing the wound by using the conventional treatment. Between January 2011 to January 2014 , there was 9 cases with wounds effusion and split ,and 6 cases with internal and external fistula under the jaw and neck after the oral cancer radical + free flap defect repair, statistics the average time of healing the wound by using vacuum sealing drainage.

Results: The average time of healing the effusion and cracking wounds was 16 days by using the conventional treatment, but internal and external fistula in mouth was 24 days. And the average time of healing the effusion and cracking wounds was 12 days and the internal and external fistula in mouth was 19 days by using vacuum sealing drainage . The time were significantly shortened to 4 days (25%) and 5 days(21%).

Conclusion: The VSD not only can drainage thoroughly, keep the wound clean and then prevent infection, but also narrow the wound, eliminate the dead space, stimulate the growth of granulation tissue rapidly, promote wound healing and shorten the time of repairing. In the treatment of the complicated postoperative wound's repair after oral cancer radical, vacuum sealing drainagecan improve the clinical therapeutic effect, shorten the time of living in the hospital, relieve patients' pain, reduce the times of using the antibiotics, and it is an effective method for the treatment of maxillofacial and neck complicated wound .

Key words: VSD; Maxillofacial complex wound

9

Chimeric Flaps Pedicled with Lateral Circumflex Femoral Vessel for Individualized Reconstruction of Through-and-through Oral and Maxillofacial Defects

Gong Zhaojian

The Second XiangyaHospital, Central South University

Purpose: To evaluate the feasibility and reconstructive efficacy of chimeric flaps pedicled with lateral circumflex femoral vessel (LCFV) for the reconstruction of through-and-through oral and maxillofacial defects.

Methods: A retrospective review was performed of 41 patients who underwent reconstruction of through-and-through oral and maxillofacial defects with chimeric flaps pedicled with LCFV from January 2009 through December 2012 in the Second Xiangya Hospital. The methods of chimeric flaps design and defects reconstruction, as well as reconstructive efficacy, are reported.

Results: Of the 41 chimeric flaps, 29 were chimeric anterolateral thigh (ALT) and ALT flaps, 12 were chimeric ALT and anteromedial thigh flaps, with flap sizes ranging from 5 cm × 8 cm to 9 cm × 11 cm. The chimeric flaps provided separated flaps to reconstruct the intraoral mucosa and extraoral skin defects. Forty of 41 cases of chimeric flaps survived completely, providing a success rate of 97.6 per cent. All patients were followed for approximately 6 to 48 months, and they were satisfied with the

aesthetic and functional results of the donor and recipient sites after the reconstruction.

Conclusion: Chimeric flaps pedicled with LCFV are a good choice for the reconstruction of through-and-through oral and maxillofacial defects.

Key words: Lateral circumflex femoral vessel; Chimeric flaps; Oral and maxillofacial region; Defect

10

Application of PFM Crowning Techniques To Restore Multiple Adult Stuck Teeth with Large Scattered Clearance

Guo Ling, Li Wangyang , Huang Yao

Stomatology Hospital Affiliated to Luzhou Medical College

Purpose: The purpose of this presentation is to present the results of applying PFM crowning techniques to restore multiple adult stuck teeth with largely scattered clearance.

Methods: Lack of permanent tooth germ would result in multiple adult anterior teeth stranded and wide gaps with canine crossbite. The approach adopted to restore these stuck teeth includes three steps: 1: Correct the malocclusion by orthodontic treatment,2: Apply PFM bridge to restore maxillary teeth 3: Apply union crown to restore deciduous teeth due to short root and wide gaps.

Results: Multiple wide scattered clearances were corrected successfully in a short period. The deciduous tooth was kept while the gaps were closed at the same time. The function of aesthetics and language were fully restored.

Conclusion: The combination of orthodontic treatment with restoratory treatment can be effectively used to restore the teeth with large gap and multiple teeth stranded. It has the advantages of keeping the deciduous tooth while closing the gaps and fully restoring the aesthetics and language.

11

Experience of Clinical Details in Restoration for Unilateral Maxillary Defect with Maxillary Obturator

Yang Huochuan, Qiu Xingchun, Li Yan

Guanghua School of Stomatology, Hospital of Stomatology, Sun Yat-sen

Purpose: The difficulties of clinical operation in restoration for maxillofacial defect with prostheses enlarge as the complexity of defect increase. This article summarized the experience of clinical details in a case which restoring unilateral maxillary defect with maxillary obturator.

Methods: 6 months after the resection of partial maxillary bone, the patient（18-year-old,female）with unilateral maxillary defect, was rehabilitated with an maxillary obturator. We made the best of every undercut buccally or lingually by designing the clasps appropriately. The protection of the abutment teeth was also considered the occlusal force putting on the prostheses. In this case, linked crowns were used for protection of the further damage in the alveolar bone of the abutment teeth. As a result of tissue defect in the palate, chokes coughs usually occur during teeth preparations which increase the difficulty of clinical operation. In this case, rubber dam was used and patient felt much more comfortable during the treatment.

Results: As a result of this appliance, the masticatory function was improved and pronunciation was much clearer. The retention and stability of the prostheses were good while the aesthetic result was satisfactory.

Conclusion: Attention to the clinical details was very important in restoring unilateral maxillary defect with maxillary obturator successfully.

Key words: Maxillofacial defect; Obturator; Restoration

12

Genetic Investigation of Bisphosphonate-Related Osteonecrosis of Jaw (BRONJ) via Whole Exome Sequencing and Bioinformatics

Jee Hwan Kim , Yong Jae Ko, Jae Hoon Lee, Jin Kim, Ji Hyun Lee, Dong Hoo Han

Department of Prosthodontics, Yonsei University

Purpose: Bisphosphonate-related osteonecrosis of jaw (BRONJ) is one of the complications linked to the consumption of BP. Not all patients prescribed with BP experience BRONJ and it is multigenic disease possibly affected by both environmental and genetic factors. The purpose of this study is to discover genetic biomarkers associated with BRONJ via WES followed by statistical analysis and protein functional network study.

Methods: 16 individuals who have been diagnosed with BRONJ were chosen and each individual's saliva sample was collected by OG-500 (DNA Genotek, Ottawa, Ontario, Canada) for whole exome sequencing (WES) (Agilent SureSelect Human All Exon 50 Mb kits). Saliva sample was taken for massive sequencing and SnpEff, 1000 genomes project East Asian population, 126 healthy Korean randomized subsample originally recruited for thyroid cancer (GSK project), and Polyphen were used to filter out common variants from 16 individuals' whole exome sequencing data. Common variants with minor allele frequencies (MAF) >= 0.05 from all control datasets were eliminated and different impacts (high, moderate and loss of function) were used for comparison. Bioinformatics study by gene set enrichment analysis (GSEA) and network analysis was done to detect various genes and gene sets associated with BRONJ.

Results: Total of 118,856 variants were detected and 2,180 which is equivalent to 1,866 genes was recovered after the filtering step. Bioinformatics study revealed possible gene sets related to risk of developing BRONJ. Domains including, cell adhesion, cadherin, laminin/lectin, actin cytoskeleton, fibronectin and extracellular matrix were distinctive from GSEA. The protein functional network study composed of terms related to cell adhesion, cell morphology and apoptosis. Known genes associated to BRONJ from previous studies have been tested for presence in current study and only RBMS3 was detected from current study.

Conclusion: Our results suggest that various genes and gene sets involved in cell adhesion, morphology and apoptosis take pivotal role in developing BRONJ in patients with Bisphosphonate medication history.

Key words: Bisphosphonate; BRONJ; Whole Exome Sequencing (WES); gene set enrichment analysis (GSEA); network analysis

13

The Protection and Evaluation in Epilepsy Patients after A Fixed Partial Denture

Zhang Yufeng, Sun Xiaolin

Stomatology Hospital of Jilin University

Objective: To evaluate the application of the bruxism splint after fixed partial denture in epilepsy patients.

Methods: Female,42 years old,11,12 and 22 missing. The patient had been suffering from epilepsy. Seizure frequency was 1 to 2 times a month. Because of the long-term use of antiepileptic drugs, she h as been unresponsive and has a poor self-care ability. In the process of treatment, the doctor had a

variety of difficulties for her uncooperation and the seizures of epilepsy caused by the pain and discomfort. So, we asked her to take antiepileptic drugs before operating , and finished the fixed denture under her optimum status. At the same time, we gave her a bruxism splint in order to avoid damage to natural teeth and dentures when seizures.

Results: After 54 months follow-up, we didn't find any damage to the natural teeth and dentures with seizures for more than 60 times(we changed the bruxism splint 4 times).The long-term effect was significant. And the patient was satisfied with her prostheses.

Conclusion: The bruxism splint after fixed partial denture rehabilitation in epilepsy patients has a protective role of natural teeth and dentures, so the bruxism splint should be widely applied in clinic for epilepsy patients.

14

Effect of Cleaning Methods on Mechanical Properties of Prostheses Silicone Rubbers

Wang Junjie

Guanghua School of Stomatology, Hospital of Stomatology, Sun Yat-sen University

Purpose: To evaluate the effect of different cleaning methods on the mechanical properties of two silicone rubbers used for maxillofacial prostheses, and to make recommendations for clinical use.

Methods: 2mm-thickness pigmented strips of A-2000 and ZY-1 silicone rubbers were prepared. 35 dumb-bell shaped specimens were cut from strips, which were used for Shore A hardness test, tensile test, percentage elongation test and permanent deformation calculation. 35 crescent specimens were made in the same way, which were used for tear test. All dumb-bell and crescent specimens were randomly divided into 7 groups, 10 for each group (5 for each shape), to be processed as below: (1)Group IPA: Immersed inIsopropyl alcohol for 6h, simulating the total immersion time of 1 year with l min everyday. (2)Group Polident: Immersed in Polident solution for 90h, simulating the total immersion time of 1 year with 15 min everyday. (3)Group Cleansoft: Immersed in Cleansoft solution for 18h, simulating the total immersion time of l year with 3 min everyday. (4)Group Steradent: Immersed in Stemdent solution for 60h, simulating the total immersion time of l year with 10 min everyday. (5)Group distilled water: Immersed in distilled water for 60h, simulating the total immersion time of l year with l 0 min everyday. (6)Group empty: Kept from light at room temperature for 60 h. (7) Group pre-treatmen Tested immediately after preparation.

Results: 1. ZY-I had significantly higher tear strength than A-2000 in all groups ($P<0.05$). There was no significant difference in other tested mechanical properties (Shore A hardness, tensile strength, percentage elongation and permanent deformation) between the two silicone rubbers($P>0.05$).

2. For each silicone rubber, there was no significant difference in the Shore A Hardness, tensile strength, percentage elongation, permanent deformation and tear trength among different group ($P>0.05$).

Conclusion: The mechanical properties of A-2000 and ZY-1 silicone rubbers were not significantly influenced with different cleaning methods.

Key words: Maxillofacial Prostheses; Silicone Rubber; Mechanical Properties; Cleaning Method

15

The Reaserch about The Relationship between Three Brand of Zironic Ceramic Trancemittance and Color

LI Chen, Wang Dalin, Wang Shaohai

Department of Stomatology, Changhai Hospital, Second Military Medical University, Shanghai

Purpose: To introduce a new indicator to the Colorimetric system so as to provide experimental basis and to simulate natural dentin color much better, we analyze the relationship among zirconia dental ceramic materials and light transmittance of L*, a*, b* and thickness.

Methods: Using X-rite color i7 spectrophotometer, three brands (Lava, Upcera, Doceram) zirconia ceramic transmittance and reflectance (L*, a*, b*) were measured of different colors, different thickness (0.9mm, 0.6mm, 0.3mm), the results were analyzed by using SPSS18.0 software, t[1]o investigate the linear transmittance between the thickness and the color value.

Results: 1,The difference among the three brands of zirconia ceramic transmittance was not statistically significant (p>0.05), while the transmission of three kinds of thickness of zirconia ceramic was statistically significant (p<0.05). 2、the transmittance range of 0.9mm zirconia ceramic rate was 13.63~27.47； the transmittance range of the 0.6mm zirconia ceramic rate of 18.05~33.96, the transmittance range of 0.3mm zirconia ceramic rate of 25.24~39.73. 3、There is a linear relation among transmittance、thickness and color value of the three brands of zirconia ceramic，Upcera：TT=0.366*L*-thickness*0.661-0.280*b* ;Doceram:TT=0.524*L*-0.536*thickness-0.237*b*;Lava:TT=0.210*L*-0.610*thickness-0.164*b*.

Conclusion: Three brands of zirconia ceramic transmittance range do not have the remarkable difference, with the increase of thickness, transmittance decreases. With the increase of luminance the transmittance increases gradually, while the zirconia ceramic is bluer, the light transmission is higher. Therefore, in the all ceramic restoration process, the introduction of transmittance is important to investigate the correlation between the transmittance and color, and redefine the natural tooth color perception and representation.

Key words: Zirconia ceramic; Transmittance; Color

16

Correlation between Autophagy and Apoptosis in Oral Carcinoma IL-24 Gene Therapy

Li Jichen

Department of Oral and Maxillofacial Surgery, the First Affiliated Hospital of Harbin Medical University

Purpose: To study the role of autophagy in the IL-24-induced apoptosis in oral carcinoma. Improve the effect of IL-24 gene therapy of oral carcinoma by inhibiting autophagy.

Methods: In this study, apoptosis induced by IL-24 in human oral squamous cell carcinoma cell line (KB) was measured using the MTT assay, flow cytometry and Caspase-Glo®3/7 Assay. Autophagy activation induced by IL-24 was revealed Transmission Electron Microscope, monodansylcadaverine (MDC) staining, GFP-LC3 fluorescence and western blot assay of microtubule-associated protein 1 light chain 3 (LC3).

Results: By MDC staining, GFP-LC3 staining, Transmission Electron Microscope, Western blot confirmed IL-24 not only induced apoptosis in oral carcinoma cells, but also induced autophagy in the meantime. In addition, use 3-MA inhibited the IL-24-treated oral carcinoma cells can cause survival rates decline, increased caspases activity and increased apoptosis rate.

Conclusion: Our results indicate that in human oral carcinoma, IL-24 gene therapy causes autophagy

activation to protect cancer cells from apoptosis. In conclusion, autophagy inhibition could have promising potential as IL-24-based gene therapy against oral carcinoma.

Key words: IL-24; Gene therapy; Autophagy; Apoptosis; 3-MA

17

Effect of Different Surface Treatments on Bonding of Silicone Elastomer to Acrylic Resin

Li Xiaona

Dalian Stomatological Hospital

Purpose: To evaluate the effect of surface treatments on the bonding of silicone elastomer to acrylic resin.

Methods: 56 acrylic resin strips were polished with 600-grit silicon carbide paper and divided randomly into 4 groups. The bonding surface was pretreated with the following methods: Application of Primer (Group C), Primer after sandblast (Group S), Primer after immersion in methyl methacrylate (Group M), Primer after sandblast and immersion in methyl methacrylate (Group SM). 28 overlap-joint models were made and tested by universal test machine. Seven specimens were fabricated for each of 4 groups. Failure loads and failure style were assessed for all specimens. The effect of different treatments on acrylic resin surfaces by portable surface analyzer and scanning-electron microscopy (SEM) were also determined.

Results: Group SM recorded the highest shear bond strength. This is followed by Group S, Group M and Group C, respectively. Significant differences were found among the treatment categories ($p<0.05$). All specimens in each group showed cohesive failure of the silicone elastomer. Group S demonstrated significantly higher surface roughness values compared to Group C ($p<0.05$). No differences were present between Group SM and Group S, Group M and Group C. SEM images reported that sandblast and MMA treatment produced significant surface texture changes of the acrylic resin.

Conclusion: Treatment of acrylic resin by sandblast and MMA immersion can improve the adhesion between maxillofacial silicone elastomer and acrylic resin.

Key words: Silicone elastomer; Acrylic resin; Surface treatment; Shear bond strength

18

Preliminary Clinical Study on Application of Computer-Assisted Surgery Technique in Maxillary Defect Reconstruction

Liang Jie, Shan Xiaofeng, Huang Jinwei, Zhang Lei, Cai Zhigang

Department of Oral Maxillofacial surgery, School of Stomatology, Peking University

Purpose: Maxillary defect caused by tumor, trauma, and congenital deformity shade great influence on patients' function and aesthetics, affecting their quality of life. As the development of Computer-Assisted Surgery (CAS) technique became widely applied in Oral-Maxillofacial Surgery, the reconstruction of maxillary defect is heading for a more precise and individualize criteria. This study plan to compare different CAS method applied in maxillary reconstruction, in order to draw a workflow for each method, evaluate their advantages and disadvantages and their clinical application value.

Methods: 12 cases were included in this study , which received CAS assisted maxillary defect reconstruction surgery during Mar.2012 – Mar.2014. Including the Navigation guided 3D-printed Titanium Mesh Group: 2 cases, the Navigation guided 3D-printed Model Induced Pre-formed Titanium

Mesh Group: 5 cases, the 3D-printed Model Induced Pre-formed Titanium Mesh Group, 2 cases, the 3D-printed Model and Navigation Guided Group, 2 cases, the 3D-printed Model combined Surgical Stent Group, 1 case. The CT scan would be obtained in all patients pre and post-operatively. The models of pre-and –post operation were introduced into Geomagic Qualify 12.0, analyzed in 3D compare function, report of the deviations were obtained.

Results: All patients in 5 groups achieved satisfying functional and aesthetical reconstruction outcome. All cases were able to take semi-fluid food to normal food, with normal swallowing and speaking function, with normal eye movement and vision. The 3D compare deviation indicating: groups adapting navigation technique show lower standard deviation than non-navigation groups; when reconstructing a defect that involves multiple facial anatomy landmarks, the 3D-Printed titanium mesh showed smaller deviation with multiple buttress reconstruction and shorter operating time; the 3D-printed model induced pre-formed titanium transfer the VSP more directly. Using 3D compare to evaluate the repeatability of each transfer method, we found that Navigation surgery provided more stable results; while compared to normal titanium mesh, the individualized printed titanium mesh showed advantages on reconstructing large defect that relating multiple vital aesthetical landmarks with milder deviation and shorter surgical time cost. Complications were mainly about: flap loss in 1 case, tumor recurrence in 1 case, epiphora in 5 cases, ectropion in 1 case, wound dehiscence in 1 case, infection in 1case.

Conclusion: 1. The feasibility of CAS adapted in Maxillary Defect Reconstruction was proved.2. Computer assisted surgery technique helps improving the safety, stability and accuracy in reconstruction surgery of Brown Class II-V Defects.3. Each transfer method has its advantages: (1) Navigation Surgery helps to control the safety, stability and accuracy of surgery. (2) Rapid prototyping manufactured model helps directly reflecting the VSP. (3)Surgical stent indicates the position of grafts, facilitating the fixation.(4) 3D-printed titanium mesh is beneficial in complex defects reconstruction, helping to achieve precise and individualized reconstruction outcome.

Key words: Computer assisted surgery; Navigation Surgery; Rapid prototyping; 3D-printed Titanium Implant; Surgical Template; and Maxillary Defect Reconstruction

19

High Expression of NBR1 Proteins May Be Associated with Epithelial-mesenchymal Transition (EMT) in Keratocystic odontogenic tumours

Liu Bing, Man Qiwen, Chen Gang, Zhao Yifang

Department of Oral and Maxillofacial Surgery, School and hospital of Stomatology, Wuhan University, China

Purpose: The aim of this study was to evaluate the expression of NBR1 in keratocystic odontogenic tumours (KCOT), and also to investigate its possible relationship with epithelial-mesenchymal transition (EMT) which has an important indication of invasion.

Methods: We detected the expression levels of NBR1 and some key EMT-related proteins (Snail, Slug, Twist, E-cadherin, and N-cadherin) in clinical samples of KCOT and radicular cysts by immunohistochemistry and then detected their mRNA expression by real-time quantitative polymerase chain reaction (qPCR). The correlation between NBR1 and the tested EMT-related proteins in KCOT was explored using Spearman's rank correlation, followed by cluster analysis.

Results: The results showed that both the immunoreactivity and mRNA expression of NBR1 tested were considerably increased in samples of KCOT compared with those in samples of radicular cysts.The correlation analyses showed that the immunostains of EMT-related proteins in samples of KCOT correlated closely with each other.The immunostains of these EMT-related proteins also correlated closely with the immunostains of NBR1 in KCOT.More importantly, double-labelling immunofluorescence analyses also showed that the distribution of NBR1 and E-cadherin was partially synchronous in the samples of KCOT.

Conclusion: In conclusion, our results suggest that the high expression of NBR1 in KCOT has possible

association with the invasive behavior.

Key words: NBR1; Keratocystic odontogenic tumour; EMT-related proteins; Invasive

20

A Survey of Motivation and Psychology of Implant Treatment of 60 or Older Habitant in Panzhihua

Lv Linhu，Zhou Hui，Guo Ling

School of Stomatology，Luzhou Medical College

Purpose: To understand the motivation for implant treatment of people over the age of sixty in Panzhihua and predict their subjective needs for implant treatment.

Methods: Simple random sampling method was adopted and a face-to-face interview was conducted with the 60 or older at some public sites using a questionnaire to gather the baseline data for the subsequent evaluation．Data entry and statistical analysis were completed by Epidata 3.0，and SPSS 13.0 respectively．

Results: A total of 300 questionnaires were handed out for face-to-face interview and 294 questionnaires were returned（efficiency 98%）．Men on the number of missing teeth than women, the difference has statistical significance. The motivation of planting treatment affected by gender, age, education level.71.4% of the respondents don't choose to implant after edentulous, 82.6% of the respondents think good teeth is to give people a nice impression in the communication in modern society.

Conclusion: The motivation of implant treatment of older people is influenced by gender, age and academic level. Edentulous will affect the physical and mental health of the old man and is a barrier to get a nice impression in social activities.

21

The Expression of Neuropeptide Y Was Regulated by Coticosterone and Acetylcholine Via Respective Receptors in The Osteocytic MLO-Y4 Cells

Ma Yuanyuan*1, Wang Hang2

1 Guanghua School of Stomatology, Hospital of Stomatology, Sun Yat-sen University; Guanghua School of Stomatology, Hospital of Stomatology, Sun Yat-sen University

2 State Key Laboratory of Oral Diseases, West China Hospital of Stomatology; Department of Prosthodontics, West China College of Stomatology, Sichuan University

Purpose: Neuropeptide Y (NPY) is a potential modulator of bone remodeling. It is unknown whether its expression is related with specific biochemical stimulations. Then, we investigated the effects of corticosterone and acetylcholine (ACh) on the expression of NPY in the MLO-Y4 cells.

Methods: (1)MLO-Y4 cells were incubated with corticosterone and/or RU486 for 1, 3, 6, 12 and 24 h; (2) MLO-Y4 cells were treated by ACh and/or receptor antagonists including atropine, mecamylamine and d-tubocurarine for 1, 2, 3, 4 and 5 days; (3)Then we detected the viability and proliferation of cells, as well as the gene and protein expression of NPY by real-time PCR assay and western blotting analysis respectively.

Results: (1)Corticosterone significantly reduced cells viability and upregulated the NPY expression at the gene and the protein levels in a time-dependent manner, which were reversed by RU486. (2) ACh

significantly induced cells viability and proliferation and reduced the expression of NPY mRNA, which was reversed by the pretreatment of receptors antagonists; ACh had no significant effects on the NPY protein.

Conclusion: Corticosterone and ACh could regulate the cell viability and NPY expression in osteocytes via respective receptors. There is possible casual relationship between the cell viability and NPY gene expression, which needs further study.

Key words: Corticosterone; NPY; Osteocytes; Acetylcholine

22

The Approach of Tongue Pressure Measurement for Making Palatal Augmentation Prosthesis

Shigehiro Fujiwara, Takahiro Ono, Yoshitomo Minagi, YoshitsuguTokuda, Kazuhiro Murakami, Kazuhiro Hori, Yoshinobu Maeda

Dept. of Prosthodontics, Gerodontology and Oral Rehabilitation, Osaka Univ. Grad. Sch. of Dent

Purpose: Although the palatal volume of palatal augmentation prosthesis (PAP) is often designed with soft waxes or tissue conditioning materials, it is difficult to know precisely about tongue-palate contact. This report describes the attempt to determine the palatal volume by reference to tongue pressure production with the tactile sensor sheet system.

Method: A 61-years-old male patient was extracted two thirds of right dorsum of tongue and grafted a flap of the thigh because of tongue cancer and had eating and swallowing disorders after the operation.

Results: First, both new dentures were made because of ill-fitting old dentures. At the step of try-in, the palatal volume was given with a soft wax by reference to a pressure indicating material. But problems of food residue at palate were remained. And so tongue pressure production, which consisted duration, maximum pressure of tongue-palate contact, was measured with tongue pressure measurement system, then it was shown that too much contact between grafted flap and palate inhibited tongue movement. After modify palatal volume by reference to this result, the problem was resolved.

Conclusion: It was suggested that tongue pressure measurement was useful for designing the palatal volume of PAP

Key words: PAP(palatal augmentation prosthesis); Maxillofacial prosthesis; Tongue; Tongue pressure; Dysphagia

23

Impression Technique for A Maxillofacial Pass-through Defect with Limitation of Mouth Opening:A Case Report

Zou Shiquan, Ren Weihong, Liu Peng

Stomatological hospital of Capital medical university

Purpose: To acquire the impression of the defect area with limitation of mouth opening, so that the silicon obturator fabrication can be followed

Methods: Because of the limitation of mouth opening, the impression of the defect area can only be acquired through the facial pass-through defect area. And also because of the existence of massive undercuts, the polysiloxane impression should be hollow for the removal and future gypsum perfusion. Gauze, injected polysiloxane impression material and a little balloon were employed for this purpose.

Results: The impression of the defect area was successfully acquired for the fabrication of silicon

obturator

Conclusion: For patients suffer from maxillofacial pass-through defect accompany with limitation of mouth opening, impression technique can be confusing. Different instrument and methods can be applied.

24

Contributing Factors for Abutment Teeth Survival on Obturator Prostheses

Shogo OZAWA, Kana MAKIHARA, Fumi YOSHIOKA, Shin MIYAMAE, Yoshinobu TANAKA

Aichi Gakuin University, School of Dentistry, Removable Prosthodontics.

Purpose: We have reported long term clinical observation of abutment teeth on obturator prostheses in the last ISMR meeting at New Mexico. In order to gain retention and stability of obturator prosthesis are mostly relied on abutment teeth, so that excessive load should be applied to the abutment teeth. The aim of this study was to assess contributing factors for survival of abutment teeth on obturator prostheses.

Methods: Ninety nine patients who were treated in Maxillofacial Prosthodontic Clinic, Aichi Gakuin University Dental Hospital were enrolled in this study. Those who were followed less than three years were excluded to demonstrate long-term clinical outcomes. Maxillary defect configuration (Aramany's classification), the number and kinds of retainers, followed up periods of abutment teeth, irradiation history and number of remaining teeth were surveyed using the medical record and the clinical protocol. Statistical analysis was performed using Kaplan-Meier method and Log-Rank test.

Results: Total of one hundred and sixty nine prostheses and four hundred and thirty eight abutment teeth were studied. Average observation period is seven years and six months, and the longest case is thirty one year's follow up. Overall survival rate of the abutment teeth were 80.1 %. The statistical analysis showed significant longer prognosis of abutment teeth was seen in Class I and II as compared to Class IV patients. As for the kinds of retainer, there were no significant differences in longevity among the retainer designs. Irradiated abutment teeth are significantly lower survival rate and cases of more than seven remaining teeth are significantly higher survival rate.

Conclusion: Our survey revealed that survival rate of abutment teeth on obturators is 80.1 % in which average observation periods is 7.5 years. Contributing factors of the teeth survival are defect size and location, irradiation history and number of remaining teeth in a jaw.

Key words: Obturator; Abutment teeth; Long term observation; Survival rate

25

EPCs Transplantation for Microvascular Repair in Irradiated Tissue

Wu Shuyi, Chen Jiangfei, Wei Hongbo, Bai Shizhu, Zhao Yimin

School of Stomatology, Fourth Military Medical University; Guanghua School of Stomatology, Hospital of Stomatology, Sun Yat-sen University

Purpose: This study tried to investigate the therapeutic potential of EPCs in treatment of irradiated tissue ischemia in vivo, hoping to provide a new way to improve the ischemic state of the irradiated tissues.

Methods: EPCs were separated from the bone marrow of F344 inbred rats and then purified by colonies selection. Before transplantation, we constructed the lenti-EmGFP and transduced the EmGFP gene into the EPCs. With the purpose of finding the right time for EPCs transplantation, we used the

irradiated lower left hindlimb in F344 rat for the animal model and investigated the histological changes and the expression levels of SDF-1, ICAM-1, VCAM-1 and E-selectin. In the selective time, we transplanted EPCs into the F344 rat via tail vein injection. 8 weeks after transplantation, we observed EPCs homing situation through immunofluorescence staining of the left medial grastrocnemius frozen sections and studied the blood flow change through microangiography and microCT scanning.

Results: Flow cytometry analysis showed the cells were positive for a panel of markers, including CD34(2.45%), CD144(95.8%) , CD31(80.9%)and VEGFR2(46.6%). Also the cells were positive for vWF immunofluorescence staining , DiI-AcLDL uptake, FITC -UEA-1 binding, Weibel-Palade body containing, and could form tubular-like structures in matrigel. After EmGFP gen transduction, more than 90% EPCs could be successfully labeled when the MOI was 50. When the lower left hindlimbs of the F344 rats were irradiated, inflammatory reaction mainly disappeared 3 weeks after radiation, but the expression of SDF-1, ICAM-1, VCAM-1 and E-selectin kept in high levels. Thus, we selected this time to be a relative right time for EPCs transplantation. 8 weeks after cells transplantation, we found EPCs could successfully home to the irradiated tissue and contribute to microvascular repair, helping to improve the blood flow in irradiated region.

Conclusion: This study proved that EPCs transplantation could enhance the microvascular repair in irradiated tissue. It would be a new method to solve the ischemia problem after irradiation, and worth further investigation.

Key words: Endothelial Progenitor Cells (EPCs); Radiotherapy; Homing

26

Molecular Mechanism and Potential Roles of TNF-α-enhanced Fusion between Oral Squamous Cell Carcinoma Cells and Endothelial Cells

Yan Tinglin, Shang Zhengjun

Stomatology of wuhan university

Purpose: Uncover a new insight into the molecular regulation and signal transduction mechanisms responsible for TNF-α-promoted oral cancer-endothelial cell fusion, and provide valuable insights for current and future in potential mechanism underlying tumor angiogenesis.

Methods: 1.Reverse transcription and RT-PCR2.Protein extraction and Western blot analysis 3.immunofluorescence4.hybridization in situ

Results: 1. TNF-α increased the expression of syncytin-1 and ASCT-2 on SCC-9 and HUVECs respectively 2. The expression of syncytin-1 is relative to the Wnt/β-catenin signaling pathway.

Conclusion: TNF-α promote cancer-endothelial cell fusion through Wnt/β-catenin activation-mediated upregulation of fusogenic protein syncytin-1.

27

Application of the Prosthesis with Titanium Framework and Functional Impressiontechnique in The Reconstruction of The Unilateral Maxillary Defect

Tong Ling, Li Suling, Wang Lu

Stomatological hospital of Chongqing medical university

Purpose: To investigate the clinical application and effect of the prosthesis with titanium framework and functional impression technique in there construction of the unilateral maxillary defect.

Methods: We had selected ten cases which used the obturator prosthesis with titanium framework and functional impression technique to observe the therapeutic effect. Masticatory efficiency test and speech intelligibility test and clinical effect evaluation of self were conducted to evaluate the functions of mastication and speaking.

Results: The prosthesis with titanium framework was excellent in biocompatibility, light in weight, small in volume, comfortable in feeling; the clasps had better elasticproperty and provided enough retention that they can decrease the stress of abutments and residual ridge to protect them.

Conclusion: The prosthesis with titanium framework and functional impression technique can improve partly function of the speeching, swallowing, sucking and masticating of the patients of unilateral maxillary defect.

28

The Role of Sclerostin in Mediating Alveolar Bone Remodeling in Response to Tooth Loss

Wang Lufei, Deng Meng, Bai Ding, Han Xianglong

Department of Orthodontics, State Key Laboratory of Oral Diseases, West China Hospital of Stomatology, Sichuan University

Purpose: Tooth loss is a common and serious clinical issue. When tooth is missing, the lack of normal functional occlusion (occlusal hypofunction) would lead to a reduced alveolar bone mass, which is very crucial in dentofacial rehabilitation. However, the related molecular mechanism has not been fully identified. Since occlusal hypofunction can be considered as a kind of unloading environment, in view of the important role of sclerostin in mediating unloading-induced bone remodeling, we conducted the present study to investigate the characteristic of sclerostin in tooth loss-induced alveolar bone loss.

Methods: Eight 10-week male Sprague-Dawley rats were used for this experiment. The unilateral maxillary molar was extracted while the homolateral upper incisor was abraded, aiming to induce occlusal hypofunction. For each rat, extraction side (occlusal hypofunction) and non-extraction side (control) were set as self-control comparison. 8 weeks after tooth extraction, the rats were sacrificed and the specimens were collected for analyses. We applied X-ray and micro-CT for alveolar bone histomorphometric evaluation, and HE staining for histological evaluation. Osteoclast number was calculated by Tartrate-resistant acid phosphatase (TRAP) staining, while expressions of sclerostin and β-catenin were assessed by immunohistochemistry staining.

Results: Apparent bone loss and architecture deterioration were observed at occlusal hypofunction side by X-ray, micro-CT and HE staining. Compared with control side, bone mineral density of hypofunction side was decreased dramatically, and the ratio of bone volume to total volume was significantly lower ($P < 0.001$). Similarly, compared with control side, TRAP staining showed a higher number of osteoclast at hypofunction side ($P < 0.001$). In addition, the expression of sclerostin was increased while β-catenin was decreased when functional occlusion was lacking.

Conclusion: This study preliminarily elucidates the role of sclerostin in mediating alveolar bone remodeling in response to tooth loss. Based on the current findings, it is indicated that sclerostin and Wnt/β-catenin signal are closely associated with tooth loss-induced alveolar bone loss. Anti-sclerostin treatment may be considered as a promising therapeutic strategy in preventing tooth loss-induced alveolar bone loss, and it would obtain widespread application in dentofacial rehabilitation.

29

Measurement and Analysis of The Distribution Range of Chroma Values of Healthy Anterior Gingival in Han Population

Wang Shaohai, Wang Dalin, Li Chen, Li Hongjiao, Xu Lijuan, Jiang Caidi

Department of Stomatology, Changhai Hospital, Second Military Medical University, Shanghai

Purpose: In order to get the current distribution range and distribution characteristics of Chinese Han population healthy anterior gingival color chroma values , the gingival color value of healthy Han people and the effects of gender、age、region and areas on it were investigated .

Methods: 400 healthy Han people were chosen from 5 major cities (Beijin Shanghai,Guang zhou,Henan,Xi'an) , and chroma value of their arterial gingival color were measured and analyzed with MINOLTA CR-321 clorimeter .

Results: 1、In the comparison of different region of gingival color chroma value，The a* values of attached gingiva between the root of two teeth and distal incisor attached gingiva has no significant difference（0.02＜P＜0.05）; the b* values of mesial incisor gingival papilla and distal incisor attached gingiva has no significant difference（p＞0.5）; the gingival color chroma values of the rest areas have statistical significant differences（p＜0.001）.The color difference ΔE between various parts was＞2；2、There was no significant difference on Chinese Han population healthy anterior gingival color by area（P＞0.01，ΔE＜2）；3、Chroma values of Chinese Han population healthy anterior gingival color was measured by age, multi group comparison results of a* values and b* values showed no significant difference（p>0.01）, while there are significant differences between groups of L* value（p=0.012＜0.05），by a further pairwise comparison，the difference between Group 18-29（P＜0.01）and group 30-39and difference between group 30-39 and group 40-49（P=0.023）had statistical significance. 4、There was significant difference on Chinese Han population healthy anterior gingival color by gender（ΔE >2），statistically significant differences were found in L* value and b* value (P<0.001), there was no significant difference of a* value (P=0.666). 5、The range of chorma values of Chinese Han population was L* value:28.84～57.99，a*value:3.37～16.28，b*value:1.43～8.63.

Conclusion: This investigation reveals that there was no significant difference on color by area and age, while the difference in gingival color by region and gender was significant; The range of chorma values of Chinese Han population was L* value:28.84～57.99，a*value:3.37～16.28，b*value:1.43～8.63

Key words: Han; Healthy gingival; Color

30

Effects of A Hindered Amine Light Stabilizer on The Color Stability and Mechnical Properties of Maxillofacial Silicone Elastomer

Mo Wenjuan, Liang Qinye, Li Yan *

Guanghua School of Stomatology, Hospital of Stomatology, Sun Yat-sen University

Purpose: To evaluate the effects of a hindered amine light stabilizer on the color stability and mechanical properties of a maxillofacial silicone elastomer, and to explore an optimum dosage which ensures better color stability and benign mechanical properties.

Methods: The intrinsically pigmented SY-1 maxillofacial silicone rubber was divided into 8 groups on the basis of the additive ratio of the hindered amine light stabilizer Tinuvin123, which increased as 0.00%, 0.05%, 1.00%, 1.50%, 2.00%, 2.50%, 3.00%, 3.50% by weight. Specimens were made in plexiglass moulds at 70℃ for 1.5h and 26℃ for 24h in dark place.

Experiment Ⅰ: 80 columniform specimens (10mm diameter, 10mm height), 10 for each group, were picked out for the tests of color stability. All specimens underwent a 480h ultraviolet aging test. Chromatic values (L*a*b*) were measured before and after test and the color differences (ΔE) were calculated. Experiment Ⅱ: The silicone rubber sheets (2mm thickness) were made and cut into dumb-bell shape and right angle shape specimens. 80 dumb-bell shaped specimens, 10 for each group, were picked out for the tests of Shore A hardness, tensile strength, elongation at break and permanent deformation. Similarly, 80 acceptable right-angle shaped specimens were picked out for the tests of tear

strength.Data were analyzed with 1-way ANOVA, Jonckheere-Terpstra rank-sum test, Bonferroni, LSD, and Dunnett multiple tests (α=0.05).

Results: 1.The lightness value increased, the reddish degree lightened and the yellowish degree darkened as the mass ratio of Tinuvin123 rised. 2. The color difference (ΔE) value began to decrease significantly ($P<0.05$) once the dosage of Tinuvin123 reached to 1% by weight.3. The Shore A hardness began to increase significantly ($P<0.05$) once the dosage reached to 3.0% by weight.4. The tensile strength, the elongation at break and the tear strength began to decrease significantly ($P<0.05$) once the dosage reached to 2.5%, 3.0% and 3.5%, respectively. 5. The permanent deformation had no significant difference ($P>0.05$) when the dosage was not exceeding 3.5% by weight.

Conclusion: The color stability of the intrinsically pigmented SY-1 maxillofacial silicone elastomer can be improved through adding hindered amine light stabilizer Tinuvin123. The mass ratio of 2.0% by weight is an optimal dosage which would meanwhile ensure the benign mechanical properties.

Key words: Maxillofacial prostheses; Silicone elastomer; Hindered amine light stabilizer; Color stability; Mechanical properties

31

Intraoral Approach for Mandibular Benign Tumor Resection and Mandible Reconstruction with Non-vascularized Iliac Graft

Wu HanJiang

the Second Xiangya Hospital, Central South University

Purpose: To evaluate the feasibility and reconstructive efficacy of intraoral approach for mandibular benign tumor resection and mandible reconstruction with non-vascularized iliac graft.

Methods: A retrospective review was performed of 54 patients who underwent mandibular benign tumor resection and mandible reconstruction with non-vascularized iliac graft from January 2009 through December 2012 in the Second Xiangya Hospital. All the surgery were performed through the intraoral approach, and pretragal minimal incision was also made when the condylar process could be preserved. According to the UrKen's classification of mandibular defects, there were 10 cases of CRB, 22 cases of RBS, 3 cases of BSB, 15 cases of BS, and 4 cases of S, with defect sizes ranged from 3 cm to 13 cm. The homolateral or hibateral ilium was cut off accordingly to reconstruct the mandible en bloc or deblock, with a height of 3 cm. The ilium was fixed with titanium miniplates or reconstruction plates, and the intra-oral wounds were double-deck sutured with absorbable suture lines. Two drainage tubes were laid and exited from the back of submandibular region or opisthotic hairline. In 26 patients of the present series, digital surgical technic was applicated for the shaping of titanium plates.

Results: Of the 54 patients, wound effusion occurred in 2 patients, wound infection occurred in 3 patients, and delayed fistula of the wound occurred in 6 patients. Gradual wound healing was observed after daily wound dressings and / or secondary surgery in these 11 patients. All patients were followed for approximately 1 to 3 years, and they were satisfied with the esthetic and functional results of the donor and recipient sites after the reconstruction.

Conclusion: Intraoral approach for mandibular benign tumor resection and mandible reconstruction with non-vascularized iliac graft is a new surgical technic with several obvious advantages, including satisfactory esthetic and functional results, high success rate of non-vascularized iliac graft, and lower complication rate of the donor and recipient sites. The key steps of the surgical technic are tumor ressection, shaping of the titanium plates, iliac graft, fixation of titanium plates, and adequate wound drainage. Additionally, application of digital surgical technic is of great value in mandible reconstruction.

Key words: Intraoral approach; Tumor; Reconstruction; Iliac graft

32

The Role of MiR-136 in Osteocyte Autophagy Activated by Estrogen Deficiency in Ovariectomized Mice

Wu Junhua

School of Stamotology , Tongji University

Purpose: The Jaw bone loss is associated with osteoporosis induced by imbalanced estrogen levels. The response of osteocyte to estrogen play an important role in jaw bone absorption and homeostasis. The reduction of the osteocyte autophagy is one of the important reasons of osteopenia.miRNA also play an important role in the regulation of bone formation and absorption. In metabolic bone diseases such as osteoporosis, the miRNA dysfunction is an important pathological factor. According the effect and mechanism of miRNA, specific knockout of the target gene of miRNA may be one of the effective means for the treatment of metabolic bone disease.

Methods: First, we screened the miRNAs which were differentially expressed between the jaw bone of ovariectomized mice and that of normal mice by miRNA microarray. And found that 6 miRNAs were upregulated after OVX, whereas 4 miRNAs were downregulated. Among these miRNAs, miR-136 exhibited the greatest changes. To identify the mediation of miR-136 in the response of osteocyte to estrogen, we treated osteocyte-like MLO-Y4 cells with E2, and found that estrogen can rapidly inhibit the expression of miR-136, which suggests that miR-136 is involved in the response of osteocyte to estrogen. To further explore the relationship between miR-136 and osteocyte autophagy, we transfected the miR-136 mimics and inhibitors in osteocyte-like MLO- Y4 cells, and test the phos- phorylation of the key autophagy related protein Erk1/2 and the expression ofLC3-I/LC-3II by Western hybridization.

Results: Overexpression of miR-136 canupregulate the phos- phorylation of Erk1/2 in osteocyte-like MLO-Y4 cells, while inhibition of miR-136 canget the opposite result. Moreover, overexpression of miR-136 enhanced autophagy, and inhibition of miR-136 decreased autophagy.

Conclusion: MiR-136 is involved in the MAPK/ERK pathway activated by 17-β estradiol receptor, andenhance autophagy activity in osteocyte-like MLO-Y4 cells. This study may provide a newidea and theoretical basis for therapeutic targets of mandible osteoporosis.

Key words: Osteocyte; Micro-RNA; Autophagy

33

Increasing the Success Rate of Impression for Rehabilitation of Maxillofacial Defects with Prostheses through Nursing Care

Guanghua School of Stomatology, Hospital of Stomatology, Sun Yat-sen University

Zhang Xueling

Purpose: To explore the effect of nursing care on increasing the success rate of impression for rehabilitation of maxillofacial defect with prostheses.

Methods: Before impressing for maxillofacial defect, a deep communication between maxillofacial prosthodontist, nurse and patient was needed, in order to make a comprehensive treatment plan. Based on the plan, the nurse should provide detailed and directed nursing care, including the patient's psychological care, mouth-opening training, breathing training before impressing and selection of impression material, etc.

Results: The first success rate of impression for maxillofacial defects rose remarkably from 50% to 82% through the nursing care and operation ways listed above.

Conclusion: Detailed and directed nursing care could raise the impression success rate of rehabilitation of maxillofacial defects with prostheses, as well as the comfort of patient and the working efficiency of maxillofacial prosthodontist.

Key words: Nursing care; Impression; Prostheses; Maxillofacial Defect

34

Reconstruction of Hard and Soft Palate Defect with Dysarthria Dyspagia : A Case Report

Yamamoto Masaaki[1]*, Ono Takahiro[1], Sato Shizuka[2], Nago Shotaro[2], Kumakura Isami[2], Maeda Yoshinobu[1]

1 Osaka University Graduate School Of Dentistry, Suita, Japan

2 Senri Rehabilitation Hospital, Minoh, Japan

Purpose: The maxillofacial defects lead to dysarthria and dysphagia in many cases. We usually treat with dento-maxillary prosthesis with obturator for these cases. This report presents an application of dento-maxillary prosthesis with a long-shaped obturator extended posterosuperioly in maxillectomy patient with hard and soft palate defect.

Method: The patient is fifty-five years old man, who was affected by the carcinoma (T4aN2cM0) of maxilla, with hard and soft palate defect in other hospital. He was treated with radiation therapy (60gy) after surgery. He had dysarthria and dysphaiga stemming from pharyngeal contraction failure and silent aspiration.

Results: The dento-maxillary prosthesis was applied to the patient. First, although the prosthesis was attached with normal-shaped obturator for hard and soft palate defect, the functional disorder has not improved. After that, the prosthesis attached PLP or Bulb-PLP, or nasal speaking valve (NSV) was applied, but he felt strongly against these attachments and could not apply. Finally, the prosthesis attached a long-shaped obturator extended to the posterior wall of pharynx from inside the defect was applied, and dysarthria and dysphagia has improved. In addition, Swallowing training with thick has done for dysphagia.

Conclusion: It was suggested that the obturator was useful for pharyngeal contraction failure, but that this treatment was insufficient for other function. Further prosthetic treatment is under consideration.

Key words*: Obturator;Dysarthria; Dysphagia

35

The Activity of Hybrid Vector-mediated Interleukin-24 for Oral Carcinoma Drug Resistant Cells

Yang Dezhao

Department of Oral and Maxillofacial Surgery, The First Affiliated Hospital of Harbin Medical University

Purpose: Evaluate the potential therapeutic effect of IL-24 against KB (human oral squamous cell carcinoma cells line) and KBv (Vincristine resistant KB cells line). To seek a new way for the therapy of drug resistant oral carcinoma.

Methods: KB (human oral squamous cell carcinoma) and KBv (vincristine resistant KB cell line) were utilized in this study. The human keratinocyte cell line HaCaT was used as a positive control for receptor detection. Apoptosis induced by IL-24 in human oral squamous cell carcinoma cell line (KB and KBV) was measured using the MTT assay, flow cytometry, Caspase-Glo®3/7 assay and Western Blot assay.

Results: By MTT assay, we compared the drug resistance of KB and KBV, KBV cells had normal cell viability under 100ng/ml Vincristine environment, but the cell viability of KB cells was significantly decreased. Use AdLTR2EF1α-IL24-treated cells, we found that IL-24 significantly inhibited cell

viability and induce apoptosis in KB and KBV cells, but no harmful effects toward normal cells HaCaT.

Conclusion: Our results indicated that IL-24 not only induced apoptosis in oral carcinoma cells, but also induced apoptosis in oral drug resistance carcinoma cells. In addition, it has no harmful effects toward normal cells. In conclusion, IL-24 could have promising potential as gene therapy against oral drug resistance carcinoma.

Key words: IL-24; Gene therapy; Drug resistance; Apoptosis

36

Evaluation of Using Casting Maxillary Prosthesis to Repair for 9 Patients of The Part of Maxilla Were Excised

Chao Yi

Stomatological Hospital of Nanjing Medical University

Purpose: Evaluated the function and aesthetic effect of using casting maxillary prosthesis to repair for 9 patients' facial collapse due to the part of maxilla were excised in the tumor surgery

Methods: Due to the part of maxilla were excised in the tumor surgery, when the surgery trauma was recovered thoroughly, the 9 patients of facial collapse were repair with casting maxillary prosthesis in 6~8 weeks after the surgery, then made a return visit after three months' wearing, so as to observed the following four indicators including the extent of plumpness of face from appearance of these 9 patients, the articulation of the pronunciation , the masticatory efficiency, whether inorrhea and bucking and so on occur when drinking water and swallowing after wearing the maxillary prosthesis, and evaluated whether the prosthesis wearing has more remarkable promotion in comparison to the previous condition.

Results: After prosthesis repair, not only the 9 patients' masticatory efficiency was improved, the basic feeding was not affected, no inorrhea and bucking occur while drinking water and swallowing, but also the articulation was better, and they could communicate smoothly with others; they showed more confidence for their facial collapse had recovered well.

Conclusion: Regarding to the maxillary prosthesis repaired for the maxillary defect, the function and aesthetic effect were of relatively outstanding advanced after the treatment of maxillary prosthesis repaired in comparison to the previous status.

37

Measured The Adhesive Properties of ZY-1 and ZY-2 Silicone Rubbers Curing by Steps

Han Ying, Li Xiaohong

Stomatological Hospital of Xi'an Jiaotong University

Purpose: To study the influence of the adhesive strength between the ZY-1 and ZY-2 silicone rubbers, which was cured step by step.

Methods: Under Constant temperature 80 ℃ ,the group of silicone rubber adhesive (Adhesive A) was used for positive control group. The adhesive strength of different teams between ZY-1 and ZY-2 were measured and statistical analysis was done. The Bonding interface of Silicone rubber was observed by scanning electron microscope.

Results: There were no significant differences between direct experimental group and positive control group. Scanning electron microscope found that the two materials formed a good interfacial bonding and had no gap.

Conclusion: Ensuring each layer of silicone didn't occur deformation. Step by step solidification of ZY-1 and ZY-2 silicone rubber sat 15-minute can get a better adhesion.

Key words: Silicone elastomers; Adhesive strength; Scanning electron microscopy

38

The Most Suitable Aperture Size and Porosity for Porous

Zhang Ling，Guo Ling

School of Stomatology，Luzhou Medical College

Purpose: Porous tantalum has the advantages of high volumetric porosity, low modulus of elasticity, and excellent osteoinduction, biocompatibility and safety included. However,its cost is too high and processing technic is complex,limiting its clinical use.Consequently,it is necessary to look for a material with similar construction.Titanium has the advantages of exceptional biocompatibility and biosecurity. Above all,the material cost is low,which can be made into a substitute of tantalum.Porous Titanium has proven to promote bone growth,but there has not been a systematic analysis for the most suitable aperture size and porosity.

Method: Electronic and manual search of the literature was conducted, and randomized controlled trials (RCTs) and controlled clinical trials (CCTs) between January 2004 and November 2014 comparing different aperture size and porosity of porous titanium were evaluated for this review.

Results: A total of 2397 articles were identified by the literature search. Finally, 3 eligible studies were selected in this meta-analysis.

Conclusion: The most suitable aperture size is 1.0-2.0mm and porosity 65%-90%.

Key words: The most suitable aperture size, porosity, Porous titanium, oral implant.

39

Research Progress on Prenatal Ultrasound in The Diagnosis of Cleft lip and Palate

Zhang Liuchao, Wang Jingmin.

1. Dept. of Oral and Maxillofacial Surgery, Dalian Stomatological Hospital, Dalian,China; 2. Dept. of Obstetrics and Gynecology, The First Affiliated Hospital of Dalian Medical University, Dalian, China

Abstract: Cleft lip and palate is a common congenital deformity in oral and maxillofacial surgery. Along with the continuing improvement of Chinese economy income, education, living standards and medical technology, more and more parents of cleft lip palate children, whom diagnosis is confirmed by prenatal ultrasound examination, refer to dental hospital for consultation .Thus paying attention to prenatal diagnosis and treatment of cleft lip palate deformity has great significance. This article reviewed prenatal ultrasound diagnosis of cleft lip palate and relevant treatment strategy.

Key words: Cleft lip and palate; Prenatal diagnosis; Ultrasound; Examination

40

Anatomic Study of The Blood Supply of Oral Mucoperiosteum in Minipig

Zhang Xueming,Wang Zuolin

Hospital of Stomatology, Tongji University

Purpose: To provide vascular anatomical basis for the incision design of the oral mucoperiosteal flap.

Methods: The blood supply source, ramification and distribution of the oral mucoperiosteum of Mini-pigs were investigated through latex perfusion and micro-dissection, and the micro-vasculature through ink perfusion and tissue section technique.

Results: The vascular supply of the gingival mucoperiosteum came from the artery going through the muscle layer beneath the alveolar mucosa of the vestibular sulcus, which issued branches toward and into the lamina propria of the gingiva vertically to the mucogingival junction. The microvascular of the lamina propria was constructed vertically to the surface of the epithelium The vascular supply of the hard palatine mucoperiosteum was provided by major palatine artery. Double vascular network could be seen in the submucosa layer.The vasculature of the palatine plica had a tree-like structure.

Conclusion: The incision design of oral mucoperiosteum flap should follow its vasculature and anatomic character. The gingival mucoperiosteum should not be dissected into two layers when elevating the flap, while the hard palatine mucoperiosteum flap could be dissected properly

41

Intrinsic Gene Expression During Regeneration in Maxilla of Salamander

Feng Zhihong, Wen Xuan, Liu Huan, Zheng Yinghui , Zhao Yimin *

Department of Prosthodontics,School of Stomatology,Fourth Military Medical University

Purpose: The extensive regeneration ability of salamander, particularly in relation to maxilla re-growth following resection, is becoming increasingly recognized as a useful model system for understanding intrinsic gene expression in a whole animal context. As such, they present a simplified and controlled regenerating model system which can potentially provide clues as to the mechanism involved in the programming and polarity of resected maxilla. This research was to display the differential expression of the related gene in the maxilla regernation of slamander, then to reveal the posible mechnism to control the maxilla regerneration.

Methods: After the anesthesia in 0.1%tricaine, the distal portion of right maxilla and the surounding soft tissue, about 4mm, was resctected. Then, the salamanders were put in the 0.5% sulfamerazine solution for 12h to protect the wouds. The specimen were collected at 0d, 1d, 3d, 5d, 7d, 9d, 12d, 17d, 20d and kept in the liquid nitrogen. The specimen include the regenerated, the proximal orignal bone and surounding soft tissue. High RNA-sequence technique was applicated to detect the differential expression of RNA. The related gene expression of the bone regeneration were summarized.

Results: The results demonstrated an active transcriptome with extensive differential gene expression focused at the original distalpart of the maxilla explant where the regenerating blastema was located. The transcription profiles also revealed that expression patterns showed subtle differences in the levels of gene expression rather than the presenceor absence of certain genes. The result of analysis revealed that the differential expression ofSOX2, Nanog, Sall4, Tcf, Hif, TNF, TGF, FGF, MAPK, NOTCH, BMP, NAGA,JAK-**STAT.**

Conclusion: The self-regeneration of the resected maxilla was ordered controlled through a complicated gene and molecular network. The study of the related gene and molecular expression must play an important role to reveal the regeneration mechnisim of the maxilla. Epimorphosis (seil-regeneration) maybe provide a possible way to reconstruct the maxillary defect for patients.

Key words: Maxilla; Epimorphosis; Gene; self-regeneration.

42

Effect of Nursing Cooperation on Restoration of Maxillary Defect with Hollow Obturator

Lu Lei, Zhang Xueling, Wu Shuyi *

Department of Prosthodontics, Guanghua School of Stomatology, Hospital of Stomatology, Sun Yat-sen University

Purpose: To explore the effect of nursing cooperation on restoration of maxillary defect with hollow obturator.

Methods: 24 patients suffering from acquired maxillary defect were chosen and restored with maxillary hollow obturator by specialized training maxillofacial prosthodontist and nurse. The nurse kindly provides psychological nursing, oral health education, oral hygiene instruction and mouth-opening training before restoration, and well prepared the sterile appliances and strengthened chairside psychological nursing during the whole restoration procedure. Finally, satisfaction survey and psychological condition were estimated after obturator restoration.

Results: All of the obturators had good retention, favorable stability, nice masticatory function and could obviously improve patients' facial appearance. Results showed that the satisfaction degree of patient to the obturators was 100%, as well as the one of patients to the nursing cooperation. 91.67% of the patients remarkably improved their psychological condition when 8.33% of the patients also had slight improvement.

Conclusion: Good nursing cooperation was an important pledge to make obturator prostheses of maxillary defect successful**.**

Key words: Nursing cooperation; Maxillary defect; Obturator

43

Comparative Studies on Tongue Reconstruction after Hemiglossectomy with Forearm Flap Versus Anterolateral Thigh Flap

Shen Zhiyuan

Department of Oral and Maxillofacial Surgery, the third hospital of the fourth Military Medical University, Shanxi Xi'an 710032, China.

Objective: To evaluate the function in swallowing and speech after the tongue carcinoma surgically resected and function recovered with forearrn flap or anterolateral thigh flap.

Methods: 20 cases of tongue cancer patients received tumor resection and reconstruction between July 2013 and July 2014. 14 patients were reconstucted using forearm flap and 6 patients were reconstructed with anterolateral thigth flap. All of them were followed postoperatively to compare the outcome of functional recovery in swallowing and speech after 6 months.

Results: There was no significant difference between two groups in the swallowing function and the language articulation. In the recipient site, the forearm flap group had 12 patients with hypertrophic scarring, 10 patients with numbness of skin-grafted area and 2 patients with function impairment; however, the anterolateral thigh flap group had 1 patients with hypertrophic scarring and 0 patients with function impairment.

Conclusion: The anterolateral thigh flap; With a long pedicle; Suitable vessel diameter; And low donor site morbidity; Could be the ideal flap for hemiglossectomy defect reconstruction

44

Nerve Growth Factor-modified Mesenchymal Stem Cells Enhance Recovery of Inferior Alveolar Nerve in Rabbit Mandibular Distraction Osteogenesis

Wang Lei, Du Zhaojie, Cao Jian, Yang Xinjie, Lei Delin

Department of Oral and Maxillofacial Surgery, School of Stomatology, the Fourth Military Medical University

Purpose: Distraction osteogenesis (DO) is widely used in treating bone deformities and defects. However, inferior alveolar nerve (IAN) injury is a concern in mandibular DO. The purpose of this study was to investigate the feasibility of lentiviral-mediated human nerve growth factor beta (hNGFβ) of the IAN in the rabbit model of mandible DO.

Methods: Bone marrow mesenchymal stem cells (MSCs) from rabbit mandibles were isolated and genetically engineered using recombinant lentiviral vector containing hNGFβ. Twenty New Zealand white rabbits underwent mandibular DO, and 5 million MSCs transduced with hNGFβ-vector or control vector were transplanted around the IAN in the bone fracture gap during the surgery (n=10 for each group). After gradual distraction, IAN samples were harvested for nerve histologic and histomorphometric analysis.

Results: The genetically engineered MSCs transducted by the lentiviral vector were able to secret hNGFβ at physiologically relevant levels as measured by enzyme-linked immunoabsorbent assay. IAN histology showed more regenerating nerve fibers and less myelin debris in the group with implantation of hNGFβ-modified MSCs when compared with the control group. Nerve histomorphometric analysis showed markedly increased myelinated fiber density in the group with implantation of hNGFβ-modified MSCs than the control group.

Conclusion: The data suggest that implantation of hNGFβ-modified MSCs can markedly accelerate the morphological recovery of the IAN in rabbit mandibular DO. Lentiviral-mediated gene therapy approach to deliver hNGFβ *via* MSCs may be a promising method in minimizing DO-induced nerve injury clinically.

Key words: Nerve growth factor; Distraction osteogenesis; Bone marrow mesenchymal stem cells; Gene therapy; Nerve injury.

45

The Experimental Study of Stem Cells on Prevention of Irradiation Injury of Salivary Gland in Mice

Wang Yan, Liu Bin，Liu Yanpu，Hu Hanqing，Xing Hongyan.

Department of Oral and Maxillofacial Surgery, Qin Du Hospital, Fourth Military Medical Xi'an 710032；2. Department of Biology and Laboratory Animal Center, Qin Du Hospital, Fourth Military Medical Shan Xi Xi'an 710032

Objective: To investigate the feasibility of stem cells to prevent salivary gland irradiation injury, and provide a way and experimental evidence for preventing dry mouth in clinic.

Methods: First，ASCs and BMSCs were isolated and cultured from male mice, the characteristics of two kinds of cells would be identified . Second，found an salivary gland radiation damage model，The mice were devided into 6 group, submandibular glands of every group mice were locally irradiated respectively in the head and neck region with a single dose of 0Gy, 12Gy, 15Gy, 18Gy, 21Gy, 24Gy by a linear accelerator, salivary gland injury were be measured at the one week, one month, two months，three months after irradiation by measuring weight，gland function and gland morphology. Choose the mice of the ideal irradiation dose to provide irradiation model for next experiment. At last, injection stem cells into the mice This part of experiment includes 4 groups, control group, IR + NS, IR +ASCs, IR + BMSCs. Two kinds of the third generation stem cells were injected into the mice respectively by

caudal vein twice every week, which were just irradiated locally 18Gy, totally last for 8 weeks. The cell concentration is 2×10^5/ml, the volume is 0.2ml. It will be detected whether injection stem cells could preserve salivary gland irradiation injury by measuring every index at the two months, three months, four months after injection cells.

Results: We could cultivated ASCs and BMSCs successfully. Salivary gland Radiation damage is dose dependent. The more irradiation dose, the lower the saliva flow rate is. 18Gy exposure group tissue slice with a lot of inflammatory cell infiltration, compared with the control, saliva flow close to 60%, the weight of mice, weight of glands and saliva flow rates in IR +ASCs and IR + BMSCs groups were increased than IR + NS group, the index in the IR +ASCs group are more than that of IR + BMSCs, but it could not come to normal level. There were obvious differences among four groups.

Conclusion: We proved that ASCs of mice are prior to BMSCs in multiplication capacity and cell viability after cell passage. The mice which are irradiated by 18Gy is the ideal salivary gland radiation damage model. Injection stem cells after irradiation could preserve salivary irradiation injury. ASCs are more effective than BMSCs in preventing salivary gland irradiation injury, there were obvious statistics difference between two groups.

46

Reconstruction Defects of Maxilla and Palate with Temporalis Muscle Flap after Maxilla Tumor Resection

Cheng Xiaobing, Wei Jianhua, Lei Delin

State Key Laboratory of Military Stomatology, Department of Oral and Maxillofacial Surgery, School of Stomatology, the Fourth Military Medical University, Xi'an 710032, China

Objective: To evaluate functional effects upon reconstruction defects of maxilla and palate with temporalis muscle flap after benign or malignant tumor resection.

Methods: 45 cases with immediate reconstruction of maxilla and palate by temporalis muscle flap from 2008 to 2013 were enrolled in the present study. 31 were malignant tumor and others were benign tumors. 25 patients received post-operative XRT. Their appearance and recovery of speech, deglutition function were analyzed.

Results: Among the 45 patients, all flaps were survived. Shrinkage was not significant with time except after XRT. There were only 2 cases with oronasal fistula formation. 35 patients were satisfied with their appearance. The average speech intelligibility was 90. 1%. 85% cases swallow well with no fluid reflux.

Conclusion: The reconstruction of defects in maxilla and palate with temporalis muscle flap can reconstruct the appearance, prevent Oronasal fistula formation and restore the speech/swallowing function after operation. Comparing with free osseous myocutaneous flap, this flap represents a relatively simple and acceptable alternative choice for maxilla reconstruction.

47

BDNF Mediated TrkB Activation Contributes to The EMT Progression in Human Salivary Adenoid Cystic Carcinoma

Jia Sen, Wang Weixi, Hu Zhiqiang, Shan Chun, Wang Lei, Wu Baolei, Yang Zihui, Lei Delin *, Yang Xinjie *

State Key Laboratory of Military Stomatology, Department of Oral and Maxillofacial Surgery, School of Stomatology, The Fourth Military Medical University, Xi'an 710032, China

***Correspondence to: Dr.Xinjie Yang or Pro.Delin Lei,**

Purpose: Brain-derived neurotrophic factor (BDNF) and its receptor Tropomysin-related kinase B (TrkB) are over-expressed in a series of malignancies and associated with the tumor progression. Recent studies indicated that BDNF/TrkB axis may participate in the epithelial-mesenchymal transition (EMT) of malignant epithelial tumours. However, the roles of BDNF/TrkB in salivary adenoid cystic carcinoma (SACC) have been poorly investigated. The present study was aimed to investigate whether BDNF and TrkB expression is correlated with the clinical progression of SACC and whether BDNF/TrkB axis is associated with the EMT induction in SACC cells.

Methods: BDNF, TrkB, and E-cadherin (EMT biomarker)expression in 76 primary SACC cases and 20 normal salivary gland tissues were analyzed by immunohistochemistry. Moreover, BDNF, TrkB, and E-cadherin expression in SACC cell lines (SACC-83 and SACC-LM) were analyzed by RT-PCR and western blotting. The biological role of BDNF/TrkB axis in the EMT progression of SACC was analyzed using BDNF stimulating and TrkB interruption in SACC-83 cell line. The progression of EMT was indicated by RT-PCR, western blotting, photography, migration and invasion assays.

Results: Higher expression of TrkB (92.1%) and BDNF (89.5%) was found in SACC specimens, which was significantly correlated with the invasion and metastasis of SACC ($P<0.05$). The expression of TrkB was negatively associated with the expression of E-cadherin in SACC cases and cell lines ($P<0.05$). BDNF stimulation by exogenous rhBDNF(100 ng/ml) significantly promoted the trkB activation and the EMT progression of SACC cells. While interruption of trkB by its inhibitor, k252a (100 nM), significantly inhibited the EMT progression of SACC cells.

Conclusion: These results suggested that BDNF mediated TrkB activation contributed to the EMT progression in SACC. The present study demonstrated that BDNF/TrkB axis promoted the migration and invasion of SACC via EMT. Prevention of BDNF/TrkB axis may be a potential strategy for the treatment of SACC.

Key words: Salivary adenoid cystic carcinoma; EMT; BDNF; TrkB

48

Application of PFM Crowning Techniques To Restore Multiple Adult Stuck Teeth with Large Scattered Clearance

Guo Ling, Li Wangyang, Huang Yao

Stomatology Hospital Affiliated to Luzhou Medical College

Purpose: The purpose of this presentation is to present the results of applying PFM crowning techniques to restore multiple adult stuck teeth with largely scattered clearance.

Method: Lack of permanent tooth germ would result in multiple adult anterior teeth stranded and wide gaps with canine crossbite. The approach adopted to restore these stuck teeth include three steps: 1: Correct the malocclusion by orthodontic treatment,2: Apply PFM bridge to restore maxillary teeth 3: Apply union crown to restore deciduous teeth due to short root and wide gaps.

Results: Multiple wide scattered clearances were corrected successfully in a short period. The deciduous tooth was kept while the gaps were closed at the same time. The function of aesthetics and language were fully restored.

Conclusion: The combination of orthodontic treatment with restoratory treatment can be effectively used to restore the teeth with large gap and multiple teeth stranded. It has the advantages of keeping the deciduous tooth while closing the gaps and fully restoring the aesthetics and language.

49

Comparative Studies on Sensory Recovery in The Radial Forearm Flap Versus Anterolateral Thigh Flap Used for Tongue Reconstruction

Yan Zhiwei, Wei Jianhua, Sun Moyi, Cheng Xiaobing, Lei Delin

Department of Oral and Maxillofacial Surgery, the third hospital of the fourth Military Medical University, ShannxiXi'an 710032,China

Purpose: To evaluate sensory recovery in patients with tongue carcinoma surgically treated and reconstructed in non-innervated radial forearm flap or anterolateral thigh flap.

Method: 43 cases of tongue simultaneous reconstruction by using free flap. 23 patients were reconstructed using a radial forearm flap,and the remaining were reconstructed with an anterolateral thigh flap. At 6 months and 8 months after treatment, all cases of tongue reconstruction were analyzed flap sensations to touch, two-point discrimination,sharp vs dull, warmth vs cold, then were followed to determine their swallowing and speech functional outcome.

Results: 6 flaps showed 3/4 or more area of sensory recovery, 3 flaps showed 2/4 or more area ofsensory recovery, 11 flaps showed 1/4 or more area of sensory recovery, 3 flaps showed anesthetic in radial forearm flap group of 23 patients; 7 flaps showed 3/4 or more area of sensory recovery, 8 flaps showed 2/4 or more area of sensory recovery, 4 flaps showed 1/4 or more area of sensory recovery, 1 flaps showed anesthetic in anterolateral thigh flap group of 20 patients. The degree of recovery felt different in groups of patients, but showed no statistical difference. The functional results with both flaps were adequate, and the two groups did not differ significantly between each other for either swallowing or speech.

Conclusion: Spontaneous recovery of flap sensation can be re-established after reconstrucation in non-innervated radial forearm flap or anterolateral thigh flap. The swallowing and speeching recovery in post operative patients were related with the recovery of flap sensation. sensory function with flap-recovery. Anterolateral thigh flap with sensory nerve could be an ideal flap for tongue defects functional reconstrtion

Key Words： Radial forearm flap； Anterolateral thighflap； Tongue defect； Reconstruction； Sensation

50

Experimental Study on Autologous of Rabbit Adipose-derived Stem Cells Transplantation

Yang Tao

State Key Laboratory of Military Stomatology, Department of The Head and Neck Tumor Surgery, School of Stomatology, The Fourth Military Medical University,Xi'an 710032,Shaanxi,China.

Objective: To establish an animal model for the injectable transplantation fat tissue transplantation and to investigate the morphological changes of rejection after ear transplantation in rabbit**.**

Methods: Establishment of animal models: Rabbit ear artery end automatically, vein bifurcation of the ear artery and the inner ear edge vein at the junction of the mid-point of a circle with a radius of 15cm . Separated from the skin and periosteum, periosteal stripping was required in accordance with the experimental groups, with 18 # syringe 2ml complex was transplanted to this site.Identification and culture of rabbits fat stem cells: under sterile conditions, approximately 8 ml of fat removed from the back of the rabbit, by using digestion centrifugation and cultured adipose stem cells at 37 °C, 5% CO2 incubator. HE staining, the streaming detection and confirmation of pre-transplant fat stem cells is done. To transplanted the composites into the ear of the rabbits: In accordance with the experimental groups,we put ADSCs, AG and PRF into the ear of the rabbits. Experimental group:30 healthy New Zealand

rabbits,were divided into 4 groups: GroupA:AG; GroupB:AG+PRF;GroupC:AG+ADSCs(adipose-derivedstem cells, fat stem cells);Group D: AG+ADSCs+PRF. In vivo transplantation of the injectable fat particles complex: AG, ADSCs prf grouped by experimental transplantation to rabbit ears corresponding parts. Data collection and statistical analysis. Results were statistically analyzed using SPSS18.0 software, each group data were analyzed by ANOVA single factor analysis of variance, and comparison among the four groups of survival differences were made. At month 1,3 and 6 after transplantation, the survival rates of transplanted ears ,HE staining, rabbit ears light transmission experiments.

Results: At month 1,3 and 6 after transplantation, the survival rates of transplanted ears ,HE staining, rabbit ears light transmission experiments，the differences of the group D and group A、B、C were statistical significant (P <0.05)

Conclusion: The adipose granule(AG) combined with platelet-rich fibrin(PRF) and adipose-derived stem cells(ADSCs) can improve the survival rate of transplanted fat tissue and provide experimental basis for clinical fat transplantation.

Key words: Adipose tissue; ADSCs; AG; PRF

51

A Comparison of Health Related Quality of Life between Radial Forearm Free Flap and Pectoralis Major Myocutaneous Flap for Reconstruction in Oral Cancer Patients

Wang Weiqi, Ding Mingchao, Na Sijia

Department of Oral and Maxillofacial Surgery, Fourth Military Medical University School of Stomatology,

Purpose: This study assesses and compares the quality of life of oral cancer patients who had undergone surgical resection and primary reconstruction of defect using either radial forearm free flap (RFFF) or pectoralis major myocutaneous flap (PMMF).

Methods: The University of Washington of life (UW-QOL v4) questionnaire was mailed to patients who had disease free survival for at least one year. Patient's demographic and quality of life data were collected and analyzed.

Results: A total of 112 questionnaires were returned (51.61%). There were significant differences in T-stage (p=0.002), surgical time (p=0.01) and duration if hospitalization (p<0.001) between the two groups. Patients reconstructed with RFFF had better speech, shoulder and mood domain, while swallowing in total/subtotal glossectomy was better in PMMF group.

Conclusion: Data from this study serve as a useful resource for physicians and patients during their discussion of reconstructive options for oral cancer.

Key words: quality of life; oral cancer; pectoralis major myocutaneous flap; radial forearm free flap; glossectomy

52

The Clinical Application of Temperature Molding Wax in The Protheses of Soft Palate Defect

Xia Zhuo，Feng Zhihong，Zhao Yimin

Department of Prosthodontics, School of Stomatology, the Fourth Military Medical University

Purpose: To clarify the process of acquiring the impression for the soft palate with the temperature molding wax，and to assess the clinical effect.

Methods: The impression for the defective soft palate cavity， which was acquired with the temperature molding wax，was applied into the fabrication of the obturator. As the obturator was adapted for one month，subjective perception for the nose leakage，speech intelligibility (SI) and vowel spectral analysis were measured with and without the obturator and analyzed by the paired-samples t test.

Results: There was significant difference in both perceptual ratings of nose leakage and SI values between both groups（P<0.05）.For spectral analysis of the six vowels，the first three formant frequencies had changed，and F1，F2 of [i]，F2 of [u]，F2 of [ü] in patients with obturator were significantly higher than those in patients without obturator（P< 0.05）.

Conclusion: The obturator，which was made from the impression acquired with the temperature molding wax，can obviously improve the situation of nose leakage and speech disorder relative to the velopharyngeal incompetent.

Key words: Temperature molding wax；Impression for the soft palate；Clinical assessment

53

Factors Influencing The Survival of Nonvascularized Bone Grafts Mandibular Reconstruction

Zhang Xiangyu, Tang Xiufa

Department of Head and Neck Oncology, West China Hospital of Stomatology, Sichuan University

Purpose: To evaluate factor influencing the survival rate of autogenousnonvascularized bone grafts for mandibular reconstruction.

Methods: Fifty-six patients of West China Hospital of Stomatology from 2007 to 2013 with segmental mandibulectomy and non-vascularized bone grafting were included. Factors including age, sex, alcohol consumption, smoking habit, site of the defect, kinds of bone grafts, method of graft fixation, infection of the lesion, operation duration were recorded and analyzed by Logistic regression to see their correlation with survival. SPSS 16.0 were adopted for analysis.

Outcomes: The main reason of mandibular reconstruction is ameloblastoma(58.9%). In 49 (87.5%) patients, the initial reconstruction was successful. The main classification of the defect is L (57.1%) and H (30.4%), and the two kinds nonvascularized bone grafts are rib (41.1%)and iliac bone (58.9%). The main factors that correlated with survival were smoking habit (P=0.024, Exp (B)=187.739) and operation duration (P=0.029, Exp(B)=1.032). The other factors were not correlated with survival (P>0.05)

Conclusion: Nonvascularized bone grafts for segmental reconstruction of the mandible is a choice of high success rate. Smoking and long operation time could decrease its survival.

54

Large Full-thickness Labial Defects Repaired by Free Flaps: A Case-series

Li Chunjie, Han Bo, Li Yi, Li Longjiang

Department of Head and Neck Oncology, West China Hospital of Stomatology, Sichuan University

Purpose: To investigate the effect of free flaps in the reconstruction of large full-thickness labial defects.

Methods: Patients with large full-thickness defects of the lip in West China Hospital of Stomatology,

Sichuan University between 2010-2014 were retrospectively reviewed. The demographic characteristics, causes of defects, types of flaps and survival etc were recorded.

Result: A total of 15 patients received free flap reconstruction for large full-thickness labial defects with ages between 39 and 72 and there were 11 males and 4 females. Causes of the defects were labial squamous cell carcinoma (6), buccal squamous cell carcinoma involving the lip (4), labial malignant melanoma (2), gingival malignant melanoma involving the lip (1), labial epithelial myoepithelial carcinoma (1) and labial skin cancer (1). 15 radial forearm flap were used in 14 patients (with one flap was necrosis and repaired by contralateral forearm flap), and 1 anterolateral thigh flap for 1 patient. The follow-up period was between 6 and 42 months, with one died with disease recurrence and 1 had recurrence but salvaged. All patients had intact oral function and good aesthetic results.

Conclusion: Large full-thickness labial defects require free-flap reconstruction. And this reconstruction had a good practicability and aesthetic results

55

Optimal Reconstructive Strategy for Large Facial Defects: A Report of 12 Cases

Li Tang, Li Chunjie, Li Longjiang

Department of Head and Neck Oncology, West China Hospital of Stomatology, Sichuan University

Purpose: To detect the efficacy of optimal reconstructive strategy for large facial soft-tissue defect repair.

Methods: Patients with large facial soft-tissue defects who underwent surgical treatment in Department of Head and Neck Oncology, West China Hospital of Stomatology, Sichuan University between 2012.7 and 2013.7 were reviewed. Any patients who received optimal soft-tissue flap reconstruction were included. Demographic characteristics, types of disease, types of defects, reconstructive strategy and the prognosis were recorded and analyzed by SPSS 16.0.

Results: 14 patients were included with 11 males and 3 females. Causes of the defects included malignancy resection, post-operative inflammation and trauma. 8 cases with underwent anterolateral thigh flap reconstruction, include 5 facial basal cell carcinoma , 1 altercation defect after gingival carcinoma surgery and 2 facial sarcoma. 1 case with facial spindle cell tumor repaired with latissimus dorsimyocutaneous flap. For the others, 2 pectoralis major myocutaneous flap, 1 anteromedial thigh flap, and 1 inferior epigastric perforator flap were conducted. 1 case with anterolateral thigh flap was failed and the others all succeeded. All the patients were followed up for at least 1 year and were all survived with good quality of life and satisfactory.

Conclusion: A choice of the soft-tissue flap reconstruction should be based on the depth, size and location of the defects and the characteristics of flaps. Such optimal reconstructive strategy has great value to the clinic.

56

A Case Report: Two Stage Denture Issuance Technique for Fabricating Definitive Prosthesis for Hemi-Maxillectomy

Patient.

Kunal Parekh

University of the East, manila, Philippines

Abstract- Restoring masticatory functions, phonetics , deglutition and nasal regurgitation of oral intakes

are challenging problems to overcome for hemimaxillectomy patients. A definitive solution for such surgery is the fabrication of prosthesis that improvises the impression procedures to accommodate the dimensional changes of the tissues and utilizes a two stage denture issuance technique. The 1st stage includes chair-side soft auto-polymerizing resin material over hollow bulb obturator denture issuance. Upon recall verifying the dimensional changes, 2nd functional impression is recorded using the previously issued denture as a special tray. Permanent processed soft tissue conditioner is used as liner over the hollow-bulb obturator denture as final issued definitive and retentive prosthesis for 2nd stage denture issuance. Two stage denture issuance technique to fabricate a retentive, stable and functional prosthesis for hemimaxillectomy patients with soft tissue liner material minimize dimensional changes of the soft tissue. The defect sealing by the denture to the defect is improved and soft denture liner provides conditioning to the underlying tissues.

57

GDF15 Is A Potential Predictive Biomarker for TPF Induction Chemotherapy and Promotes Tumorigenesis and Progression in Oral Squamous Cell Carcinoma

Zhong Laiping, Yang Chengzhe, Zhang Chenping

Department of Oral &Maxillofacial-Head &Neck Oncology, Ninth People's Hospital, Shanghai Jiao Tong University School of Medicine

Purpose: Randomized trials have not shown major survival benefits when induction chemotherapy plus standard therapy is compared with standard therapy alone in patients with oral squamous cell carcinoma (OSCC). Induction chemotherapy is likely to be effective for biologically distinct subgroups and biomarker development may lead to identification of patients whose tumors are likely to respond to a particular treatment.

Methods: We evaluated immunohistochemical staining for GDF15 in pretreatment biopsy specimens of 230out of 256 OSCC patients who were treated in a prospective, randomized, phase three trial on induction chemotherapy including docetaxel, cisplatin and 5-fluorouracil(TPF).Relationship between GDF15 intervention and cell proliferation, migration, invasion, colony formation and tumorigenicity was analyzed using *in vitro* and *in vivo* OSCC models.

Results: LowGDF15 expression predicted a better survival in OSCC patients, especially overall survival (P=0.049, HR=0.597) and distant metastasis free survival (P=0.031, HR=0.562). cN+ patients with low GDF15 expression benefitted from induction TPF in overall survival(P=0.039, HR=0.247) and distant metastasis free survival (P=0.039, HR=0.247), cN- patients with high GDF15 expression benefitted from induction TPF in overall survival(P=0.019, HR=0.231), disease free survival (P=0.011, HR=0.281), locoregional recurrence free survival (P=0.035, HR=0.347) and distant metastasis free survival (P=0.009, HR=0.197). Decreased GDF15 expression in OSCC lines significantly inhibited cell proliferation, migration, invasion, colony formation and tumorigenesis through increased phosphorylation of AKT and ERK1/2 (P<0.05). Likewise, overexpression of GDF15significantly promoted cell proliferation, migration, invasion and colony formation through decreased phosphorylation of AKT and ERK1/2 (P<0.05).

Conclusion: GDF15 expression can be used as a prognostic biomarker for OSCC, and as a predictive biomarker for benefitting from TPF induction chemotherapy.GDF15 promotes tumorigenesis and progression through phosphorylation of AKT and ERK1/2 in OSCC.

58

Modified Bilateral Karapandzic Flap for Reconstruction of Large Lip Defect

Hu Jingzhou, Ye Weimin, Zhu Hanguang, Zhang Chenping, Zhang Zhiyuan
Ninth People's Hospital, Shanghai Jiao Tong University School of Medicine

Purpose: Reconstruction of lower lip defect with Karapandzic flap often leads to greater rounding of commissure. The aim of this study was to provide a new design of bilateral Karapandzic flap, which is useful in large lower lip defect reconstruction.

Methods: A modification of the Karapandzic lip reconstruction technique was used with an additional incision to recruit more tissue. The esthetic outcome of the reconstruction was assessed in a 4 point scale with regard to the shape of commissure, lip symmetry, appearance of the scar and lip projection. The functional outcome were assessed in terms of speech, preservation of oral competence, lip sensory, facial expression, diet and denture usage.

Results: Seventeen lower lip squamous cell carcinoma patients underwent single-stage lip reconstruction (13 males, 4 females) with an age range of 52 to 82 years. The lip defects post tumor resection ranged from 50% to 90% of the lower lips. All patients achieved oral competence, without leading to greater rounding of the commissure. The esthetic outcome was considered excellent/good in 88% of cases and the reconstruction did not lead to functional impairments of speech, oral competence, lip sensory, facial expression, diet or denture usage.

Conclusion: Modified bilateral Karapandzic flap is a reliable technique to reconstruct large lip defects without leading to rounding of the commissure. With this technique, good esthetic and functional outcomes could be achieved.

59

The Basis of Applicating High-frequency Color Ultrasound in Preoperative Identification and Selection Perforator of Anterolateral Thign Flap

Huang Jian, Shen Yi,Lu Linguo, Huang Guanlan,Zhou Huihong,Chen Qian-qian,Li Jun, Sun Jian

Department of Oral and Maxillofacial Surgery, College of Stomatology; Ninth People's Hospital, Shanghai Jiao Tong University; Shanghai 200011,China

Purpose: To explore the basis of selecting the appropriate perforator vessels according to the results of preoperative high-frequency color Doppler ultrasound and guide the anterolateral thign(ALT) flap harvest.

Methods: From March 2013 to December 2013, 52 patients underwent preoperative ultrasound before ALT harvest for head and neck cancer reconstruction. Using ultrasound predict the number， original, course, location, diameter and hemodynamics of perforators to choose the better donor site for harvest flap. The preoperatively mapped perforators were compared with the actual intraoperative findings.

Results: A total of 208 perforators were found by preoperative ultrasound in 52 patients. Finally 27 patients used ALT to reconstruction head and neck defect. There were no significant difference between preoperative and real situation of intraoperative perforator indicators (P>0.05).

Conclusion: Preoperative mapping of perforators by ultrasound proved valuable in ALT flap design and harvest. The basis are as follows: ① perforator diameter is the first consideration indicator； ② priority to the septum or half septum perforator which is easily dissected； ③ select the perforator with high flow velocity and low resistance index； ④ the pedicle length of perforator meet the needs of reconstruction. We should make a comprehensive consideration in clinical to choose the appropriate perforator.

Key words: Ultrasound; Anterolateral thigh flap; Preoperative planning; Basis

60

Functional Evaluation after Mandibular Reconstruction for Oral Cancer Patients

JiTong, Ong Huishan, Zhang Chenping, Sun Jian.

Dept. Oral&Maxillofacial– Head Neck Oncology, 9th People's Hospital, Shanghai Jiao Tong University School of Medicine，Shanghai China, 200011

Purpose: Evaluate the functional benefits of mandibular reconstruction following segmental resection.

Methods: Objective measures of oral function were evaluated in 54 patients. The relationships among the function and reconstruction method were evaluated.

Results: Both patients presented decreased function as compared with normal. However, bone graft patients had significantly better measures of oral function as compared with other methods.

Conclusion: Both reconstructed and other methods patients presented with a significant functional deficit when compared with normal, with osteocutaneous flap reconstructed patients having better masticatory, swallowing and speech than other two groups of patients.

Key words: Mandible; Reconstruction; Functional evaluation

61

Double Barrel Vascularized Fibula Graft in Mandibular Reconstruction: A 10-year Experience with An Algorithm

Li Jun, Sun Jian, Shen Yi

Department of Oral and Maxillofacial-Head and Neck Oncology, the Ninth Affiliated Hospital, Shanghai Jiao Tong University, Shanghai, China.

Purpose: This retrospective study aims to report an algorithm to assist surgeons in selecting different modes of the double barrel vascularized fibula graft for mandibular reconstruction.

Methods: Forty-five patients who underwent reconstruction of mandibular defects with different modes of the double barrel vascularized fibula graft were reviewed. Our algorithm for deciding on any one of the different modes for different mandibular defects is influenced by the factors including history of radiotherapy, the length of mandibular body defect, and the need to preserve the inferior mandibular border. Postoperative functional outcomes included diet type and speech, and aesthetic results gained at post-operative 2 years. Patients with implant-borne prosthetic teeth underwent assessment of their masticatory function.

Results: There were 4 modes of mandibular reconstruction according to our algorithm, which included double barrel vascularized fibula graft (n=21), partial double barrel fibula graft (n=11), condylar prosthesis in combination with partial/double barrel fibula graft (n=11), and double barrel fibula onlay graft (n=2). Flap survival in all patients was 97.78%. Good occlusion, bony unions and wound closures were observed in 44 patients. Eleven patients received dental implantation in the transplanted fibula at post-operative 9~18th months. One patient wore removal partial dentures. For 11 patients with implant-borne prosthetic teeth, the average postoperative ipsilateral occlusal force was 41.5±17.7% of the contralateral force. Good functional and aesthetic results were achieved in 38 patients with more than 2 years follow-up, including regular diet, normal speech and excellent or good appearance, especially for patients with dental rehabilitation.

Conclusion: Good aesthetic and functional results can be achieved after dental rehabilitation by following our algorithm when choosing the different modes of double barrel vascularized fibula graft for mandibular reconstruction.

Key words: Mandibular reconstruction; Double barrel vascularized fibula graft; Algorithm

62

Ablative Surgery of Giant Ossifying Fibroma in The Jaws Followed by Immediate Reconstruction: A 10-year Single Institution Experience

Lv Mingming, Shen Yi, Li Jun, Sun Jian

Department of Oral and Maxillofacial-Head and Neck Oncology, the Ninth Affiliated Hospital, Shanghai Jiao Tong University, Shanghai, China

Purpose: The aim of our study was to present our 10-year experience in treatment of giant ossifying fibroma (OF), and to reveal that if good aesthetic and functional outcomes can be achieved after ablative surgery of giant ossifying fibroma followed by immediate reconstruction.

Methods: 18 patients who underwent radical resection of giant OF in jaws and immediate reconstruction was done using vascularized fibula flap or ilium flap between Oct 2003 and Oct2013. Post-operative aesthetic results and functional outcomes gained at post-operative 2 years.

Results: 4 patients underwent immediate maxillary reconstruction and 14 patients underwent mandibular reconstruction after ablative surgery of giant OF in jaws. The average length of follow-up was 3.5 years. No recurrence was occurred in our cases. 5 patients received implant-borne prostheses and 13 cases received removable partial dentures. Good cosmesis and function outcomes were noted in these 18 cases.

Conclusion: It is a feasible and effective way to radical resection of giant OF followed by immediate reconstruction and good aesthetic and functional results can be achieved after dental rehabilitation.

Key words: Giant ossifying fibroma; Radical resection; Immediate reconstruction

63

Oral Cavity Reconstruction Using A pedicled Submandibular Gland Flap: A Preliminary Report

Mubarak Mashrah, Zhou Shanghui, Ma Chunyue, He Yue, Zhang Chenping

Department of Oral and Maxillofacial–Head & Neck Oncology, 9th People's Hospital, College of Stomatology, Shanghai JiaoTong University School of Medicine, Shanghai, China

Purpose: To present our preliminary experience in the use of submandibular gland (SMG) flap in reconstruction of defects of the oral cavity following tumor resection.

Methods: 13 patients (7 males and 6 females) with ages averaging 38 years (range from 3 to 69 years), admitted to Oral and Maxillofacial–Head & Neck Oncology department, from July 2012 to May 2014, were subjected to ablative surgery and reconstruction using a pedicled SMG flap. Only small and medium-sized defects, resulting from resection of intraoral masses were included in the study. Patients with squamous cell carcinoma were excluded from this article. All patients were evaluated in respect to flap reliability, cosmesis, function (speech and swallowing), and donor site morbidity.

Results: All patients were followed-up for a period ranged from 3 to 22 months. Functional and esthetic outcomes in both recipient and donor sites were satisfactory. Partial necrosis was observed in 1 patient and partial dehiscence in 2 patients. No xerostomia observed in all patients.

Conclusion: The SMG flap is a simple and reliable alternative option for reconstruction of small- to medium-sized oral cavity defects in carefully selected cases, with better cosmetic and functional results.

Key words: Submandibular gland; Pedicled flap; Oropharyngeal reconstruction.

64

State of Art of Post-operative Hemimaxillectomy Rehabilitation: Clinical Evaluation on Prosthesis Supported by Zygoma Implant and Remaining Natural Teeth

Qu Xingzhou(DDS, MD, PhD),Wang Mingyi(DDS, PhD), Ong Huishan(BDS, MD, PhD),Zhang Chenping(DDS, MD, PhD)

Department of Oral Maxillofacial-Head & Neck Oncology, Shanghai Ninth People's Hospital, Affiliated to Shanghai Jiao Tong University

Purpose: The aim of this study is to evaluate the stability zygoma implant with remaining teeth in supporting a prosthesis for subjects who had undergone hemi-maxillectomy.

Methods: Ten patients were included in the study. Oral rehabilitations were performed with temporary prosthesis supported by remaining teeth for the first three months. The final prosthesis will be supported by remaining teeth and zygoma implant, prosthesis was tailored made according to biomechanical three-dimensional finite element analysis result. The patients were assessed by referring to prosthesis functioning scale (OFS) of the Memorial Sloan-Kettering Cancer Center. In addition, the retention and bite force were recorded with temporary prosthesis and final prosthesis respectively. **Conclusion:** The bite force was increased significantly with the support of zygoma implant. The application of zygoma implant in the restoration of maxillary defects showed good results in functional outcome and social acceptance.

Key words: Maxillectomy; Zygoma implant; Rehabilitation; Finite element analysis

65

Clinical Data Analysis of 200 Cases of Parotid Gland Tumor

Shen Shukun,Xu Liqun,Li Jiang,Zhong Laiping, Zhang Chenping

Ninth People's Hospital, Shanghai Jiao Tong University School of Medicine, Shanghai, China, 2Ninth People's Hospital Affiliated Shanghai Jiaotong University School of Medicine, Shanghai, China

Purpose: A retrospective study of clinical data for 200 cases of primary parotid gland tumors in the day surgery ward have been done,in order for us doctors to get some useful information of the preoperative clinical diagnosis of parotid gland tumors to help to evaluate postoperative patients.

Methods: From May 2009 to May 2012, the medical history of patients checked by gender, age , clinical symptoms, imaging data , surgery, pathology , hospital costs and outcomes were analyzed and evaluated.

Results: The data indicated that about 57% of the male, while about 53% of female, with a median age of 55 years old were composed of the patients, of which 78 % were benign, mainly pleomorphic adenoma. But Warthin tumor occurred in middle-aged men, with only four cases women,including 2 cases showing obvious signs of infection. Most patients had tumor with no obvious symptoms, but clearly there was pain, swelling, uncomfortable in patients with malignant diagnosis. Imaging data predicted the nature of the tumor in most patients and the specific distribution areas, also add some cost to patients. The average cost of hospitalization in patients with benign tumors was about 12 to 14 thousand Yuan in RMB, while the patients in malignancy cost 18 to 25 thousand Yuan in RMB. No patients with benign tumors recurred. And except only two cases of local recurrence, a case of lymph node metastasis, a female case of sudden death after two days operation of Warthin Tumor, not any other patients recurred or died. It might be due to different postoperative treatment in various types of cancer patients.

Conclusion: The main symptoms of primary tumor of parotid gland have some relevance with diagnosis and prognosis. In addition, poor uninsured patients can be considered to reduce the imaging examination to reduce the burden.

Key words: Parotid gland tumor; Cost

66

Special Considerations in Virtual Surgical Planning for Secondary Accurate Maxillary Reconstruvtion with Vascularized Fibula Osteomyocutaneous Flap

Shen Yi, Sun Jian, Li Jun

Department of Oral and Maxillofacial-Head and Neck Oncology, the Ninth Affiliated Hospital, Shanghai Jiao Tong University, Shanghai, China.

Purpose: This paper describes our special considerations in virtual surgical planning for secondary maxillary reconstruction with vascularized fibular osteomyocutaneous flap and our revised surgical design for maxillary reconstruction.

Methods: Eleven patients with different maxillary defects according to Brown's revised classification underwent virtual surgical planning for secondary accurate reconstruction. For different horizontal class defects, the fibular was osteomized to match maxillary alveolar arch by using the mirror image of the contralateral alveolar ridge or the curve of mandibular arch and dentition.

Results: Maxillary reconstruction was performed with the guidance of preoperative virtual planning and using fibular osteotomy and reposition guide templates to replicate the virtual planning intraoperatively. Virtual surgical planning was replicated intraoperatively in all patients. The fibulae were osteotomized into four segments in three patients with the horizontal class d2 defect and three segments in eight patients with the horizontal class b~d1 defects, respectively. Overall success rate for 11 flaps was 100%. Good bony unions and wound closure were observed and intelligible speech was achieved in 11 patients. Maximum incisal opening ranged from 3.0 to 4.0cm. All patients tolerated a regular diet postoperatively. Postoperative mid-facial appearance was good in all patients.

Conclusion: We recommend that the horizontal class d defect in Brown's revised classification of maxilla and mid-face be divided into two subtypes according to whether it involves the contralateral canine or not. Special considerations in virtual surgical planning are helpful to perform accurate secondary maxillary reconstruction with vascularized fibular osteomyocutaneous flap.

Keywords: Virtual surgical planning; Secondary maxillary reconstruction; Fibular osteomyocutaneous flap; Brown's classification of maxilla and midface

67

Surface Modification of Silicone Rubber by Layer by Layer Assembly Method

Sun Wenling, Liu Xiaoqiu,Liang Dan,Li Shenghai

Department of Prosthetic Dentistry, Hospital of Stomatology, Jilin University, Changchun 130021, P. R. China

Purpose: In order to improve the hydrophilicity and antibacterial properties of silicone elastomers materials, chitosan was selected to modify the surface of silicon rubber through layer by layer assembly method.

Methods: The cleaned MDX-4-4210 silicone rubber specimen was alternately immersed in 5 wt% Nafion solution and chitosan acetic acid solutions at room temperature for 8min and 10min respectively. After each immersing step, the silicon sample was extensively rinsed with deionized water and dried with a stream of N_2 gas. After ten repeat cycles, the sample was dried under vacuum for characterization. The chemical composition of the assembly layer on the surface of the silicone rubber specimen was characterized by Fourier transform infrared (FTIR). The surface wettability was

evaluated by static contact angles of water on the surface of the silicone rubber at room temperature.

Results: The FTIR analysis of the samples confirmed that the assembly of chitosan and Nafion on the surface of silicon surface is successful. The wettability of the modified surface was improved by the assembly of hydrophilic polymer. It was noted that the water contact angle reduced from 98.4^{o} for virgin silicon to about 75.3^{o} for modified silicon with only 5 assembly layers.

Conclusion: It indicated that the layer by layer assembly method could be used to modify the properties of the silicon elastomer.

Key words: Surface modification; silicone rubber; layer by layer assembly method

68

Tendon Sheath Giant Cell Tumor (TSGCT) with Intradural Extension: Utilizing Temporal Bone for Skull Base Reconstruction in Preventing Brain Hernia

Ong Huishan, Ji Tong, Wu Yuqun, Zhang Chenping

Oral Maxillofacial-Head & Neck Surgery Department, Shanghai Ninth People's Hospital, Affiliated to Shanghai Jiao Tong University.

Neurology Department, Shanghai Ninth People's Hospital, Affiliated to Shanghai Jiao Tong University

Purpose: TSGCT is a rare, benign, idiopathic proliferative destructive disease of the synovium. It tends to arise in large joints like knee and ankle and rarely in TMJ. Destructive nature of TSGCT required immediate treatment upon diagnosis. Radical resection proved to be an excellent choice for superior local control. However, unfavorable anatomic location of TMJ and infratemporal fossa with intradural extension makes such a resection impractical.

Methods: Hereby, we reported a case of transcranial approach in resection for a TMJ orientated TSGCT with intradural extension. A complex resection might require a good reconstruction. Transposition of temporal craniotomy bone flap will be another novel state of art in reconstructing the inferior skull base for sake of improved three-dimensional rigid architecture.

Results: Temporal craniotomy bone graft is a reliable plug for rigid support in preventing brain hernia and correlated CSF leak. This cost-effective technique is relatively simple and applicable across all socioeconomic strata.

Keywords: Tendon Sheath Giant Cell Tumor; TMJ; Head Neck Cancer; Skull base; Resection; Reconstruction

69

Application of Submental Island Flaps for Reconstruction of Oral Maxllofacial Soft Tissue Defects

Wang Liang, Li Jun,Sun Jian* ,Shen Yi

Department of Oral and Maxillofacial-Head and Neck Oncology, Shanghai Ninth People's Hospital, School of Stomatology, Shanghai Jiaotong University school of medicine,Shanghai Key Laboratory of Stomatology, Shanghai 200011,China

Purpose: To explore the effect of Submental island flap in reconstruction of maxillofacial soft tissue defects.

Methods: We analyzed 78 cases of submental island flap,（from 2008.12 to 2011.6,）including the indications of flap ,its harvest technology, the flap survival situation, supply area appearance, the form

and function of defect area after reconstruction， postoperative complications and the factors influencing the flap survival.

Results： 78 cases of Submental island flaps was used in reconstructing defects of tongue,bucca,soft palate,mouth floor and oralpharynx.After reconstruction,the appearance and function of defects is good,and its supply area has obtained satisfactory appearance by repairing with adjacent flap. Of 78 cases of submental island flap all survived,except 2 cases with diabetes was necrosis in the edge,among them,1 case was got microsurgical vasovasostomy because of venous embolism、

Conclusion： The submental island flap provides a more effective and practical way for the oral and maxillofacial soft tissue defect reconstruction in carefully selected cases.

Key words： Submental island flap；Soft tissue defects；Appearance

70

Surgical Management of Arteriovenous Malformation in Head and Neck

Wang Yan-an,Zhang Zhiyuan,Fan Xindong, Ye Weimin, Zhu Hanguang Department of Oral and Maxillofacial Surgery, College of Stomatology, Ninth People's Hospital, Shanghai JiaoTong University School of Medicine; Shanghai 200011, China

Purpose: Arteriovenous malformation (AVM) present a significant clinical challenge to the head and neck surgeons which is often difficult to treat and can leave large, complex defects, and often requires a multidisciplinary team approach. The purpose of this article is to present our experience in surgical management of AVM in head and neck, and to evaluate free tissue transfer (FTT) as a safe and effective reconstructive technique to treat tissue defect after AVM resection.

Methods: Retrospective, single-institution case series.

Results: We describe3 patients with extensive lesions in various parts of the head and neck which underwent radical resection following preoperative embolization, and reconstructed with free flaps. There is no recurrence during a mean follow-up period of 5 years.

Conclusion: AVMs are uncommon and challenging lesions. Complete surgical excision following preoperative embolisation is an effective treatment method and immediate reconstruction is an integral part of definitive surgery for AVM. Use of FTT can ameliorate the large defects resulting from excision of these lesions.

Key Words: Arteriovenous malformation; Embolization; Surgery; Reconstruction; Free tissue transfer

71

Illiac Crest Flap Used for Mandibular Reconstruction of Familial Gigantiformcementoma

Wang Yang, Xu Liqun, Zhang Chenping

Department of Oral and Maxillofacial Surgery, College of Stomatology, Ninth People's Hospital, Shanghai Jiao Tong University School of Medicine, Shanghai 200011, PR China

Abstract： Familial gigantiformcementoma (FGC), which is generally considered benign and limited to the facial bones, is a rare familial form of the cementomas. Here we show a patient of FGC presented mandibular swelling from the right first molar to the left second molar. The preoperative laboratory investigations showed bone mineral in mandible was reduced, and he suffered fractures of tibia and femur 3 times without traumatic impacts. In case of serious complications of lower limb,

vascularized iliac crest flap was used for mandibular reconstruction instead of fibula flap. Segmental mandibular ctomy from anterior to the right first molar to anterior to the left second molar was performed with a computer simulation by Surge case 5.0 software. The defect was reconstructed with a bone graft of 11cm which was shaped to 4 segments. Outer wedge osteotomy was performed to extend the length of the bone graft. Thus, we performed a difficult case of mandibular reconstruction with illiac crest flap which was preferred used when defects are ≤9 cm.

Key words: Familial gigantiformcementoma; Mandibular reconstruction; Illiac crest flap

72

Orientation Techniques in Mandibular Reconstruction

Xu Liqun,Zhang Chenping ,Sun Jian

Dept. of Oral Maxillofacial-Head & Neck Oncology, Shanghai Ninth People's Hospital, School of Stomatology, Shanghai Jiaotong University, 200011, Shanghai, China

Abstract: Orientation of reconstructed mandible includes that of stump mandible and bone graft, which plays an important role in the functional and cosmetic lower jaw reconstruction respectively. A total of six types of orientation techniques for the stump of mandibles wafer based inter-maxillary fixation (IMF), inter-maxillary rigid fixation (IRF), pre-bending reconstruction plate (PRP), external fixation device (EFD), CAD/CAM re-position guidance (RPG) and navigation and robotic surgery (NRS) were introduced, simultaneously PRP, pin guidance EFD, RPG and NRS techniques also employed for bone graft. So far, NRS technique was mainly used for accurate calibration of some orientation techniques, like RPG. Several issues affected the orientation of reconstructed mandible as reconstruction pattern (one-stage or two-stage), defect type (HCL classification), occlusion factor and soft tissue consideration. In secondary mandibular reconstruction, the orientation of lower jaw was a refractory issue. Building up a stable and good occlusion relationship and respecting the acquired condylar position of unaffected side were really important for functional consideration and long term stability of reconstructed jaw. So sometimes orthognathic surgery should be done with the jaw reconstruction simultaneously, like BSSO or subapical osteotomy etc. Basically orientation of bone graft should obey the principle of mid-line accordance, reasonable width, height and projection of lower face. In this report, literature review combined with clinical cases presentation and experience sharing of varied orientation techniques would be performed.

Keywords: Mandibular reconstruction; Orientation technique; Stump mandible; Bone graft

73

Versatility of The Composite Lateral Arm-PCNA/PCNF Free Flap in Head and Neck Reconstruction

Yang Wenjun, Ruan Min, Zhou Shanghui, Liu Shengwen, Zhu Yun, Zhang Chenping

Department of Oral and Maxillofacial-Head and Neck Oncology, Ninth People's Hospital, Shanghai JiaoTong University School of Medicine, Shanghai Key Laboratory of Stomatology, Shanghai, China

Purpose: The aim of this study was to introduce the reconstructive potential of the composite lateral arm-PCNA/PCNF free flap in head and neck reconstruction.

Methods: The free lateral arm flap (LAFF) is a fasciocutaneous flap, it also may be harvested as a composite flap, with the posterior cutaneous nerve of the arm (PCNA) and posterior cutaneous nerve of the forearm (PCNF). These two nerves provide the potential for sensory flap, or vascularized nerve graft. We present 23 patients, 11 women and 12 men, mean age 40.1, which operated on between June,

2007 and May, 2012 in whom lateral arm flaps with PCNA/PCNF were utilized. 13 cases were employed as sensory flaps, among them 12 for reconstruction of defects of hemiglossectomy, 3 for bucca & lower lip, 7 cases as nerve cable graft for reconstruction of facial nerve as well as facial contour in complex parotidectomy defects. Literatures were reviewed and utility of LAFF was discussed.

Results: As a composite flap, LAFF can offer expendable quality skin for facial &oral mucosal defects, with PCNA for sensory flap, PCNF for vascularized nerve cable graft, or even with a segment of bone .It's possible for 2-team operation, easier to harvest. Furthermore, it's no need to sacrifice main vessels, no need for skin graft, scar formation & morbidity are minimal. Functional recovery of can be observed in PCNA cases as sensory flap and PCNF case as nerve cable graft for reconstruction of facial nerve.

Conclusions: For its more advantages, LAFF may be used in various anatomic defects within most soft tissue head and neck microsurgical reconstructions in current stage. It's successful as a single donor site for reconstructing facial contour and the facial nerve after major ablative defects in the parotid region. The possibility of sensory recovery through neural anastomoses and low donor site morbidity enhances its efficiency.

74

Clinical Present of Vascular Crisis Salvaged Operations of Free Flap Reconstruction of Head Neck Region in 56 Cases

Yang Xi, Xu Liqun, Ji Tong, Zhang Chenping

Department of Oral & Maxillofacial – Head & Neck Oncology

Ninth People's Hospital Affiliated Shanghai Jiaotong University, School of Medicine, Shanghai, China

Purpose: Vascular crisis still represents the most common complication in free flap transfer in oral and maxillofacial and head neck reconstruction. The aim of this retrospective study was to represent medical information of patients with vascular crisis of free flap reconstruction.

Methods: We examined the data of 56 patient cases of vascular crisis in the patients undergoing free flap reconstruction with a microsurgical flap in our department between 2007 and 2012. We represent medical data such as results of exploration, type of vascular crisis, initial symptom, response date of vascular crisis after operation.

Results: 56 patients had undergone 58 vascular crisis salvaged flap operations. In which, 28 flaps were successful, 26 flaps turned out to be failure and 4 flaps were partial necrosis (skin paddle necrosis and flap partial necrosis). 16 flaps were arterial crisis, 36 flaps venous crisis, 4 cases no clear reason and 2 cases were partial reason. Color change was most common of initial symptom of vascular crisis. The exploration during three days after operation had better successful rates.

Conclusions: Vascular crisis salvaged operation was a convenient and reliable method in oral & maxillofacial-head neck reconstruction as soon as possible, which need serious nurse and clinical experience.

75

Tongue Reconstruction with Tongue Base Island Advancement Flap

Ye Weimin, Hu Jingzhou,Zhu Hanguang, Zhang Zhiyuan

Department of Oral and Maxillofacial-Head and Neck Oncology, the Ninth Affiliated Hospital, Shanghai Jiao Tong University, Shanghai, China

Econstruction of medium-sized defect of tongue remains a challenge if aesthetic impairment is to be avoided. In this study, nineteen tongue base island advancement flaps were developed to reconstruct medium-sized defects after the tongue squamous cell carcinoma ablations: 13 cases were T1N0M0, 6 cases were T2N0~1M0. The largest size amounts to 5.4×4.8 cm (length × width), with a mean of 4.6×4.4 cm. The tongue base island advancement flap reduces the volume of tongue base without causing function impairment of tongue. All patients recovered with good objective and subjective speech and swallowing and aesthetics. No patient developed local recurrence or lymphatic metastasis. The technique of tongue base advancement flap is ideal for functional and aesthetic repair of medium-sized tongue defects after cancer ablation.

76

Comparison of Functional Outcomes in Surgically and Prosthetically Rehabilitated Maxillectomy Patients.

Manju V

Dept of Prosthodontics & Implantology Amrita School Of Dentistry Consultant Maxillofacial Prosthetist Head & Neck Institute Amrita Institute of Medical Sciences

Purpose: Surgical resection of maxillofacial tumours usually results in oro-nasal and oro-antral communication. This in turn causes severe functional problems and affects the appearance and the psychosocial functioning of the patient. Rehabilitation of the defect can be done by either conventional obturator prosthesis or surgically reconstructed with a local pedicle flap, or free vascularized flap. The main purpose of rehabilitation is to restore the functions of swallowing, speech and mastication; which determines the quality of life of a patient.

Aim of the study: To compare the masticatory performance and swallowing function of post-maxillectomy patients who are rehabilitated with obturator prosthesis and surgically reconstructed by free vascularized flap combined with prosthesis.

Materials and methods: A comparative cross sectional study was used to compare the functional outcome in post-maxillectomy patients rehabilitated with obturator or free flap combined with prosthesis. The measurements are done for both the study group and the control group using the following criteria:1.Mastication: Chewing ability is measured as the masticatory performance, which is defined as the particle size distribution when chewed for a given number of strokes2. Swallowing: Assessed by video fluoroscopic examination.

Results: The data analysis was done using the IBM SPSS software (version-20) to find the statistical significance of function. Swallowing outcomes of two groups were not statistically significant for both high density barium swallow ($p>0.05$) and low density barium swallow ($p>0.05$). Patients with free flap combined with prosthesis group had better masticatory performance when compared with obturator group.

Conclusion: Within the limitations of the study, the masticatory function in patients rehabilitated with flap and prosthesis were better than the obturator group. With respect to the swallowing function, both groups showed comparable outcomes.

77

Clinical Evaluation of The Effects of Different Retention Systems in Patients with Half-maxillary Defects

Ma Xiao

School and hospital of stomatology Wuhan university

Purpose: The aim of this study was to evaluate the clinical effects of obturators with different retention systems (clasp, ERA, ball, bar)in patients with half-maxillary defects, including retention, stability and durability.

Methods: 20 patients were included and divided into four groups corresponding to four systems (each n=5). In each patient, abutment teeth adjacent to defects were splinted with crowns. Retention and stability were evaluated by modified Kapur scale, and the durability of abutment teeth and attachments were detected by clinical examination one year later after delivery.

Results: After delivery, retention scores of four groups were not significantly different. Stability of clasp group and ERA group were significantly better than the other two groups. One year after delivery, retention of clasp group decreased rapidly and were significantly different with that of ERA group.

Conclusion: Due to the resilient characteristic, the ERA attachment is a reliable choice to restore half-maxillary defects.

Key words: ERA; Half-maxillary defects; Retention; Stability; Durability

78

Analysis of Cortical Bone on The Mandibular Body in Psychological Stressed Rats by Micro-CT

Li Qiang, Zhang Min, Liu Jiu, Chen Yongjin

Department of General Dentistry and Emergency, School of Stomatology, The Fourth Military Medical University

Purpose: To evaluate the influence of psychological stress on the bone mineral density (BMD) of mandibular cortical bone in rats.

Methods: The adult male SD rats were randomly divided into psychological stress (PS) group, control (C) group and foot shock (FS) group. The PS animals were placed internally in the communication box to receive the psychological stimuli which came from their neighboring FS group rats. After observing the behavioral changes of the PS group rats and C group rats at week 1, 2, 3, 4 and 5with elevated plus maze test, the BMD of five regions of interest (ROIs), i.e. A, B, C, D and E, in the buccal side or lingual side of mandible were calculated by Micro-CT.

Results: Remarkable decrease of time spent in the open arms, ratio of open arms time and ratio of open arms entries were observed in PS group compared with C group at each time point ($p<0.05$), while no significances were observed among PS groups ($p>0.05$). On the buccal side of mandibular body, BMD in site D of week 5 PS group was higher than that of matched C group and week 1 PS group ($p<0.05$). Similar results of BMD were obtained in site E between week 5 PS group and C group as well as week 1 and week 2 PS group ($p<0.05$). On the lingual side of mandibular body, the obvious alterations of BMD were observed in sites B and C between week 5 PS group and matched C group and week 1 PS group ($p<0.05$). No statistically alterations of BMD were observed in the other sites between PS group and C group at each time point ($p>0.05$).

Conclusion: Psychological stress induced by communication box could result in the anxious behavior of SD rats as well as increase the BMD of cortical bone in certain regions of the mandibular body to some extent.

Key words: Psychological stress；Mandible；Micro-CT；Bone mineral density

79

Prosthesis-guided Implant Restoration of Auricular Defect Using Computerized Tomography and 3-Dimensional Photographic Imaging Technologies: A Clinical Report

Wang Shuming, Leng Xu,Zhang Yaqi,Zhang Dapeng,Wu Guofeng

Department of Prosthodontics, School of Stomatology, the Fourth Military Medical University

Purpose: The concept of "prosthesis-guided implantation" has been widely accepted for intraoral implant placement, while it is not fully appreciated by clinicians for facial defect restoration. In this clinical report, we utilized multiple digital technologies to achieve facial defect restoration by prosthesis-guided implantation.

Methods: A simulation surgery was performed to remove the residual auricular tissue, and ensured the correct position of the mirrored contralateral ear model. The combined application of computed tomography and 3-dimensional photography reserved the position of the mirrored model, which was evolved into the definitive implant-retained auricular prosthesis.

Surgical reconstruction of congenital microtia remained a challenge to surgeons because of the complex shape and size of the human ear. An auricular prosthesis is a good alternative to surgical reconstruction. Since Tjellström1 firstly reported the application of craniofacial implants-retained prostheses for auricular defects, many clinical literatures have proved its benefits, e.g., excellent support and retentive abilities, improvement of patients' appearance and life quality.2-6Tjellström

Results: To enhance the implantation outcomes, computerized tomography (CT) has been used to determine the ideal implant placement according to the cranial bone quality and esthetic perspective.7This pre-surgical planning usually results in a resin guide template for the surgeon to insert implants in proper positions.8-10 However, in some microtia cases, the residual ear tissue is unfavorable for the auricular prosthesis esthetics and needs to be removed during the implantation surgery. This operation will inevitably affect the fitness of the implant resin template in patient without prior estimation during the surgical planning. Thus, a simulation of the resection process should be included in the design of the guide template. Previous reports have not discussed this simulation operation for residual auricular tissues. In past decade, CT scan11,12 and 3-Dimensional (3D)13 photographic imaging have been reported to mirror the contralateral and unaffected ear and offer significant benefits in the design of the auricular prosthesis. Nevertheless, both of these techniques have disadvantages if they are used individually. CT needs to expose the patient to radiation, while 3D photographic imaging may lose some auricular data of undercut areas if certain areas cannot be directly recorded by the lenses13. None of previous studies have combined the use of CT scan and 3-D photography systems in the same case although they may be mutually complementary.

Conclusion: In this study, the patient underwent two scans in sequence: one CT scan at the beginning for the position planning of the implant surgery and then a 3D imaging scan for the design of the definitive auricular prosthesis. The two scanning data were merged perfectly, which guaranteed the definitive auricular prosthesis in its original position of the implant planning. Moreover, advances in Rapid Prototyping (RP) has been evolved to the development of new fabrication techniques of maxillofacial prostheses12-14. Achievement of further automation RP technology, e.g., Selective Laser Sintering (SLS), led to the automatic generation of solid patterns, either wax powder or polystyrene powder. In this study, SLS machine was used to fabricate the wax pattern of the auricular prosthesis and the resin cast of the patient's face, which was proved to be favorable for the subsequent maxillofacial laboratory process.

Key words: Temperature molding wax；Impression for the soft palate；Clinical assessment

80

Obturator Restoration of An Extensive Palatal Defect with The Assistance of Intermaxillary Traction: A Clinical Report

Zhang Dapeng, Wu Guofeng*, Ding Yin

Department of Prosthodontics, School of Stomatology, the Fourth Military Medical University

Purpose: Palatal defects secondary to the treatment of tumor, trauma, and congenital factors are commonly seen in Prosthodontic clinics accounting for 1-1.5% of outpatients in China. The defects not only result in significant dysfunction of speech, mastication and deglutition to the patients, but also cause severe disfigurement, thereby impairing the level of self-esteem of these patients. Therefore, the treatment goal of restoring acquired palatal defects is to obtain normal function and appearance. The goal of this report is to present the restoration of a significant defect of the right maxilla acquired from previous hemimaxillectomy using obturator denture following intermaxillary traction in a 65-year-old woman.

Method: Treatment began with intermaxillary traction to rectify the palatal inclination of the remaining teeth, and to obtain a favorable occlusal relationship. The remaining teeth were then splinted by metal ceramic connected crowns. A partial denture obturator was then employed to restore the defect and the patient was able to achieve a stable and satisfactory occlusion and facial profile.

Results: During the recall appointments (2 week, 6 weeks, and 3 months), the prosthesis demonstrated continued serviceability, and the patient was pleased with both function and esthetics. Mastication and pronunciation capabilities were greatly improved and follow-up training by a Speech Pathologist maximized the potential of the obturator prosthesis. The facial support and profile was also improved.

Conclusion: This clinical report describes a multidisciplinary approach to restoring an acquired palatal defect complicated by the palatal inclination of the residual maxilla. The rectification of the misdirection of the remaining alveolar bone and teeth using intermaxillary traction was essential to optimize support, stability and function of the obturator prosthesis. The obturator prosthesis eliminated the confluence of the nasal and oral cavities and thus, the ability of pronunciation, mastication, and deglutition was improved to the greatest extent.

Key words: Palatal defect; Intermaxillary traction;Obturator

81

Mechanical Properties and Color Stability of Nano-oxides Pigmented Maxillofacial Elastomer

Han Ying, Zhao Yimin

Department of Prosthodontics, School of Stomatology, the Fourth Military Medical University

Purpose: The objective of this study was to evaluate the effect of 2 nano-oxides (commercial UV-light protection) combined with silicone pigments on the mechanical properties and color stability of a silicone elastomer before and after artificial aging.

Method: Two types of nano-oxides [Nano Zinc oxide (ZnO) and Nano Titanium oxide (TiO_2)] were combined at 1%, 2%, 3% concentrations with A-2000 silicone elastomer. Silicone intrinsic pigments were added (control = no pigments). All specimens were tested.

Both mechanilcal properties and color measurement were recorded before and after aging in an artificial aging chamber at 450 kJ/m2. CIE L* a* b* values were measured by spectrophotometer.

Hardness (ASTM D2240), tensile strength (ASTM D412), tear strength (ASTM D624) and elongation were measured using a universal testing machine. For each property, 3-way ANOVA and Fisher's PLSD test were performed to determine if there were statistically significant differences ($p<0.05$).

Results: After artificial aging, the changes of tensile strength, elongation, tear strength and hardness were showed in the Figures. There was no significant difference between no pigments groups and mixed pigments groups ($P>0.05$) when mixed with nano-oxides;

For color stability, ΔE^* values of the mixed groups of all concentration of nano-oxides were significantly below the 50:50% acceptability threshold when compare to control groups. Overall, TiO2 provided better protection to this silicone than ZnO after artificial aging.

Conclusion: Nano-oxides improve color stability and mechanical properties of A-2000 silicone elastomer after subjected to artificial aging.

Key words: Mechanical Properties; Nano-oxides; Color Stability; Maxillofacial Prosthetic Elastomers

82

Effects of Speech after Partial Glossectomy with Reconstruction Using Radial Forearm Free Flap

Na Sijia, Wang Weiqi, Jin Wei

Department of Oral and Maxillofacial Surgery, School of Stomatology, the Fourth Military Medical University

Objective: The purpose of this study was to investigate the effects of glossal soundsafter partial glossectomy with reconstruction using radial forearm free flap (RFFF).

Methods: The methods of evaluation consisted of scores for intelligibility of 399Chinese syllables and 3 groups of glossal sounds. The glossal sounds, based on palato-lingual contact (lingogram), were useful to evaluate function of the respective parts of the tongue.

Result: One patient who had had a partial glossectomy and resection of the floor of the mouth achieved an overall score of 80.5% one year postsurgery, and his glossal sounds were also excellent. Three patients who underwent removal of the floor of the mouth and hemiglossectomy, excluding the root of the tongue, had overall scores ranging from 41.3% to 85.6%. Two of these had particularly low scores for the glossal sounds produced with the rear part of the tongue, and this suggested the necessity for suspension slings to prevent depression of the reconstructed tongue and the floor of the mouth. The hemiglossectomy with partial mandibulectomy had an acceptable score of 67.4%. Other patients without reconstruction using RFFF had lower scores for the limit of tongue moving.

Conclusions: The glossal sounds produced with the rear part and the blade of the tongue often tended to improve postsurgery.This study also shows the speech of patients undergoing partial glossectomy reconstructed with RFFFimprove significantly.

Keywords: Free radial forearm flap; Glossal sounds; Glossectomy.

Session V – Chemo-radiation – Morbidities and strategies to minimize them

1

The Effect of X- rays on Rabbits' Infraorbital Nerve.

Chiang Tingyen，Ren Weihong

Capital Medical University

Purpose: This study aims to observe the effect of X- rays on infraorbital nerve of rabbits.

Methods: New Zealand rabbits were randomly divided into four groups, among which there were a control group without X-ray irradiation operation and three irradiation groups exposure to 10, 20, and 30 Gy X-ray irradiation, respectively (n = 6 in each group). All the rabbits were sacrificed three months following X-ray irradiation operation and the infraorbital nerve of rabbits were extracted. The ultrastructure changes of rabbits' infraorbital nerve were investigated by using electron microscope.

Results: In control group, nerve fiber structure is clear, and myelin sheath is concentric layered arrangement, and the axon is clear visible transverse microtubule and neurofilament. The cytoplasm, extracellular matrix and cell organelle structure of Schwann's cell is clear.10 Gy group had no obvious difference compared with the control group. In 20 Gy group, partial myelin appear vacuolar degeneration, and some myelin appeared delaminateIn 30 Gy group, vacuolation in myelin, unclear lamellar structure, degenerated axons, and serious morphological change of myelin were observed.

Conclusion: X-ray is detrimental to the infraorbital nerve of rabbits, resulting in the injury of myelin and axon, and the change is positively related with the does.

Key words: Infraorbital nerve; Radiation injury

2

Reconstruction of The Cranio-maxiilofacial Soft Tissue Defection with Vascularized Free Rectus Abdominismusculocutaneous Flap and Scalp Expansion: a case report

Lin Chongxiang, Tu Chengwei, Shao Xia, Zheng Shunyou

Department of Oral and Maxillofacial Surgery, the First Affiliated Hospital of Wenzhou Medical University

Purpose: Presented is a case of a 45-year-old male patient with defection of cranio-maxillofacial soft tissue caused by a serious traffic accident.

Methods: After debridement of the necrotized soft tissue, we used a vascularized free rectus abdominismusculocutaneous flap to reconstruct the maxillofacial soft tissue defection.

Results: And two soft tissue expanders were implanted under the scalp 12 days later, while the transplanted rectus abdominismusculocutaneous flap survived. Cicatricial massive scalp defects were repaired by the expanded flaps in secondary operation five months later.

Conclusion: Our experience indicates that reconstruction of cranio-maxiilofacial soft tissue defection with rectus abdominismusculocutaneousflaps and scalp expansion is a suitable, cosmetically acceptable method.

3

Evaluation of Oral Health Before and After Radiotherapy in Patients

Undergoing a Protocol of Dental Hygiene.

Bellia E; Menardi P; Furnari A; Carossa S; Gassino G.

Department of Surgical Science, CIR Dental School, Prosthodontic Section, Turin, Italy

Purpose: Aim of the study is to evaluate the role of professional and domestic oral hygiene sittings in preventing collateral effects of radiotherapy.

Methods: The sample includes 26 patients affected by head and neck carcinoma, recruited before proceeding with radiotherapy; Patients are given two questionnaires, to evaluate their knowledge about oral hygiene manoeuvres and radiotherapy collateral effects.

Before and after radiotherapy patients undergo: periodontal evaluation by means of the plaque index and PSR. basal and induced saliva flux evaluations.

Results: In 80% of the cases plaque index drops to less than the threshold value of 40% .PSR values remain unvaried to level 2, only one case improves to level 1.In 90% of the cases saliva is found to be much thicker after radiotherapy. Before radiotherapy, saliva flux is more or equal to 4ml, while after radiotherapy values decrease to 3.5 ml. In most cases ph tends to become more acid after radiotherapy, while buffer capacity doesn't show a definite trend before and after radiotherapy.

Conclusion: In the light of these preliminary data we can infer that dental hygiene plays a significant role in monitoring and preventing radiotherapy collateral effects, thus maintaining acceptable oral health conditions throughout the whole treatment period.

Key words: Dental hygiene; Radiotherapy.

4

Assessment of Shoulder and Neck Dysfunction and Functional Status Post Radiotherapy/Chemotherapy in Head and Neck Cancer Patients: A Pilot Study

Paramjot, Sandeep, Aashima

Method: The Purpose of this descriptive study was to explore the disabilities of neck and shoulder and to check for the functional status for 20 outpatients (who met inclusion and exclusion criteria) after a course of radiotherapy (RT) /chemo-radiotherapy (CXRT) for cancers of Head and Neck. Sampling method used was convenience sampling. Time period of the study was March 2014-April 2014. Data was collected in follow up cases from 1 month to 30 months from Christian Medical College and Hospital , Ludhiana, Punjab post RT/CXRT patients using GUSS (Gugging Swallowing Screen), NDI (Neck Disability Index), DASH (Disabilities of Arm, Shoulder and Hand),Lung expansion and Cervical ROM

Results: The mean age of the study was 58.7 years (59) and the number of male patients (85%) were more than female patients (15%). Significant result was found when compared between DASH and NDI (0.522) and GUSS and NDI. In NDI 75% patients were found to have disability (mild to severe) and in GUSS 100% were found to have dysphagia (slight to severe) and in case of DASH 80% were found to have slight to severe disability. Flexion and rotations of the neck were also significant with NDI. In this study the patients having decreased chest expansion were 85% and 15% were found to have normal chest expansion.

Conclusion: The study was tested and accepted the hypothesis that there is a significant difference in Neck disability and swallowing performance of the subjects. The participants had greater risk of aspiration and aspiration related effects. Hence, Selected Interventions such as Swallowing exercises like Shaker exercise and Hyoid lift manoeuvre and positioning during swallowing can be recommended for the patients. For the neck and shoulder disability various neck and shoulder exercises can be taught to the patient as per to increase the ability of the patient and increase the level of performance.

Key words: Head and Neck Cancer; Radiotherapy; Chemotherapy; NDI; DASH; GUSS; Lung

expansion; Goniometry

5

PH-Responsive Micelles Constructed by PCL-PEG-PCL Triblock copolymer Via Oxime Linkage for Anticancer Drug Delivery

Li Xiao

Department of Oral and Maxillofacial Surgery, The First Affiliated Hospital of Harbin Medical University

Purpose: To obtain a pH-responsive Doxorubicin drug delivery system.

Methods: A novel and well-defined pH-triggered backbone-cleavable triblock copolymer was successfully synthesized by hydroxyethyl terminal with oxime linked poly (ethylene glycol) (OAPEG-OH) ligating with polycaprolactone (PCL). And the triblock copolymer was characterized using fourier transformed infrared spectroscopy (FTIR), nuclear magnetic resonance (NMR), and gel permeation chromatography (GPC) analysis. Doxorubicin (DOX), a model anticancer drug, was encapsulated into PCL-PEG-PCL micelles.

Results: Benefiting from its amphiphilic structure, PCL-PEG-PCL copolymer can self-assemble into micelles in aqueous solution, which was demonstrated by transmission electron microscopy (TEM) and dynamic light scattering (DLS). The cytotoxicity of the PCL-PEG-PCL micelles was evaluated by MTT assay against NIH/3T3 normal cells. The drug release assay result showed that the DOX release from the micelles was significantly accelerated at mildly acidic pH of 5.0 compared to physiological pH of 7.4, demonstrating the pH-responsive feature of the drug carrier with oxime linkages. Besides, the anticancer activity of DOX-loaded micelles was evaluated by MTT assay against HeLa cells.

Conclusion: Results demonstrate that micelles self-assembled from PCL-PEG-PCL triblockcopolymers are promising vehicles for acid-triggered delivery of hydrophobic drugs.

Key words: pH-responsive; Micelles; Oxime linkages; Drug delivery system

6

Sequential Release Chemotherapeutic Drug with Polymeric Delivery System for Oral Squamous Cell Carcinoma Therapy

Liu Bing

Department of Oral and Maxillofacial Surgery, The First Affiliated Hospital of Harbin Medical University

Purpose: We developed a ROS-responsive effective drug delivery system to overcoming multidrug resistance (MDR) of oral squamous cell carcinoma (OSCC).

Methods: The ROS-responsive crosslinked polymeric micelles (Cinnamaldehyde- Loaded HPG-7-ethyl-10-hydroxyl-camptothecin, CA-LoadedHPG-SN38) were successfully prepared by the self-assembly of amphiphilic HPG-SN38 and CA. And amphiphilic HPG-SN38 that conjugate via a thioether chain copolymer was characterized using fourier transformed infrared spectroscopy (FTIR), nuclear magnetic resonance (NMR), and gel permeation chromatography (GPC) analysis. CA-Loaded HPG-SN38 Micelles was characterized using transmission electron microscopy (TEM) dynamic light scattering (DLS), critical micell concentration (CC) and Ultra Violet(UV).

Results: The drug release assay result showed that the SN38 release from the micelles was

significantly accelerated at the high level of ROS concentration. The anticancer activity of CA-loaded HPG-SN38 micelles was evaluated by MTT assay against HN-4,MCF-7 and A549 cells. The IC50 of CA-loadedHPG-SN38 was significantly reduced. The flow cytometry and confocal laser scanning microscopy (CLSM) measurements confirmed that the CA-loadedHPG-SN38 could be internalized by HN-4 and MCF-7 cells efficiently and release CA and sn38 inside the tumor cells to enhance the inhibition of cell proliferation

Conclusion: In conclusion, the prodrug CA-loadedHPG-SN38 formed nanocapsules responsive to tumor ROS heterogeneity, releasing the parent drug SN38 via enhanced hydrolysis due to ROS-oxidation of the linker, giving rise to high in vitro cytotoxicity therapeutic activity. The nanocapsules had sizes good for tumor targeting via the EPR effect. Excellent CA-loadedHPG-SN38 provide a favorable platform to construct smart drug delivery systems (DDS) for cancer therapy.

Key words: ROS-responsive; Micelles; Drug delivery system

7

A study of postoperative radiotherapy effects on vascularized nerve graft for facial nerve repair in a rabbit model

Zhu Yun, Liu Shengwen, Zhou Shanghui,Yu Zhiwei, Hu Haisheng, Sun Jian, Zhang Chenping, Yang Wenjun.

Department of Oro-maxillofacial Head and Neck oncology, Ninth People's Hospital, College of Stomatology, Shanghai Jiaotong University School of Medicine, Shanghai Key Laboratory of Stomatology. Shanghai 200011, China

PURPOSE: This study intends toto study the impact of radiotherapy on vascularized and non-vascularized facial nerve repair.

Methods: 12 New Zealand white rabbits were used in this study, upper buccal branch of facial nerve of both side would be cut off, forming a 2 cm defect, one side took the great aricularnerve and associated vascular pedicle to repair facial nerve defect, the other side took the central aricularnerve directly to repair facial nerve defect. Divided into 2 groups 1 month after operation, RT group and control group, radiotherapy planned to bilateral nerve transplantation site. Dose was equivalent to 60 Gy of each side. Results were evaluated with analysis of upper lip performance, electrophysiologic monitoring, histological studies, toluidine blue staining and electron microcopeelectron scanning 3 months after operation.

Results: All the rabbits appeared lip asymmetry after operation, At 4-month following facial nerve repair, facial nerve function recovery was observed .In RT group, pathological changes were viewed as surrounding tissue fibrosis, nerve cell shrinkage, schwann cells hurt and demyelinating. Comparing with control group, postoperative radiotherapy had no obvious effect on facial nerve regeneration and facial function recovery, 3 months after radiotherapy, the upper lip recovery rate of RT group was slower than control group. In RT group, comparing VNG with FNG, nerve function recovery rate of VNG was significantly faster than FNG. The difference of the nerve conduction velocity and potential volatility was statistically significant.

Conclusions: The postoperative radiotherapy had no obvious effect on the function of facial nerve graft. In RT group, the result of nerve regeneration and functional recovery of VNG was better than FNG. VNG could reduce adverse impacts of radiotherapy on the facial nerve regeneration and facial function recovery.

Key words: Facial nerve; Vascularized nerve graft; Animal model; Peripheral nerve regeneration; Postoperative radiation

8

Implants in Irradiated Tissues.

Division of Advanced Prosthodontics, School of Dentistry, UCLA

Shahi P, Sung E, Beumer J

Irradiation of head and neck tumors predispose to changes in bone, skin, and mucosa, which affect the predictability of osseointegrated implants. Initial success requires initial implant anchorage and immobilization, the formation of a clot between the surface of the implant and the osteotomy site, release of growth factors, angiogenesis and migration of mesenchymal stem cells to and deposition of bone on the surface of the implant. However these biologic processes may be compromised or absent in patients exposed to high dose radiation, and as a result, anchorage of implants in bone is probably mechanical as opposed to biological. The purpose of this presentation is to review the literature in this field and describe the current view of when and whether it is appropriate to use implants in these patients.

9

Clinical Analysis of Two Removable Prosthetic Material to Repair the Unilateral Maxillary Defect.

Wei Zening, Li Yanan, Li Chuanjie

Department of Stomatology, Chinese PLA General Hospital.

Purpose: To explore the clinical efficacy of unilateral maxilla resection repaired by two kinds of removable prosthetic materials .

Methods: 5 patients whose unilateral maxilla was removed because of tumor, with mouth nasal cavity and orbital floor reserved were selected. Removable obturators (made of plasticized poly and silicone rubber) were applied to repair their maxillary defects. The biocompatibility of material, patients' satisfaction, comfort, voice clarity , masticatory function and surface cleanliness were assessed 1 month, 3months and 6 months after restoration.

Results: Both of these two kinds of materials can restore the facial aesthetics and oral physical function in some degree, and significantly improved the patient's voice clarity and efficiency of eating. Silicone rubber has better biocompatibility, bio-security, patient comfort and simulated effect. While the surface cleanliness and the aging time of plasticized poly (methyl methacrylate) plastic is superior to silicone rubber .There was no significant difference between the patient voice clarity and chewing efficiency.

Conclusion: Two type of removable prosthetic materials have their own advantages and disadvantages in the restoration of unilateral maxillary defects, doctor should choose it in accordance with the clinical treatment plan and the preference of the patients.

Key words: Removable prosthetic materials; Maxillary defect; Silicone rubber; Plasticized poly

10

Dosimetric distribution to tooth-bearing regions and osteoradionecrosis following intensity-modulated radiation therapy for oropharyngeal cancer

YL Seetoh, RS Lee, H Hansen, N Lee, E Riedel, J Huryn, CL Estilo

National Dental Centre Singapore

Purpose: The aims of this paper were (1) to determine the dosimetric distribution to tooth-bearing areas of the maxilla and mandible among patients receiving IMRT for BOT cancer or tonsillar cancer; (2) to report the prevalence of ORN in the study cohort; and (3) to investigate the relationship between dose and the confirmed areas of ORN.

Methods: 255 consecutive patients with oropharyngeal carcinoma who were treated with IMRT at Memorial Sloan Kettering Cancer Centre (MSKCC). The diagnosis was tonsillar cancer in 125 and BOT cancer in 130. All patients were treated with IMRT using a dose painting technique. All patients were prescribed with a mean dose of 70 Gy to the gross tumor volume. The tooth-bearing regions of the maxilla and mandible were divided into 5 regions: ipsilateral molar (IM), contralateral molar (CM), ipsilateral premolar (IPM), contralateral premolar (CPM) and anterior (ANT), giving a total of 10 distinct regions. The individual segments were manually contoured by two investigators using MSKCC proprietary contouring software. The dose delivered to each segment was then calculated and dose-volume histograms were generated for the maxilla and the mandible. A chart review of the 255 patients was conducted to identify those who developed ORN. The areas of confirmed ORN were then contoured and the mean and maximum doses to these areas calculated.

Results: In patients with BOT cancer, the ipsilateral side received significantly higher doses than the contralateral counterpart ($p < 0.0001$). Overall, T stage was significantly associated with higher dose in all contoured regions for both maxilla ($p<0.0001$) and mandible ($p < 0.002$). Furthermore, in patients with more advanced (T3 and T4) tumors, the entire mandible received maximum doses above 50 Gy. Among patients with tonsillar cancer, as with the BOT patients, higher doses were delivered to the molar than to the premolar and anterior regions in both maxilla and mandible. Unlike the BOT subset, in the tonsillar cancer subset the dose to the maxilla was similar to mandible in both mean and maximum doses (Table 3B). The doses were significantly higher on the ipsilateral side than on the contralateral side for both jaws ($p < 0.0001$) (Table 3). T stage was also significantly associated with higher mean and maximum doses delivered to the maxilla ($p< 0.0001$) (Figure 5A; Table 3). The ipsilateral molar of the maxilla and mandible received the highest maximum doses, and these doses were only marginally associated with T stage ($p=0.05$). ORN developed in 12 of the patients, 6 each in the BOT cancer and tonsillar cancer subsets (Table 5). This puts the incidence of ORN in the present cohort at 5.3% (12/255). All cases of ORN developed in the mandible: 8 in the posterior ipsilateral molar (IM) region, 1 on the contralateral molar (CM) region and 1 in the ipsilateral premolar (IPM) region. The ORN developed spontaneously in 10 patients and developed after post-radiotherapy dental extractions in 2 patients. The average maximum dose to the volumes with ORN was 74.8 Gy (range 70.5 -0.8 Gy) and the average mean dose was 64.4 Gy (range 57.5-76.0 Gy).

Conclusion: In our study, the anatomical locations of different types of cancer resulted in significantly different dose distributions in the jaws (Table 4) with several regions of the jaw typically received maximum doses in excess of 50 Gy. The results of this study show which tooth-bearing regions are at risk of receiving high doses for patients with base of tongue and tonsillar cancers. For BOT subset, these were the IM and CM for the maxilla and the whole mandible for especially for T3/ T4 tumors. For the tonsillar cancer subset, this was the IM and CM for the maxilla and the IM, CM and IPM for the mandible. This might be useful in planning for pre-radiation extractions when detailed simulation plans are unavailable.

Key words: IMRT; Intensity modulated radiotherapy; Dosemetric distribution; Osteoradionecrosis; Oropharyngeal cancer

11

Dental Implant Survival in Irradiated Maxilla: a Systematic Review of the Literature

Min Tian, Guofeng Wu, Chufan Ma, Haibo Wu, Jihua Chen

Department of Prosthodontics, School of Stomatology, Fourth Military Medical University, 145 West Changle Road, Xi'an, China

Objective: The aim of this study was to evaluate the implant survival in the maxilla after radiotherapy in oral cancer patients.

Methods: A comprehensive research on MEDLINE, PUBMED and EMBASE was conducted for articles published between January 1990 and July 2014 to identify literature presenting survival data on

the topic of dental implants in Maxilla patients who received radiotherapy for head and neck cancer. References of relevant studies were also searched. Screening, data extraction and quality assessment were conducted independently and in duplicate. Random effect model was used to calculate the survival rate of dental implant in irradiated Maxillary jaw and the 95% confidence interval.

Results: The survival rate of dental implant in irradiated Maxillary jaw was 75.2%(95% confidence interval:68.2%,81.1%); the survival rate of HBO therapy group was 81.8%(95% confidence interval:66.7%,91.0%), the survival rate of non-HBO therapy group was 73.5%(95% confidence interval:65.3%,80.4%); the survival rate of > 3 years follow-up group was 75.7%(95% confidence interval:68.0%,82.0%), the survival rate of < 3 years follow-up group was 76.3%(95% confidence interval:55.6%,89.2%).There were no significant differences between HBO therapy group and non-HBO therapy group (P >0.05), > 3 years follow-up group and < 3 years follow-up group (P >0.05).

Conclusions: It is a feasible way to use dental implant in irradiated Maxillary jaw. Only 5 studies on HBO therapy were included and the date indicated that HBO therapy did not significantly improve the implant survival rate. The survival rate didn't reduce significantly with the time.

Keywords: Radiation therapy; Survival rate; Implant; Maxil

国食药监械（准）字2013第3461200号

正海生物
ZH-BIO
WWW.ZHBIO.COM

海奥® HEAL-ALL 口腔修复膜

独特的双层结构　引导细胞长入和快速血管化　可完全降解

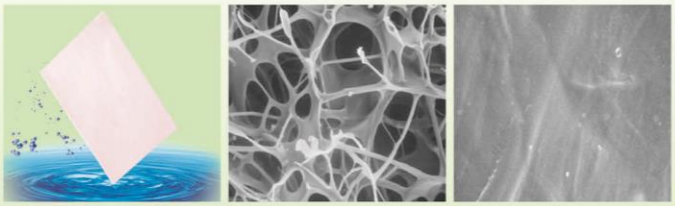

适用范围：
- 口腔内软组织浅层缺损的修复
- 腮腺手术中预防味觉出汗（Frey's）综合征
- 引导骨再生技术的应用

正海生物
ZH-BIO

烟台正海生物技术有限公司
地址：山东省烟台市经济技术开发区衡山路10号
电话：0535-6931906

上海敬仁贸易有限公司

上海敬仁贸易有限公司是一家由中国与瑞典合作建立的、专注于颅颌面器官缺损后赝复体修复治疗的专业公司。公司成立于2006年。

公司提供由于遗传、疾病、肿瘤、外伤、意外，整形失败等原因造成的颅面器官缺损的临床植入系统和颅颌面各种赝复修复体，具有独立的赝复体制作所。

产品由临床植入系统和赝复体制作二部分组成。

公司同时提供介绍国际一流、世界著名的颅颌面器官缺损赝复体修复治疗的境外医疗机构的服务。

我们的理念：专注、专业、完美。

我们的宗旨：共同努力，共同成长，共同收获。

我们的目标：让所有人都有自信。

上海敬仁贸易有限公司
地址：上海市平江路139号五航大厦9楼C座
电话：+86-21-54520499 64187052
传真：+86-21-64432618 邮编：200032
E-mail:webmaster@renjeshiye.cn

Nobel Biocare™